

# Oncoplastic Breast Surgery: Is it reliable in the treatment of multifocal breast cancer? A preliminary report of a prospective randomized controlled trial

AT Awad<sup>1</sup>, Mostafa Elsayed<sup>2</sup>, Ahmed Elsayed<sup>1</sup>, Tarek Elfayoumi<sup>1</sup>, MA Alhussini<sup>1</sup>

<sup>1</sup> Surgical Oncology Unit, Alexandria Faculty of Medicine, Alexandria, Egypt

<sup>2</sup> Department of Surgery, Alexandria Students' University Hospital, Alexandria, Egypt

## ORCID ID of the author(s)

AT: 0000-0001-8782-3787  
ME: 0000-0003-4386-6894  
AE: 0000-0002-2316-8864  
TE: 0000-0002-9506-9590  
MA: 0000-0002-3169-4338

## Corresponding Author

Mostafa Elsayed  
Department of surgery, Alexandria Students' University Hospital, Alexandria, Egypt  
E-mail: m\_elsayed2009@yahoo.com

## Ethics Committee Approval

Ethical committee faculty of medicine, Alexandria University, Jan 2018.  
The study was registered at Clinical Trial. Gov (NCT03900299).

All procedures in this study involving human participants were performed in accordance with the 1964 Helsinki Declaration and its later amendments.

## Conflict of Interest

No conflict of interest was declared by the authors.

## Financial Disclosure

The authors declared that this study has received no financial support.

## Published

2021 October 14

Copyright © 2021 The Author(s)  
Published by JOSAM

This is an open access article distributed under the terms of the Creative Commons Attribution-NonCommercial-NoDerivatives License 4.0 (CC BY-NC-ND 4.0) where it is permissible to download, share, remix, transform, and buildup the work provided it is properly cited. The work cannot be used commercially without permission from the journal.



## Abstract

**Background/Aim:** Multifocal breast cancers (MFBCs) still have undiscoverable clinical significance. Being the standard surgical management for early breast cancer, implementation of breast-conservation therapy (BCT) as a surgical procedure for multifocal breast cancers is still questionable and needs a solid basis of clinical evidence via prospective randomized control trials.

**Methods:** A prospective study was conducted on female patients with operable multifocal breast cancer excluding those diagnosed with inflammatory breast cancer and those to receive neoadjuvant therapy. Surgical management was selected randomly and comprised either modified radical mastectomy (MRM) or different techniques of oncoplastic breast surgery (OPS) with a sealed envelope system based on clinical evaluation and recent guidelines for management at the Surgical Oncology Unit, Alexandria University from May 2017-May 2018. The patients were followed up until February 2021 with a median follow-up of 39 months postoperatively to assess recurrence. Analysis of different clinicopathological factors was performed to evaluate the reliability of OPS in the surgical management of MFBCs.

**Results:** A total of 132 patients were initially assessed for the eligibility criteria. Finally, 58 patients in the OPS group and 56 patients in the MRM group were followed up until the end of the study period. After a median follow-up of 39 months post-operatively for both groups, three patients belonging to the oncoplastic group suffered from local recurrence (5.2%). Two patients who had MRM had distant recurrence (3.6%). Although recurrence behavior was different between both groups, this was not statistically significant.

**Conclusion:** OPS is an oncologically safe surgical option for selected cases of multifocal breast cancer.

**Keywords:** Breast cancer, Multifocal, Recurrence

## Introduction

Multifocal breast cancers (MFBCs) represent a discrete and important oncological issue. The incidence of MFBCs varies from 6% to 60% among breast cancers worldwide [1, 2]. MFBCs are defined when there are two or more synchronous cancerous foci within the same quadrant. The size of the largest tumor focus is considered for the TNM staging system [3].

MFBCs are currently encountered in the surgical oncology field more than in previous decades mostly due to the revolution in the diagnostic modalities of breast cancer. Better guidelines for their management are needed, especially regarding the optimal loco-regional therapy and their impact on survival [4-6].

Being the standard surgical management for early breast cancer, implementation of breast-conservation therapy (BCT) as a surgical procedure for MFBCs is still questionable and needs a solid basis of clinical evidence with prospective randomized control trials [7].

Conventional contraindications to BCT include any clinical conditions which may alter local control and or cosmesis. Multifocal breast cancers may be included in this category [7-10]. However, there is now growing evidence to suggest that oncoplastic conservative surgery (OPS) can be a suitable surgical procedure with acceptable local control rates [11-16].

OPS is divided into the volume-displacement procedure which includes resection with a variable volume of breast tissue, rearrangements, and mammoplasty techniques [7, 8], and volume-replacement procedures, which entails resection with immediate reconstruction using loco-regional flaps [9, 10]. In all cases, simultaneous or delayed correction in the contralateral breast can be done to achieve better symmetry [11].

The present study is directed to analyze, in a prospective series of breast cancer patients treated at a single institution, the reliability of oncoplastic breast conservative surgery as a surgical treatment for selected cases of MFBCs in terms of oncological safety.

## Materials and methods

### Study design and randomization

In this non-blinded two-arms parallel design randomized clinical trial, multifocal breast cancer patients were first randomly selected by the simple random sampling method. Patients were assessed for eligibility and randomly allocated at a ratio of 1:1 to either the OPS arm or MRM arm using simple randomization by tables of random number generator. Concealed allocation was achieved by sequentially numbered opaque sealed envelopes technique and by keeping the executive of the randomization unaware of study participants' sequence.

### Eligibility

**Inclusion criteria:** Operable female patients with MFBC diagnosed on a clinical and/or radiological basis and proved by core needle who were admitted to the Surgical Oncology Unit, Faculty of Medicine, University of Alexandria.

**Exclusion criteria:** Patients to receive neoadjuvant treatment or inflammatory carcinoma were excluded because of the tendency towards worse prognosis in the tumor characteristics rather than in the surgical procedure. Also, the

method of localization of multifocal disease is a matter of debate [8].

### Data collection

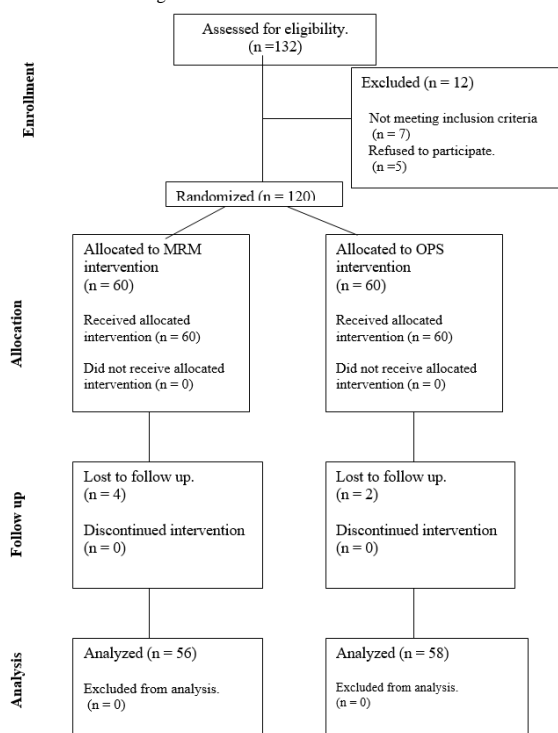
Patients diagnosed as having MFBC signed informed written consent before being enrolled in the study. They were diagnosed as MFBC on clinical and/or mammographic findings. However, MRI was resorted to whenever the mammographic findings were not conclusive (e.g., dense breast, asymmetrical architecture distortion, and lobular carcinoma). Patients were subjected to either total mastectomy or oncoplastic conservative breast surgery according to the arm of the study. Safety margin was assured in the second group by intraoperative pathological assessment. This was performed by the inking of different margins and imprinting of cytological examination of all margins by a dedicated pathologist. Effective communication between the surgeon and the attending pathologist was assured for describing the site and size of the different foci and their relation to each other and concordance with prior imaging studies. Clear margins were defined as no ink on the tumor [8].

Axillary dissection or sentinel node biopsy was performed according to the clinical and radiological states of the axilla.

Patients who underwent total mastectomy were offered different options for immediate reconstruction, only 3 (5.35%) out of 56 patients of the mastectomy accepted immediate reconstruction in the form of autologous pedicled transverse rectus abdominis muscle flap (TRAM flap) to avoid a second surgery.

The CONSORT diagram shows the flow of participants through each stage of the randomized trial (Figure 1).

Figure 1: The CONSORT diagram



After surgical intervention, the following data were recorded:

- **Tumor characteristics:** Size, nodal status, presence of lymphovascular invasion, amount of intraductal component, tumor grade, margin status, hormone receptor, and Her2 status.

- **Rate of re-excision:** If needed, was based on permanent histopathological examination of the excised specimen in patients who underwent OPS.
- **Postoperative surgical complications** or any other procedure-related problems.

All patients were scheduled for clinical follow-up every 6 months with an overall follow-up period of 39 months.

- A mammogram (or ultrasonographic examination of the mastectomy bed) and metastatic workup survey/year. The occurrence of loco-regional recurrence and distant metastases during the follow-up period were documented.

**Outcomes**

1. Loco-regional recurrence or distant metastases during the follow-up period.
  - Local recurrence is defined as recurrence in the original tumor bed of OPS or the mastectomy field.
  - Regional recurrence refers to metastatic disease in the ipsilateral axilla or supraclavicular lymph nodes or ipsilateral involvement of internal mammary nodes.
2. The disease-free survival of patients was estimated using the Kaplan-Meier method.

**Sample size calculation**

Previous studies illustrated an overall survival of 94% vs. 90% among patients undergoing breast conservation relative to the group treated with mastectomy, respectively, with no significant difference [17]. If there is truly no difference between the standard and experimental treatment (around 94% in both groups), then 110 patients (55 per each intervention arm) are needed to be 95% sure that the limits of a two-sided 95% confidence interval will exclude a difference between the standard and experimental group of more than 15%. The calculation was based on the following formula for equivalence trial to achieve 80% power at 0.05 significance level:

Calculation based on the formula [18]:

$$n = 2 \times f(\alpha, \beta/2) \times \pi \times (100 - \pi) / d^2$$

where  $\pi$  is the true percent “success” in both the control and experimental treatment groups, and

$$f(\alpha, \beta) = [\Phi^{-1}(\alpha) + \Phi^{-1}(\beta)]^2$$

where  $\Phi^{-1}$  is the cumulative distribution function of a standardized normal deviate. We anticipated a potential loss of follow-up of 10%. To account for this, we initially enrolled 132 patients in the trial.

**Ethical consideration**

The study was approved by the ethical committee of the Faculty of Medicine, University of Alexandria. Also, the study was registered in clinicaltrials.gov (NCT03900299).

<https://clinicaltrials.gov/ct2/show/NCT03900299?recrs=d&cond=Breast+Cancer&cntry=EG&draw=2&rank=2>

The patients’ records were kept confidential and all signed informed consent forms.

**Statistical analysis**

Data are expressed as mean (SD), and numbers or percentages where appropriate. The Chi-square test was performed to study the significant associations between categorical variables. Fischer exact significance, as well as Monte-Carlo significance, were used if more than 20% of the total expected cell counts <5 at 0.05 level of significance. Kaplan-Meier survival analysis was conducted to compare

overall survival and recurrence-free survival outcomes between the two interventions using the Log-rank test. All statistical tests were judged at a 0.05 significance level using IBM SPSS statistics program version 21.

**Results**

A total of 132 patients were initially assessed for eligibility. Twelve patients were excluded, five refused to participate after enrollment, and 7 patients did not meet the eligibility criteria. Sixty patients were randomized, and 2 patients in the OPS group and 4 patients in the MRM group were lost to follow-up. Finally, 58 patients who were subjected to OPS and 56 patients who underwent MRM continued follow-up (CONSORT diagram).

A summary of the clinicopathological characteristics of patients is given in Table 1. Both groups were similar regarding their age, stage, tumor size, histopathological type, grade, and lymphovascular invasion, presence of excessive intraductal component, hormonal status & Her2 expression.

The adjuvant treatments administered in both groups, whether chemotherapy, radiotherapy, or hormonal, is illustrated in Table 1.

Table 1: A summary of the clinicopathological characteristics of patients

Item	OPS (n=58)		MRM (n=56)		X <sup>2</sup>	P-value	
	No	%	No	%			
Age in years	<40	5	8.6%	3	5.4%	4.011	MC P=0.265
	40-	18	31.0%	10	17.9%		
	50-	14	24.1%	14	25.0%		
	60+	21	36.2%	29	51.8%		
T staging	T1	34	58.6%	23	41.1%	4.139	MC P=0.075
	T2	24	41.4%	32	57.1%		
	T3	0	0.0%	1	1.8%		
N staging	N0	32	55.2%	26	46.4%	0.872	0.351
	N1	26	44.8%	30	53.6%		
	N2	0	0.0%	0	0.0%		
STAGE	I	21	36.2%	12	21.4%	3.773	MC P=0.100
	II	37	63.8%	43	76.8%		
	III	0	0.0%	1	1.8%		
Histopathology	IDC	58	100.0%	55	98.2%	1.045	0.491
	Mucoid	0	0.0%	1	1.8%		
GRADE	II	57	98.3%	56	100.0%	0.947	1.000
	III	1	1.7%	0	0.0%		
	IV	0	0.0%	0	0.0%		
Estrogen	-ve	6	10.3%	3	5.4%	5.794	MC P=0.123
	+	5	8.6%	11	19.6%		
	++	18	31.0%	23	41.1%		
	+++	29	50.0%	19	33.9%		
Progesterone	-ve	7	12.1%	7	12.5%	0.332	0.954
	+	10	17.2%	11	19.6%		
	++	32	55.2%	28	50.0%		
	+++	9	15.5%	10	17.9%		
HER2	-ve	54	93.1%	51	92.7%	2.289	MC P=0.555
	+	1	1.7%	3	5.5%		
	++	1	1.7%	0	0.0%		
	+++	2	3.4%	1	1.8%		
Intra ductal component	No	47	81.0%	37	66.1%	3.290	0.070
	Yes	11	19.0%	19	33.9%		
LVI	No	26	44.8%	28	50.0%	0.306	0.580
	Yes	32	55.2%	28	50.0%		
POS CHM	No	0	0.0%	2	3.6%	2.108	FE P=0.239
	Yes	58	100.0%	54	96.4%		
POS XRT	No	0	0.0%	2	3.6%	2.108	FE P=0.239
	Yes	58	100.0%	54	96.4%		
POS HOR	No	2	3.4%	1	1.8%	0.307	FE P=1.000
	Yes	56	96.6%	55	98.2%		

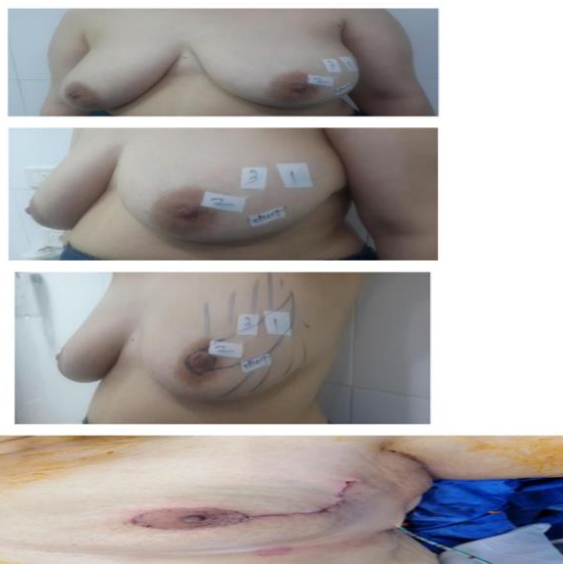\* Chi-square test, <sup>FE</sup>P: Fisher exact probability, \* P<0.01 (highly significant), <sup>MC</sup>P: Monte Carlo exact probability, \*\* P<0.05 (significant)

**Regarding patients who had OPS:** Various oncological techniques were utilized (Table 2). Lateral therapeutic mammoplasty was the commonest technique adopted; it was used in 20 patients (34.48%) who had tumors located in the upper outer quadrant (Figure 2).

Table 2: Oncoplastic techniques used in the study

OPS	Tumor location	Number of cases
Lateral therapeutic mammoplasty Round block	Upper outer quadrant	20(34.48%)
	Upper outer quadrant	14(24.13%)
	Lower inner quadrant	
	Lower outer quadrant	
	Upper inner quadrant	
Parallelogram lumpectomy	Upper outer quadrant	9(15.51%)
	Upper pole	
	Upper inner quadrant	
J therapeutic mammoplasty	Lower pole	4(6.89%)
	V therapeutic mammoplasty	4(6.89%)
LD FLAP	Lower inner quadrant	
	Upper outer quadrant	3(5.17%)
Reduction therapeutic mammoplasty	Upper outer quadrant	2(3.44%)
	Upper inner quadrant	
Grisotti flap	Upper inner quadrant	
	Central (retro areolar)	2(3.44%)

Figure 2: Pre-operative markings of therapeutic lateral mammoplasty and outcome after the remodeling of breast tissue.



Five patients (8.6%) required re-excision after frozen section examination of the excised specimen margins. The results of the margin assessment were confirmed on the final examination of the permanent paraffin block.

Postoperative complications were encountered in 33.92% and 31.03% in the MRM & OPS groups, respectively. They were diverse, related to the nature of the procedure performed, and statistically not significant with  $P=0.90$  for early complications and  $P=0.57$  for late complications (Table 3).

Table 3: Postoperative complications after OPS and MRM

	MRM (n=56)	OPS (n=58)	P-value
Early complications			0.900
Hematoma	2(3.57%)	1(1.72%)	
Seroma	11(19.64%)	8(13.79%)	
Abscess	1(1.78%)	2(3.44%)	
Skin or Flap necrosis	2(3.57%)	2(3.44%)	
Total no of complications	16(28.57%)	13(22.41%)	
No complications	40(71.42%)	45(77.59%)	
Late complications			0.579
Scar fibrosis	1(1.78%)	1(1.7%)	
Keloid	2(3.57%)	2(3.44%)	
Steatonecrosis	0	2(3.44%)	
Total no of complications	3(5.35%)	5(8.62%)	
No complications	53(94.65%)	53(91.38%)	

After a median follow-up period of 39 months, three patients belonging to the oncoplastic group suffered from local recurrence (5.2%) and two patients who had MRM had distant recurrence (3.6%). Although the recurrence pattern differed between the two groups, local recurrence, distant recurrence, and the overall recurrence rates were not significant ( $P=0.244$ ,  $P=0.239$ ,  $P=0.671$ , HR: 1.474 at 95% CI, respectively) (Table 4, 5).

Table 4: univariate analysis of local and distant recurrence in both groups

Item		OPS (n= 58)		Surgery MRM (n= 56)		$\chi^2$	P-value
		No	%	No	%		
Recurrence	No	55	94.8%	54	96.4%	0.174	<sup>FE</sup> $P=1.000$
	Local	3	5.2%	0	0.0%	2.975	<sup>FE</sup> $P=0.244$
	Distant	0	0.0%	2	3.6%	2.108	<sup>FE</sup> $P=0.239$

Table 5: Rate of recurrence in both groups

	No Recurrence		Recurrence		P-value	HR (95% C.I)
	No	%	No	%		
OPS	55	94.8%	3	5.2%	0.671	1.474 (0.246 – 8.820)
MRM	54	96.4%	2	3.6%		1.000

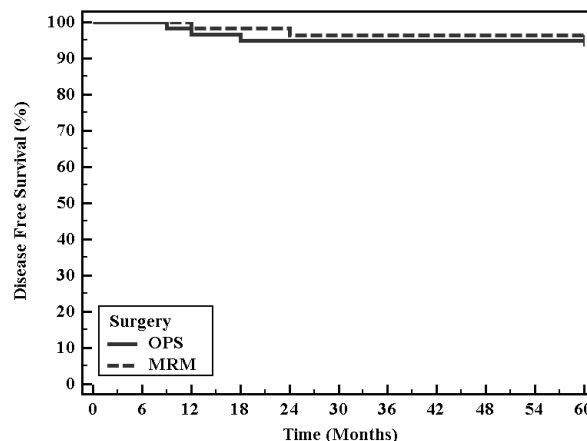
HR: Hazard ratio, CI: Confidence interval, LL: Lower limit, UL: Upper Limit

The Kaplan-Meier method revealed the disease-free survival (DFS) to be 94.8% and 96.4% in OPS & MRM groups, respectively. This difference was not significant (Figure 3, Table 6).

Table 6: Kaplan-Meier survival analysis for disease-free survival with surgery

Surgery	Mean	% 1 year	% End of study	Log-rank $\chi^2$	P-value
	OPS	57.57	96.6	94.8	0.183
MRM	58.50	98.2	96.4		

Figure 3: Kaplan-Meier survival curve for disease-free survival with surgery



## Discussion

Multifocal breast cancer is an entity that needs consideration. Its biological basis is not well understood, especially whether it is the result of a simultaneous overgrowth of tumor foci or an outcome of extensive intraductal carcinoma [19]. Many studies found it to have a different clinical outcome with a poorer prognosis if compared with unifocal breast cancer of the same stage [20] with This is attributed to the high invasive tumor burden and association with lymph node metastases [21]. The reported association between multifocality and the outcome of patients in early breast cancer is variable [20, 22, 23]. It has a higher possibility of recurrence and adverse survival after surgical treatment, especially if breast conservative surgery is performed. This paradox directed many surgeons to perform mastectomy for these patients [24, 25]. This was the reported trend in the past two decades [9, 10, 24, 26]. Recently, some studies found a lower incidence of local recurrence in patients with multifocal breast cancer treated with breast conservative surgery [27, 28]. However, most were retrospective.

Thus, the present study was conducted prospectively to compare the results of mastectomy and breast conservative therapy in the treatment of multifocal breast cancer. We included only MFBC patients diagnosed on a clinical and radiological basis. The pattern of recurrence was different between both groups; local recurrence only occurred in patients who

underwent OPS while patients who underwent MRM suffered only from distant recurrence. The overall recurrence rate and the disease-free survival (DFS) were not significantly different between the two groups.

Reviewing the literature, few studies were found investigating breast conservative therapy (BCT) and mastectomy as treatment options for MFBC. The majority found no difference between both modalities regarding local recurrence (LR) and disease-free survival (DFS) [17, 29]. Moreover, Wolters et al. found that BCT and mastectomy are suitable comparable choices in the surgical treatment of T1/2 MFBC [14]. These previous results are in agreement with our work. One of the strengths of our study is that we determined the eligibility criteria for inclusion and exclusion of patients like everyday clinical practice while applying both interventions, so the findings from this study could be generalizable. We encountered the most clinically important outcomes, and we also considered the potential complications after surgery.

Although the follow-up period in our study is relatively short, the paucity of prospective RCT addressing MFBC encouraged the authors to publish the results as a preliminary study with early results. Still, longer follow-up periods are needed. However, this study has the advantage of being a prospective one.

### Conclusions

From the present work, we can conclude that breast OPS is a safe option to treat selected cases of MFBC that can, nowadays, is better characterized with the wide use of magnetic resonance mammography. It achieves a wide resection margin enabling the removal of all tumor foci.

### References

- Yerushalmi R, Kennecke H, Woods R, Olivetto IA, Speers C, Gelmon KA. Does multicentric/multifocal breast cancer differ from unifocal breast cancer? An analysis of survival and contralateral breast cancer incidence. *Breast Cancer Res Treat.* 2009;117:365-70.
- Mona P Tan, Nadya Y Sitoh, Yih Yiow Sitoh. Optimizing breast conservation treatment for multifocal and multicentric breast cancer: A Worthwhile Endeavour? *World J Surg.* 2016;40:315-22.
- Van la Parra RF, de Roos WK, Constant CM, Bavelaar-Croon C D, Barneveld P C, Bosscha K. A prospective validation study of sentinel lymph node biopsy in multicentric breast cancer. *SMMaC trial.* *Eur J Surg Oncol.* 2014;40:1250-5.
- Wilkinson LS, Given-Wilson R, Hall T, Potts H, Sharma AK, Smith E. Increasing the diagnosis of multifocal primary breast cancer by the use of bilateral whole-breast ultrasound. *Clin Radiol.* 2005;60:573-8.
- Sardanelli F, Giuseppetti GM, Panizza P, Bazzocchi M, Fausto A, Simonetti G, et al. Sensitivity of MRI versus mammography for detecting foci of multifocal, multicentric breast cancer in Fatty and dense breasts using the whole-breast pathologic examination as a gold standard. *AJR Am J Roentgenol.* 2004;183:1149-57.
- Houssami N, Ciatto S, Macaskill P, Lord SJ, Warren RM, Dixon JM, et al. Accuracy and surgical impact of magnetic resonance imaging in breast cancer staging: Systematic review and meta-analysis in detection of multifocal and multicentric cancer. *J Clin Oncol.* 2008;26:3248-58.
- John R Benson, Ismail Jatoi, Masakazu Toi. Surgical management of multiple ipsilateral breast cancers. *Future Oncol.* 2019;15:1185-91.
- NCCN guidelines at : [https://www.nccn.org/professionals/physician\\_gls/default.aspx](https://www.nccn.org/professionals/physician_gls/default.aspx) accessed at May 2018
- Matthijs V. Nijenhuis, Emiel J.Th. Rutgers. Conservative surgery for multifocal/multicentric breast cancer. *The Breast.* 2015;24:S96-99.
- Wilson LD, Beinfeld M, McKhamm CF, Haffty BG. Conservative surgery and radiation in the treatment of synchronous ipsilateral breast cancers. *Cancer.* 1993;72:137-42.
- Bauman L, Barth RJ, Rosenkranz KM. Breast conservation in women with multifocal-multicentric breast cancer: is it feasible? *Ann Surg Oncol.* 2010;17:S325-9.
- Kapoor NM, Chung A, Huynh K, Giuliano AE. Preliminary results: double lumpectomies for multicentric breast cancer. *Am Surg.* 2012;78:1345-8.
- Ustaalioglu BO, Bilici A, Kefeli U, Şeker M, Oncel M, Gezen C, et al. The importance of multifocal/multicentric tumor on the disease-free survival of breast cancer patients. *Am J Clin Oncol.* 2012;35:580-6.
- Wolters R, Wöckel A, Janni W, Novopashenny I, Ebner F, Kreienberg R, et al. Comparing the outcome between multicentric and multifocal breast cancer: what is the impact on survival, and is there a role for guideline-adherent adjuvant therapy? A retrospective multicenter cohort study of 8,935 patients. *Breast Cancer Res Treat.* 2013;142:579-90.
- Ataseven B, Lederer B, Blöher JU, Denkert C, Gerber B, Heil J, et al. Impact of multifocal and multicentric disease on surgery and locoregional. Distant and overall survival of 6.134 breast cancer patients treated with neoadjuvant chemotherapy. *Ann Surg Oncol.* 2015;22:1118-27.
- Patani N, Carpenter R. Surgical and aesthetic considerations of conservational surgery for multifocal/multicentric breast cancer. *Breast J.* 2010;16:222-32.
- Kaplan J, Giron G, Tartert PI, Bleiweiss IJ, Estabrook A, Smith SR. Breast conservation in patients with multiple ipsilateral synchronous cancers. *J Am Coll Surg.* 2003;197(5):726-9
- Julious SA. Estimating sample sizes in clinical trial. *CRC:2009.*
- Tot T, Gere M, Pekar G, Tarjan M, Hofmeyer S, Hellberg D, et al. Breast cancer multifocality, disease extent, and survival. *Hum Pathol.* 2011;42(11):1761-9.
- Chung AP, Huynh K, Kidner T, Mirzadehgan P, Sim MS, Giuliano AE. Comparison of outcomes of breast conserving therapy in multifocal and unifocal invasive breast cancer. *J Am Coll Surg.* 2012;215(1):137-46.
- Boyages J, Jayasinghe UW, Coombs N. Multifocal breast cancer and survival: each focus does matter particularly for larger tumours. *Eur J Cancer.* 2010;46(11):1990-6.
- Joergensen LE, Gunnarsdottir KA, Lanng C, Moeller S, Rasmussen BB. Multifocality as a prognostic factor in breast cancer patients registered in Danish Breast Cancer Cooperative Group (DBCG) 1996–2001. *Breast.* 2008;17(6):587-91.
- Pedersen L, Gunnarsdottir KA, Rasmussen BB, Moeller S, Lanng C. The prognostic influence of multifocality in breast cancer patients. *Breast.* 2004;13(3):188-93.
- Vera-Badillo FE, Napoleone M, Ocana A, Templeton AJ, Seruga B, Al-Mubarak M, et al. Effect of multifocality and multicentricity on outcome in early stage breast cancer: a systematic review and meta-analysis. *Breast Cancer Res Treat.* 2014;146(2):235-44.
- Senkus E, Kyriakides S, Penault-Llorca F, Poortmans P, Thompson A, Zackrisson S, et al. Primary breast cancer: ESMO clinical practice guidelines for diagnosis, treatment and follow-up. *Ann Oncol.* 2013;24(Suppl 6):vi7-23.
- Leopold KA, Recht A, Schmitt SJ, Connolly JL, Rose MA, Silver B, et al. Results of Conservative Surgery and Radiation Therapy for Multiple Synchronous Cancers of One Breast. *Int J Radiat Oncol Biol Phys.* 1989;16(1):11-6.
- Lim W, Park EH, Choi SL, Seo JY, Kim HJ, Chang MA, et al. Breast conserving surgery for multifocal breast cancer. *Ann Surg.* 2009;249:87-90.
- Gentilini O, Botteri E, Rotmensz N, Da Lima L, Caliskan M, Garcia-Etienne CA, et al. Conservative surgery in patients with multifocal/multicentric breast cancer. *Breast Cancer Res Treat.* 2009;113:577-83.
- Kari M Rosenkranz, Karla Ballman, Linda McCall, Charlotte Kubicky, Laurie Cuttino, Huong Le-Petross, et al. The feasibility of breast-conserving surgery for multiple ipsilateral breast cancer: An initial report from ACOSOG Z11102 (Alliance) trial. *Ann Surg Oncol.* 2018;25:2858-66.

This paper has been checked for language accuracy by JOSAM editors.

The National Library of Medicine (NLM) citation style guide has been used in this paper.