

# Internal carotid artery agenesis and contralateral middle cerebral artery infarction

Fatma Şimşek<sup>1</sup>, Filiz Aktaş<sup>2</sup>

<sup>1</sup> Atatürk University, Faculty of Medicine,  
Department of Neurology, Erzurum, Turkey

<sup>2</sup> University of health sciences education research  
hospital neurology, Konya, Turkey

**ORCID ID of the author(s)**

FŞ: 0000-0003-1662-5534  
FA: 0000-0003-2973-916X

## Abstract

Internal carotid artery agenesis is usually an asymptomatic condition. It is detected incidentally by radiological imaging performed for other reasons. It may rarely present with clinical manifestations such as subarachnoid hemorrhage associated with aneurysm, transient ischemic attack, or stroke. Agensis can be erroneously interpreted as occlusion in case of insufficient clinical experience. The absence of the carotid canal on the bone window in the computed tomography scan of the brain helps confirm the diagnosis. The well-developed collateral circulation in patients with internal carotid artery agenesis is an effective factor in recovering from cerebrovascular diseases with less damage. Here, a rare case of agenesis of the right internal carotid artery and contralateral middle cerebral artery infarction is presented.

**Keywords:** Internal carotid artery, Ischemic stroke, Agensis, Magnetic resonance angiography

## Introduction

The agenesis of the internal carotid artery (ICA) occurs due to abnormal regression of the first and third aortic arch, with an unclear exact etiology [1, 2]. Carotid agenesis is a rare condition that can be unilateral or bilateral. Documented cases with absent ICA are mostly unilateral and most frequently reported on the left side [3, 4]. Most cases are clinically silent due to the well-developed collateral circulation [5]. Most patients are detected by radiological imaging methods, such as ultrasonography, magnetic resonance imaging, computed brain tomography, performed for a different reason. Inadequate collateral flow may result in cerebrovascular events and/or intracranial bleeding, which may emerge as cerebrovascular disease [6, 7]. We here report a case with agenesis of the right ICA and contralateral middle cerebral artery infarction, a rare phenomenon.

### Corresponding Author

Fatma Şimşek  
Atatürk Üniversitesi Tıp fakültesi Nöroloji  
Anabilim Dalı, Erzurum, Turkey  
E-mail: klamaks@hotmail.com

### Informed Consent

The authors stated that the written consent was obtained from the patient presented with images in the study.

### Conflict of Interest

No conflict of interest was declared by the authors.

### Financial Disclosure

The authors declared that this study has received no financial support.

### Published

2021 Jun 9

Copyright © 2021 The Author(s)

Published by JOSAM

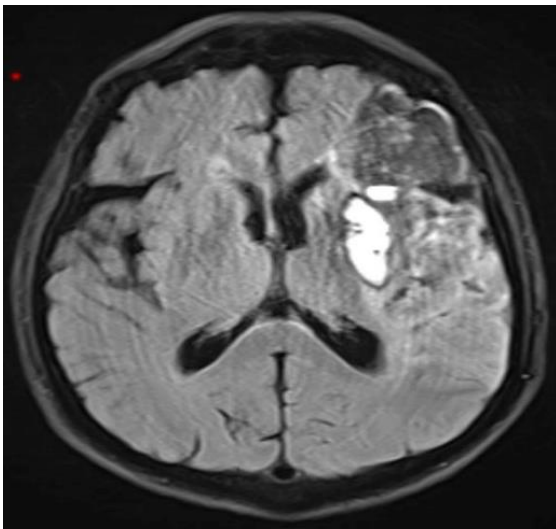
This is an open access article distributed under the terms of the Creative Commons Attribution-Non Commercial-NoDerivatives License 4.0 (CC BY-NC-ND 4.0) where it is permissible to download, share, remix, transform, and build upon the work provided it is properly cited. The work cannot be used commercially without permission from the journal.



## Case presentation

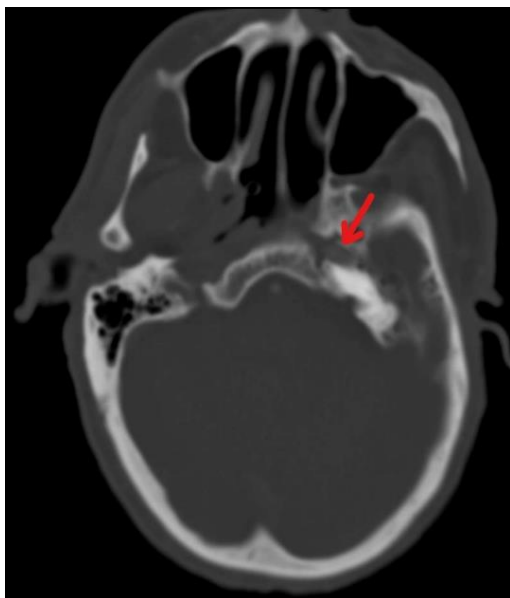
A 64-year-old male patient with no history of systemic disease was admitted to the emergency department due to sudden right-sided weakness. In the neurological examination, the patient was somnolent with partial space-time orientation and cooperation. He had central facial paralysis on the left and 3/5 motor strength on the right with extensor reflex responses. The patient had a history of smoking one packet of cigarettes a day for 25 years. The family history was insignificant. Intravenous thrombolytic therapy could not be administered due to the hemorrhagic infarction in the left middle cerebral artery watershed area, revealed by the computed tomography of the brain (CT) performed in the emergency department. The admission magnetic resonance imaging (MRI) and magnetic resonance angiography (MRA) failed to reveal the right internal carotid artery. There was a hemorrhagic infarct area on the left on MRI (Figure 1).

Figure 1: The FLAIR MRI sequence shows hemorrhagic infarction in the middle cerebral artery watershed area on the left side



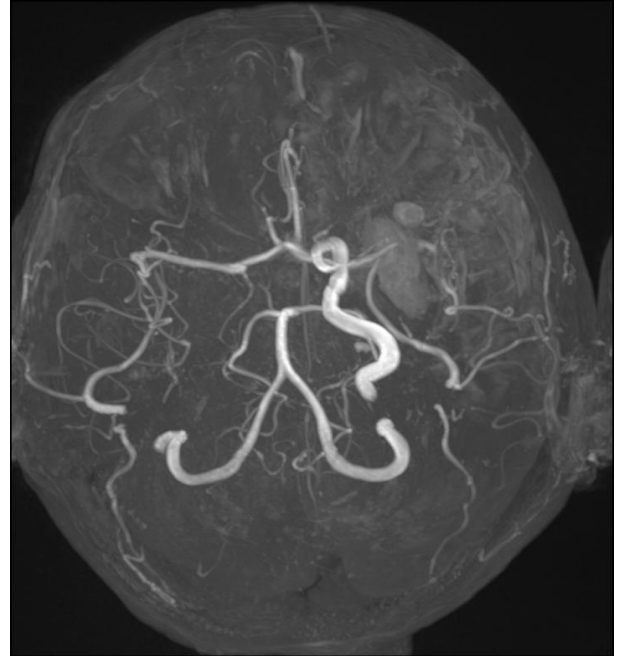
The right ICA was thought to be totally occluded. The bone window in the CT scan of the brain showed the carotid canal on the left while the carotid canal was absent on the right, confirming the diagnosis of agenesis of the right ICA (Figure 2).

Figure 2: The bone window in the CT scan of the brain shows the carotid canal on the left (red arrow), while the right carotid canal is absent.



Aneurysm is a common accompanying pathology in patients with ICA agenesis. In our patient, MRA revealed no aneurysm showing that the right middle cerebral artery and right anterior cerebral artery received collateral circulation through the anterior communicating artery and the left ICA, which appeared dolichoectatic (Figure 3).

Figure 3: MRA shows the right middle cerebral artery and right anterior cerebral artery receiving collateral circulation through the anterior communicating artery while the left ICA appears dolichoectatic.



The patient's cardiac examination (Echocardiography and 24-hour rhythm Holter), blood lipids, HbA1C, homocysteine level and blood pressure were normal. The patient, who had no risk factors other than smoking, was discharged after 4 weeks with a moderate-well condition and 4/5 motor strength on the right side. At the 3-month follow-up, he was able to walk with one-sided support and perform daily activities without help. Informed consent was obtained from the patient for scientific presentation.

## Discussion

Agenesis of the ICA and hypoplasia are rare congenital anomalies occurring in less than 0.01% of the population [8]. The left ICA is affected by dysgenesis three times more often than the right one [4].

Our patient had agenesis of the right ICA and left middle cerebral artery infarction. Agenesis of the right ICA was confirmed when the bone window in the CT scan of the brain showed no carotid canal, although it was interpreted as total occlusion of the right ICA in the initial MRI. The presence of ICA is necessary for the development of the carotid canal, the absence of which can confirm ICA agenesis. It is a rare condition that can be erroneously interpreted as stenosis or occlusion in case of insufficient clinical experience. Although our patient had agenesis of the right ICA and left MCA infarction, his clinical condition was not very severe. This was thought to be associated with the well-developed collateral circulation due to cerebral vascular anomaly. The fact that the patient remained asymptomatic until the age of 65 years supports the well-development of collateral circulation in these patients.

While collateral flow through the Willis circle is usually sufficient to prevent cerebral ischemia during carotid clamping, an incomplete and dysfunctional circle poses increased risk [9, 10]. Agensis of the ICA is a rare condition that alters the collateral circulation in the circle. Cross-clamping the side with ICA during surgery in a patient with ICA agenesis can disrupt the blood supply of the whole brain, causing irreversible damage. Ultrasonography, an easy and inexpensive method, can be used to monitor ICAs to prevent possible complications in surgical procedures as a protective factor in reducing the risk of possible cerebrovascular complications. The other ICA should be checked, especially in the presence of a dolichoectatic ICA, as in our patient.

## References

1. Kunishio K, Yamamoto Y, Sunami N, Asari S. Agensis of the left internal carotid artery, common carotid artery, and main trunk of the external carotid artery associated with multiple cerebral aneurysms. *Surgical neurology*. 1987;27(2):177-81. doi: 10.1016/0090-3019(87)90292-8.
2. Cohen JE, Gomori JM, Leker RR. Internal carotid artery agenesis: diagnosis, clinical spectrum, associated conditions and its importance in the era of stroke interventions. *Neurological research*. 2010;32(10):1027-32. doi: 10.1179/016164110X12767786356273.
3. Alurkar A, Karanam LSP, Oak S, Kori S. Congenital absence of internal carotid artery with rare type of intercavernous anastomosis and ruptured cerebral aneurysm. *Journal of clinical and diagnostic research:JCDDR*. 2016;10(4):TD03. doi: 10.7860/JCDDR/2016/17797.7549.
4. Taşar M, Yetişer S, Taşar A, Uğürel Ş, Gönül E, Sağlam M. Congenital absence or hypoplasia of the carotid artery: radioclinical issues. *American journal of otolaryngology*. 2004;25(5):339-49. doi: 10.1016/j.amjoto.2004.04.008.
5. Ryan FH, Kline LB, Gomez C. Congenital Horner's syndrome resulting from agenesis of the internal carotid artery. *Ophthalmology*. 2000;107(1):185-8. doi: 10.1016/S0161-6420(99)00006-8.
6. Damry N, Hanquinet S, Christophe C, Janssen F, Delatte P, Perlmutter N. Bilateral congenital absence of the internal carotid artery with a primitive transmaxillary arterial anastomosis. *Pediatric radiology*. 1994;24(3):200-3.
7. Farhat W, Ahdab R, Hosseini H. Congenital agenesis of internal carotid artery with ipsilateral Horner presenting as focal neurological symptoms. *Vascular Health and Risk Management*. 2011;7:37. doi: 10.2147/VHRM.S16642.
8. Given II CA, Huang-Hellinger F, Baker MD, Chepuri NB, Morris PP. Congenital absence of the internal carotid artery: case reports and review of the collateral circulation. *American Journal of Neuroradiology*. 2001;22(10):1953-9.
9. Kim GE, Cho YP, Lim SM. The anatomy of the circle of Willis as a predictive factor for intra-operative cerebral ischemia (shunt need) during carotid endarterectomy. *Neurological research*. 2002;24(3):237-40. doi: 10.1179/016164102101199846.
10. Moritz A, Koci G, Steinlechner B, Hölzenbein T, Nasel C, Grubhofer G, et al. Contralateral stroke during carotid endarterectomy due to abnormalities in the circle of Willis. *Wiener klinische Wochenschrift*. 2007;119(21):669-73.

This paper has been checked for language accuracy by JOSAM editors.

The National Library of Medicine (NLM) citation style guide has been used in this paper.