

# A rare cause of hyperamylasemia: A case with pneumothorax and subcutaneous emphysema around the parotid gland in a trauma patient

Rıfat Peksöz<sup>1</sup>, Orhan Asya<sup>2</sup>

<sup>1</sup> Muş State Hospital, General Surgery Unit, Muş, Turkey

<sup>2</sup> Muş Malazgirt State Hospital, Department of Otolaryngology, Muş, Turkey

**ORCID ID of the author(s)**

RP: 0000-0003-4658-5254  
OA: 0000-0003-0366-3099

## Abstract

Amylase is a common laboratory test in emergency departments, especially in trauma patients. Although hyperamylasemia is mostly caused by injury to the pancreas in trauma patients, non-pancreatic causes of hyperamylasemia are not rare. Being aware of these causes may prevent unnecessary diagnostic tests. In this study, we presented a trauma patient with hyperamylasemia of non-pancreatic origin. Possible mechanisms of hyperamylasemia in our case are acute hypoxia-induced hyperamylasemia because of left lung pneumothorax and massage-like activity of subcutaneous emphysema around the parotid gland.

**Keywords:** Hyperamylasemia, Acute pancreatitis, Pneumothorax, Subcutaneous emphysema, Parotitis

## Introduction

Amylase is a common laboratory test in emergency departments and other clinics, especially during the examination of patients presenting with abdominal pain. Although serum amylase levels are used in the diagnosis of salivary gland and pancreatic disorders, they have been observed to increase in many diseases [1]. One of the most common causes of amylase elevation other than pancreatic diseases is salivary gland diseases such as acute parotitis, but it may rarely be due to the release of intracellular amylase of the lung tissue because of hypoxia [2]. In this case report, we aimed to discuss the etiology of hyperamylasemia that may be caused by pneumothorax and periparotid subcutaneous emphysema in light of the literature and raise awareness that hyperamylasemia may also be a result of non-pancreatic problems, especially in patients presenting with trauma.

### Corresponding Author

Rıfat Peksöz  
Muş State Hospital, General Surgery Unit, Muş,  
Turkey  
E-mail: rifat-peksoz@hotmail.com

### Informed Consent

The authors stated that the written consent was obtained from the patient presented with images in the study.

### Conflict of Interest

No conflict of interest was declared by the authors.

### Financial Disclosure

The authors declared that this study has received no financial support.

### Previous Presentation

This article was presented orally at the 3rd International Congress of Academic Research (20-22 July 2020, Bolu, Turkey)

### Published

2021 May 15

Copyright © 2021 The Author(s)

Published by JOSAM

This is an open access article distributed under the terms of the Creative Commons Attribution-Non Commercial-NoDerivatives License 4.0 (CC BY-NC-ND 4.0) where it is permissible to download, share, remix, transform, and build upon the work provided it is properly cited. The work cannot be used commercially without permission from the journal.



**How to cite:** Peksöz R, Asya O. A rare cause of hyperamylasemia: A case with pneumothorax and subcutaneous emphysema around the parotid gland in a trauma patient. J Surg Med. 2021;5(5):553-555.

## Case presentation

A 52-year-old male patient was brought to the emergency department after an in-car traffic accident. The general condition of the patient was moderate, he could not cooperate due to mental retardation. Head and neck, and abdominal examinations were initially normal. Pelvis fracture was present. There was no edema, laceration, or hematoma in the head and neck region. Cranial and abdominal computed tomography imaging were normal. Computed tomography of the thorax was consistent with minimal pneumothorax of the left lung. The laboratory findings of the patient on admission were as follows: WBC: 12.95 ( $4.4-11 \times 10^3/\mu\text{l}$ ), AST: 198 (0-40 IU/L), ALT: 167 (0-41 IU/L), amylase: 249 (28-100 U/L), lipase: 102 (0-60 U/L). The patient was admitted to the intensive care unit for close follow-up due to a pelvic fracture and minimal pneumothorax in the left lung. One day after hospitalization, abdominal examination was normal, breath sounds were decreased in the left hemithorax, and crepitus was detected in the left side extending from the lumbar region up to the neck and periparotid region that was consistent with subcutaneous emphysema. Control computed tomography of the thorax was consistent with extended pneumothorax of the left lung and subcutaneous emphysema from the lumbar region up to the parotid gland (Figures 1 and 2). The pancreas gland was normal on control abdominal computed tomography examination (Figure 3).

Figure 1: Coronal computed tomography scan, left pneumothorax and left sided subcutaneous emphysema extending from the lumbar region up to the neck

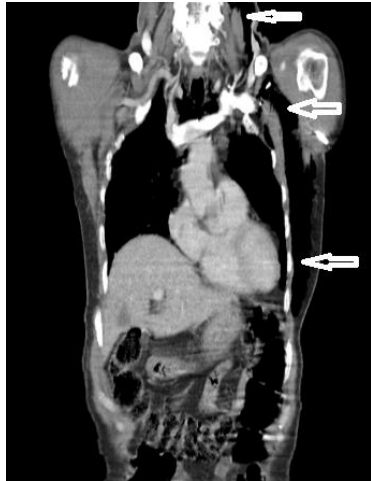

Figure 2: Axial computed tomography scan, subcutaneous emphysema around the parotid gland

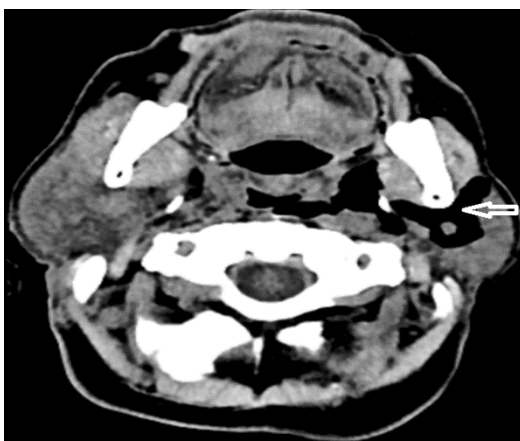
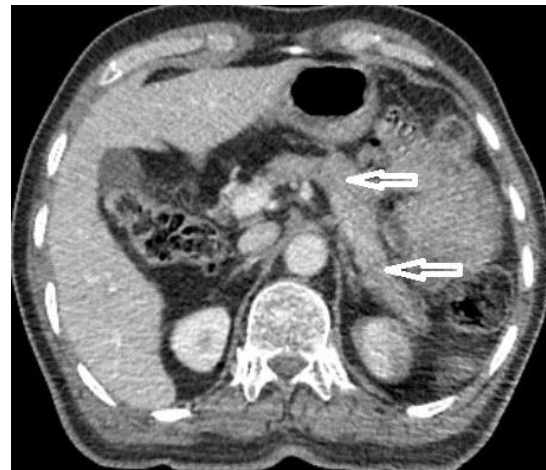


Figure 3: Axial computed tomography scan, normal looking pancreas gland with no pathology (White arrows)



There was no parenchymal abnormality in the parotid gland on ultrasonographic examination. After one day of hospitalization, control laboratory tests were as follows: WBC: 17.08 ( $4.4-11 \times 10^3/\mu\text{l}$ ), AST: 66 (0-40 IU/L), ALT: 92 (0-41 IU/L), amylase 753 (28-100 U/L), lipase 11 (0-60 U/L). The patient underwent a tube thoracostomy. On the first day of tube thoracostomy, amylase decreased from 753 to 471 U/L, and on the third day, it was 65 U/L. All biochemical laboratory findings returned to normal and subcutaneous emphysema completely regressed. The patient was discharged on the 9<sup>th</sup> day of hospitalization. Informed consent was obtained from the patient.

## Discussion

Hyperamylasemia can occasionally cause diagnostic confusion. Amylase is mostly released from the pancreas and salivary glands. Its serum level increases mostly in acute pancreatitis and salivary gland inflammation. Therefore, the pancreatic disease is usually suspected in cases of hyperamylasemia. However, amylase may be elevated in many other clinical conditions, such as salivary gland, gynecological, cardiovascular, neurological, renal, and gastrointestinal diseases [3]. Acute pancreatitis is diagnosed if two of the three following criteria are present: Abdominal pain, serum amylase-lipase levels three-fold of the upper reference range and accompanying imaging findings [4]. Elevated amylase levels without abdominal pain or imaging abnormality in the pancreas made us consider etiologic factors other than acute pancreatitis. Several studies have shown that lipase levels have higher sensitivity and specificity than amylase levels in the diagnosis of acute pancreatitis. The sensitivity and specificity of lipase elevation in patients with acute pancreatitis are between 85–100% and 84.7–99.0%, respectively [5]. In our case, although the level of amylase persisted above normal value, the lipase level was normal. Because of these reasons, acute pancreatitis was not considered in our patient and non-pancreatic causes of amylase elevation were investigated. Inflammatory diseases of the salivary gland are the leading non-pancreatic causes of elevated serum amylase. In our patient, no parenchymal damage was detected in the parotid gland. Pneumothorax in the left lung and emphysema around the parotid gland was thought to be two possible causes of amylase elevation. It was reported that the lung might serve as the site of origin for serum amylase activity under hypoxia [2]. Although its exact mechanism is unclear, it

may be due to the disturbance in cellular metabolism with a release of intracellular amylase. Jam et al. [2] reported that acute hypoxemia may raise serum amylase activity through ischemic injury to the pancreas or salivary glands. Li et al. [6] reported that acute respiratory failure increases serum amylase level of lung origin independent of parenchymal damage. Pneumothorax causing acute hypoxemia is one of the possible causes of hyperamylasemia in our patient. Evcimik et al. [7] found that massaging the parotid gland increases serum amylase activity in patients with acute parotitis, and not in patients with normal parotid parenchyma. Regardless, we thought that periparotid long-standing emphysema may cause an increase in amylase level despite normal parotid parenchymal architecture. This may be the second possible mechanism of hyperamylasemia in our case.

### Conclusion

In trauma patients with elevated amylase levels, non-pancreatic etiology should be kept in mind. Acute hypoxemia because of left lung pneumothorax and subcutaneous emphysema around the parotid gland are the two possible causes of elevation in serum amylase levels in our patient. It is not known to what extent these two etiologic factors contribute to the increase in serum amylase. Although the role of acute hypoxemia is more well known, long-standing pressure on the parotid gland may have a massage-like activity that increases serum amylase. To the best of our knowledge, there is no study to investigate the relationship between subcutaneous emphysema around the parotid gland and serum amylase levels. A study on patients with subcutaneous emphysema around the parotid gland without pneumothorax will help us learn the effect of emphysema on serum amylase.

### References

1. Vissers RJ, Abu-Laban RB, McHugh DF. Amylase and lipase in the emergency department evaluation of acute pancreatitis. *The Journal of Emergency Medicine*. 1999;17(6):1027-37.
2. Jam I, Shoham M, Wolf R, Mishkin S. Elevated Serum Amylase Activity in the Absence of Clinical Pancreatic or Salivary Gland Disease. *American Journal of Gastroenterology*. 1978;70(5).
3. Yalnız M, Asoğlu M, Demirel U, Aygün C, Bahçecioğlu İH. Hiperamilazemili bir vaka: Makroamilazemi? Literatürün gözden geçirilmesi. *J Clin Exp Invest*. 2011;2(1).
4. Kirişima S, Gabata T, Takada T, Hirata K, Yoshida M, Mayumi T, et al. New diagnostic criteria of acute pancreatitis. *Journal of Hepato-Biliary-Pancreatic Sciences*. 2010;17(1):24-36.
5. Hart AR, Johnson G, Huggett MT. Progressing pancreaticobiliary medicine in the UK. *Frontline Gastroenterology*. 2019;10(3):206-7.
6. Li T. Hyperamylasemia in acute exacerbation of patients with chronic respiratory failure. *Zhonghua Nei Ke Za Zhi*. 1992;31(3):154-6, 88.
7. Evcimik MF, Çakır BÖ, Cırık AA, Cevizci R, Soylu E, Günay C. The effect of parotid gland examination and massage on serum amylase levels in patients with acute parotitis. *ENT Updates* 2016;6(3):131-4.

This paper has been checked for language accuracy by JOSAM editors.

The National Library of Medicine (NLM) citation style guide has been used in this paper.