

Laparoscopic management of a rare case of a giant ovarian mucinous cystadenoma occupying the entire abdominopelvic cavity: A case report

Aliou Zabeirou ¹, Lassey James Didier ², Hama Younssa ², Saidou Adama ², Younoussa Moussa ¹, Maman Bachir Abdoulaye ³, Sani Rachid ², Madi Nayama ²

¹ Department of general and Visceral Surgery, Hôpital Général de Référence; Niamey, Niger
² Faculty of Health Sciences, Abdou Moumouni University of Niamey, Niamey, Niger
³ Faculty of Health Sciences, University of Maradi, Niamey, Niger

ORCID of the author(s)

AZ: <https://orcid.org/0000-0001-6152-210X>
LJD: <https://orcid.org/0009-0009-3685-9777>
HY: <https://orcid.org/0000-0002-0316-9077>
SA: <https://orcid.org/0009-0003-1195-1741>
YM: <https://orcid.org/0009-0001-1772-5409>
MBA: <https://orcid.org/0000-0001-6145-6739>
SR: <https://orcid.org/0000-0003-4494-3804>
MN: <https://orcid.org/0009-0004-7372-8040>

Abstract

Ovarian mucinous cystadenoma represents 15-20% of all ovarian epithelial tumors. They have good prognoses. In developed countries, giant ovarian mucinous cystadenoma is rarely reported due to the availability of advanced imaging technologies that enable early diagnosis and treatment. Late medical consultation and limited resources in African countries lead to late diagnosis of giant ovarian cysts. Only a few cases of laparoscopic management of massive ovarian cysts have been reported in the medical literature. We present the case of a 64-year-old black African patient with intestinal transit disorders who complained of progressive abdominal distension for 2 years. An enhanced abdominopelvic computed tomography scan revealed a giant ovarian cyst occupying the entire abdominopelvic cavity, which was approximately 55 cm wide. Laparoscopic right salpingo-oophorectomy was performed after the cyst was aspirated without spilling its contents into the peritoneal cavity. The patient's postoperative recovery was uneventful, and she was discharged on postoperative day 2.

Keywords: giant ovarian cyst, mucinous cystadenoma, laparoscopic salpingo-oophorectomy

Introduction

Ovarian cysts are a frequent cause of gynecologic consultations worldwide and affect women of all ages. Ovarian mucinous cystadenoma is a multilocular cyst of the ovary that arises from its epithelial surface [1]. They can become huge, occupy the entire abdominopelvic cavity, and cause progressive abdominal distension with nausea or vomiting, abdominal discomfort, or abdominal pain. Giant or huge ovarian cysts are not well defined in medical literature. However, some authors have defined ovarian cysts that are more than 10 cm in diameter as large ovarian cysts, and others have defined giant ovarian cysts as those that reach above the umbilicus as measured by computed tomography (CT) scan [2]. Currently, in high-income countries, they are usually diagnosed and treated early, at small or medium-sized stages. Mucinous ovarian tumors represent approximately 80% of all ovarian mucinous tumors, 10% are borderline, and 10% are malignant. Mucinous ovarian tumors are rare before puberty and after menopause [3]. The most dreaded complication of ovarian mucinous cystadenoma is rupture leading to pseudomyxoma peritonei. The surgical management of giant ovarian mucinous cystadenoma typically requires midline laparotomy to reduce the risk of cell spillage in malignant tumors [4]. Others have described the laparoscopic management of giant ovarian cysts occupying the entire abdominal cavity using different surgical techniques to limit the possible intraabdominal spillage of cyst content. The benefits of this laparoscopy procedure include reduced postoperative analgesic requirements, earlier mobilization, cosmetic advantages, and an earlier return to normal activity [5]. We report the case of a 64-year-old black African female patient who was admitted with a massive ovarian mucinous cystadenoma that was 55 cm in diameter, occupying the entire abdominopelvic cavity, and managed laparoscopically.

Corresponding Author

Aliou Zabeirou
Department of general and Visceral Surgery,
Hôpital Général de Référence; Niamey, Niger
E-mail: ali.zabeirou@gmail.com

Informed Consent

The authors stated that the written consent was obtained from the patient presented with images in the study.

Conflict of Interest

No conflict of interest was declared by the authors.

Financial Disclosure

The authors declared that this study has received no financial support.

Published
2026 April 16

Copyright © 2026 The Author(s)



This is an open-access article distributed under the terms of the Creative Commons Attribution-NonCommercial-NoDerivatives 4.0 International (CC BY-NC-ND 4.0).
<https://creativecommons.org/licenses/by-nc-nd/4.0/>



Case presentation

A 64-year-old multiparous black African female patient, gravida 7, parturition 6, with no medical or surgical history, presented to the surgical department of our hospital with a 2-year progressive abdominal distension. The patient also complained of constipation, nausea, postprandial vomiting, abdominal discomfort, and some vague abdominal pain. A general examination revealed a normal blood pressure of 120/70 mmHg, a heart rate of 68 beats/min, a respiratory rate of 18 breaths/min, and a temperature of 37 °C. Abdominal examination revealed a grossly distended and tense abdomen arising from the pelvis up to the epigastrium without generalized abdominal tenderness or shifting dullness (Figure 1). The remainder of the physical examination was unremarkable. A blood test was performed, and the hemoglobin rate was normal at 11.3 g/dl, the platelet count was 334,000 U/mm³, the WBC count was 8,000 U/mm³, the correct prothrombin level was 72%, and the CRP level was 18 mg/l. Tumor markers, including serum cancer antigen (CA) 125, carcinoembryonic antigen (CEA), cancer antigen 19.9 (CA19.9), and human epididymal protein 4 (HE4), were performed, showing normal results. The risk of malignancy algorithm (ROMA) value was 2.7. An enhanced computed tomography scan revealed a massive intraabdominal multilocular cystic mass occupying the entire abdominal cavity from the epigastrium to the pouch of Douglas and measuring approximately 55×42×34 cm. The surrounding fat planes appeared to be clean, with no evidence of ascites or lymphadenopathy (Figure 2). A diagnosis of a giant ovarian cyst was made. The patient was admitted to the operating room. The surgical procedure was performed in the supine position under general anesthesia. An open entry laparoscopy was performed 5 cm above the umbilicus to access the abdominal cavity and expose the cyst wall (Figure 3-A). A purse-string suture with a nonabsorbable suture was placed on the puncture site, and the cyst was punctured and aspirated (Figure 3-B). A total of 7100 ml of thick yellowish liquid was successfully aspirated. The purse-string suture was tightly closed. A 10-mm trocar was introduced into the open laparoscopy, and routine CO₂ insufflation was performed. Three additional 5-mm ports were inserted into the right and left flanks and the suprapubic midline area. Laparoscopic exploration revealed a huge cystic mass arising from the right ovary (Figure 3-D). The left ovary and uterus were normal. No ascites, peritoneal implants, or liver nodules were observed. A right salpingo-oophorectomy was performed using a bipolar grasper and laparoscopic scissor (Figure 3-D). The laparoscopic procedure proceeded uneventfully (Figure 3-A). The surgical specimen was extracted via open laparoscopy (Figure 4). No spillage or cyst perforation. The pelvic peritoneal fluid was sent for cytology. Histopathological examination of the surgical specimen revealed a mucinous cystadenoma of the ovary (Figure 5), and cytological examination of the pelvic peritoneal fluid revealed no neoplastic cells. The patient made an uneventful postoperative recovery with minimal oral analgesic use and was discharged on postoperative day 2.

Figure 1: Image showing the much distended abdomen of the patient, image taken on the operating table

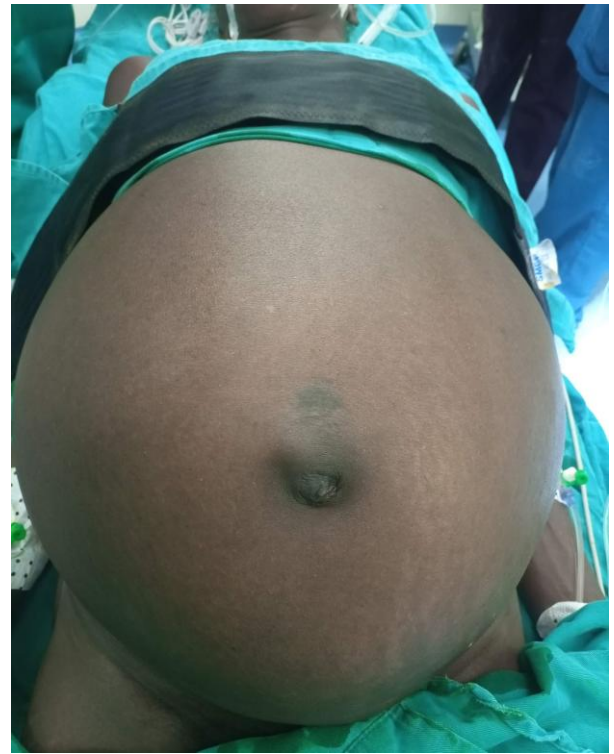

Figure 2: Abdominal CT scan showing a massive multilocular ovarian cyst occupying the entire abdominopelvic cavity. A: axial slice; B: sagittal slice

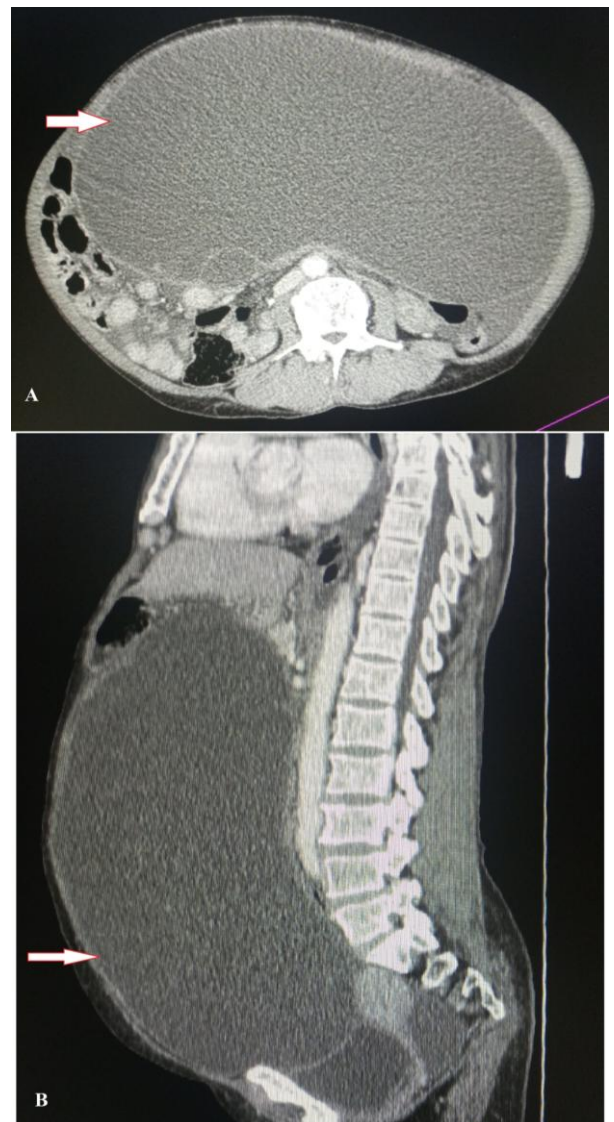

Figure 3: Figure summarizing the surgical procedure. **A:** open laparoscopy and exposure of the cyst wall, **B:** performance of a purse-string suture and puncture and aspiration of the contents of the cyst, **C:** Intraoperative view of the right ovary containing the completely collapsed cyst, **D:** salpingo-oophorectomy surgical specimen

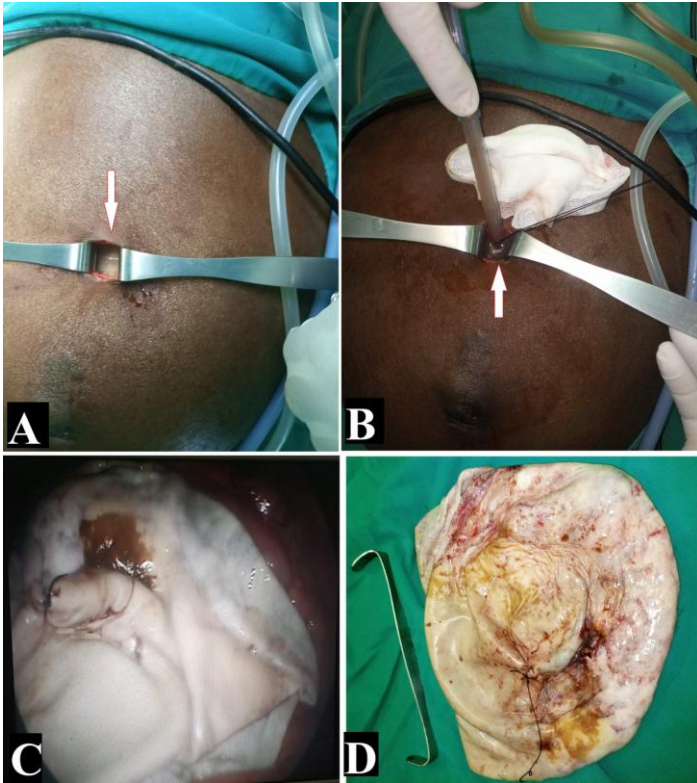


Figure 4: Immediate postoperative view of the patient's abdomen. **A:** Left side view, **B:** Front view, Black arrow: Open laparoscopy used for salpingo-oophorectomy, surgical specimen extraction

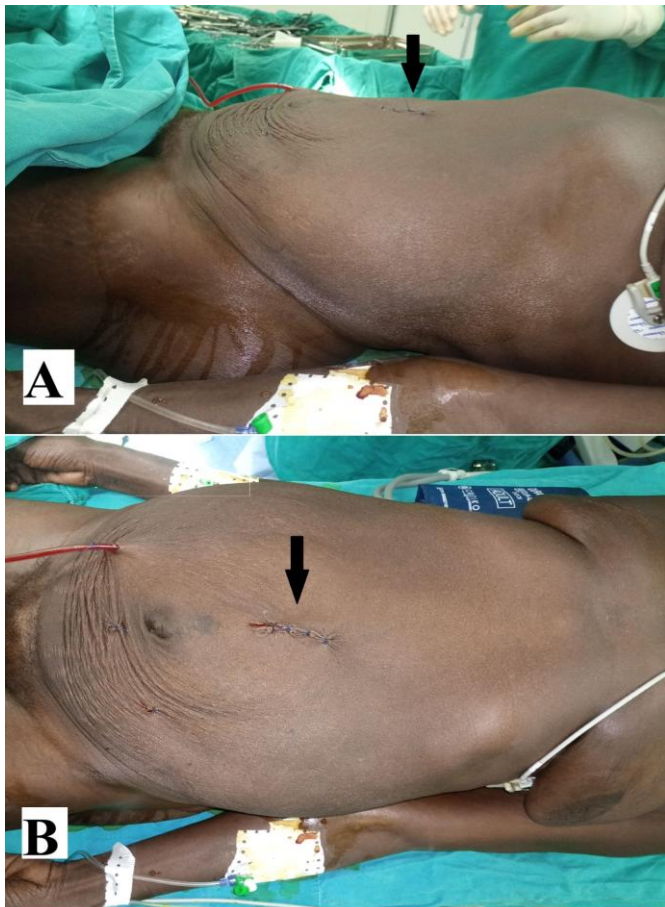
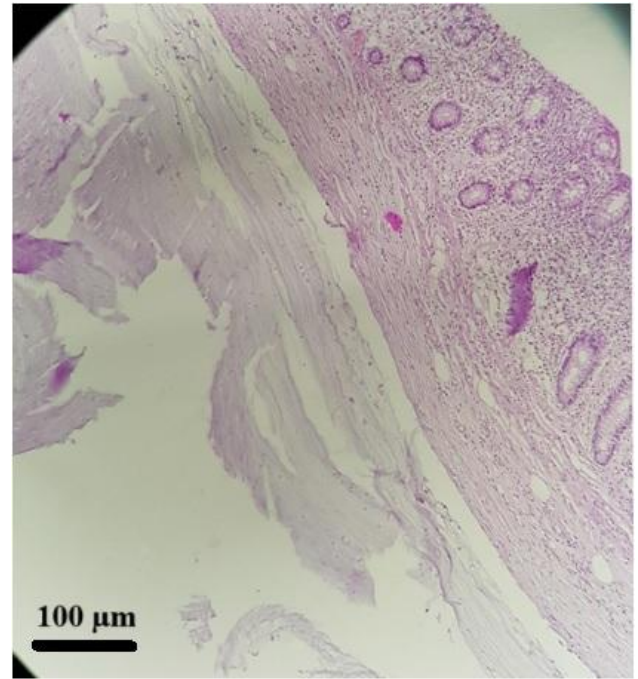


Figure 5: Microscopic image of the ovarian cyst showing a cyst wall lined by mucinous pseudostratified epithelium, with the presence of mucin within the cyst wall (hematoxylin and eosin [H&E] stain, original magnification $\times 200$. Scale bar = 100 μm).



Discussion

Mucinous cystadenoma accounts for approximately 80% of all mucinous tumors. Similar to our patient, benign mucinous cystadenomas can increase in size and become massive. However, giant ovarian cystadenoma of this size is rare. They usually occur as large, multiloculated masses containing mucus fluid, generally affecting women of reproductive age (aged 20–40 years) [6]. Currently, laparoscopic surgery is considered the gold standard for the management of small and moderate-sized ovarian cysts. Only a few authors have reported the laparoscopic management of giant benign mucinous cystadenoma of the ovary, and this represents a major improvement in this field. Many authors have considered laparoscopic management in this situation to be technically inappropriate because of the size of the cyst and to avoid any spillage of the cyst content in the peritoneal cavity [7]. They chose midline laparotomy as the standard surgical route for large ovarian cyst excision. However, minimally invasive surgery has many advantages, such as better magnification, reduced operative morbidity, reduced invasiveness, reduced hospitalization time, and reduced postoperative pain. In addition, giant ovarian cysts are commonly serous or mucinous. Therefore, some surgeons recommend laparoscopic management of huge ovarian cysts to provide patients with the benefits of laparoscopy. The selection of appropriate patients to minimize the risk of draining malignant masses is mandatory. Currently, the evidence of laparoscopic management of huge ovarian cysts is increasing. Laparoscopic surgery expertise is the only thing needed by the surgeon. However, only a few case series and case reports are available in the medical literature [5]. Dubuisson et al. reported a case of six patients with laparoscopically managed huge ovarian cysts. The Alexis laparoscopic system was used for the minimally invasive surgical extraction of large ovarian cysts. The median size of the cysts at imaging was 22.8 cm (range, 15–30 cm), whereas the median volume was 5.9 L (range, 1.9–15.6 L). The mean age of the operated women was 59 years (range, 21–88 years). The size of the skin incision initially performed to puncture the cyst ranged

from 2.5 to 4 cm. On final pathological reports, two cysts were mucinous cystadenoma and four were serous cystadenoma [8]. In a case report of a huge ovarian cyst, Rabbani et al. used a Veres needle to aspirate and drain the contents of the cyst and perform a cystectomy [9]. Alobaid et al. described a case series of 5 patients with huge ovarian cysts successfully managed by laparoscopy. An open-entry laparoscopic technique was used to avoid puncturing cysts before evaluating the intraoperative cyst. They proceeded to laparoscopic oophorectomy or cystectomy in the usual manner. The cyst was then removed using a suprapubic trocar after the incision was extended to 1.5 cm [10].

Conclusion

In low-income countries, socioeconomic factors are the main cause of late medical consultation, and diagnosis is made in the advanced stage of the disease. Nevertheless, laparoscopic management is possible and should be encouraged in the context of limited resources and should be encouraged. We hope that this case report will increase the use of laparoscopic techniques in the management of large ovarian cysts in low-income countries.

References

1. Gwanzura C, Muyotcha AF, Magwali T, Chirenje ZM, Madziyire MG. Giant mucinous cystadenoma: a case report. *J Med Case Rep.* 2019 Jun;13(1):181. doi: 10.1186/s13256-019-2102-z. PMID: 31196215; PMCID: PMC6567598.
2. Lee LC, Sheu BC, Chou LY, Huang SC, Chang DY, Chang WC. An easy new approach to the laparoscopic treatment of large adnexal cysts. *Minim Invasive Ther Allied Technol.* 2011 May;20(3):150-4. doi: 10.3109/13645706.2010.531543. Epub 2010 Nov 17. PMID: 21082898.
3. Hong JH, Choi JS, Lee JH, Son CE, Jeon SW, Bae JW. Laparoscopic management of large ovarian tumors: clinical tips for overcoming common concerns. *J Obstet Gynaecol Res.* 2012 Jan;38(1):9-15. doi: 10.1111/j.1447-0756.2011.01685.x. Epub 2011 Nov 9. PMID: 22070471.
4. Vizza E, Cutillo G, Patrizi L, Saltari M, Baiocco E, Corrado G. Use of SAND balloon catheter for laparoscopic management of extremely large ovarian cysts. *J Minim Invasive Gynecol.* 2011 Nov-Dec;18(6):779-84. doi: 10.1016/j.jmig.2011.06.019. Epub 2011 Jul 28. PMID: 21802377.
5. Ülker K, Hüseyinoğlu Ü, Kılıç N. Management of benign ovarian cysts by a novel, gasless, single-incision laparoscopic technique: keyless abdominal rope-lifting surgery (KARS). *Surg Endosc.* 2013 Jan;27(1):189-98. doi: 10.1007/s00464-012-2419-9. Epub 2012 Jun 26. PMID: 22733196.
6. Jeong EH, Kim HS, Ahn CS, Roh JS. Successful laparoscopic removal of huge ovarian cysts. *J Am Assoc Gynecol Laparosc.* 1997 Nov;4(5):609-14. doi: 10.1016/s1074-3804(05)80098-2. PMID: 9348371.
7. Song MJ, Lee SJ, Yoo SH, Seo YH, Yoon JH. Single port gasless laparoscopy-assisted mini-laparotomic ovarian resection (SP-GLAMOR): reasonable treatment for large cystic ovarian tumors with suspicion of malignancy. *Gynecol Oncol.* 2014 Jan;132(1):119-24. doi: 10.1016/j.ygyno.2013.10.005. Epub 2013 Oct 11. PMID: 24125748.
8. Dubuisson J, Heersche S, Petignat P, Undurraga M. Laparoscopic Management of Giant Ovarian Cysts Using the Alexis Laparoscopic System®: A Case Series. *Front Surg.* 2020 May;6(7):24. doi: 10.3389/fsurg.2020.00024. PMID: 32435653; PMCID: PMC7218052.
9. Rabbani I, Wynn JS, Hickling DJ. Laparoscopic excision of a large ovarian cyst. *Gynecol Surg.* 2007;4(1):225-7. doi: 10.1007/s10397-007-0277-6
10. Alobaid A, Memon A, Alobaid S, Aldakhil L. Laparoscopic management of huge ovarian cysts. *Obstet Gynecol Int.* 2013 May;8(2013):380854. doi: 10.1155/2013/380854. Epub 2013. PMID: 23766763; PMCID: PMC3665257.

Disclaimer/Publisher's Note: The statements, opinions, and data presented in publications in the *Journal of Surgery and Medicine (JOSAM)* are exclusively those of the individual author(s) and contributor(s) and do not necessarily reflect the views of JOSAM, the publisher, or the editor(s). JOSAM, the publisher, and the editor(s) disclaim any liability for any harm to individuals or damage to property that may arise from implementing any ideas, methods, instructions, or products referenced within the content. Authors are responsible for all content in their article(s), including the accuracy of facts, statements, and citations. Authors are responsible for obtaining permission from the previous publisher or copyright holder if re-using any part of a paper (e.g., figures) published elsewhere. The publisher, editors, and their respective employees are not responsible or liable for the use of any potentially inaccurate or misleading data, opinions, or information contained within the articles on the journal's website.