

Outcomes of osteoporotic intertrochanteric fractures treated with cement-augmented proximal femoral nail

Firat Fidan, Osman Lapcin

Istanbul Aydın University Medicine School,
Department of Orthopedic and Traumatology,
Istanbul, Turkey

ORCID ID of the author(s)

FF: 0000-0003-3490-7340
OL: 0000-0001-6950-3691

Corresponding Author

Firat Fidan
Istanbul Aydın University Medicine School,
Department of Orthopedic and Traumatology,
Istanbul, Turkey
E-mail: drfiratfidan@gmail.com

Ethics Committee Approval

The study was approved by Istanbul Aydın University Clinical Researches Ethics Committee (approval number:2022-050.06.04/132).

All procedures in this study involving human participants were performed in accordance with the 1964 Helsinki Declaration and its later amendments.

Conflict of Interest

No conflict of interest was declared by the authors.

Financial Disclosure

The authors declared that this study has received no financial support.

Published

2022 October 17

Copyright © 2022 The Author(s)

Published by JOSAM

This is an open access article distributed under the terms of the Creative Commons Attribution-NonCommercial-NoDerivatives License 4.0 (CC BY-NC-ND 4.0) where it is permissible to download, share, remix, transform, and build upon the work provided it is properly cited. The work cannot be used commercially without permission from the journal.



Abstract

Background/Aim: Implant failure due to poor bone quality in osteoporotic intertrochanteric fractures increases mortality and morbidity, leading to secondary surgery and complications in patients. Our study aims to evaluate the early functional and radiologic outcomes and complications of osteoporotic intertrochanteric fractures using a cement-augmented proximal femoral nail design.

Methods: This case series included 24 patients AO (Arbeitsgemeinschaft für Osteosynthesefragen type 31-A2.2 in 10 patients, A2.3 in 7 patients, 31-A3.1 in 4 patients, and A3.2 in 3 patients). Proximal femoral nail cement augmentation was invariably accomplished by injecting polymethylmethacrylate (PMMA) cement into the femoral head. The clinical outcome was rated using the Harris Hip Score (HSS) at the time of the final follow-up. The results were recorded as excellent (score >90), decent (score 89–70), and poor (score 70–0). Radiographs were reviewed for implant failure and union. Implant failure was defined as lag screw cut-out or perforation.

Results: The average age of our sample was 73.8 (6.9) years, And the mean follow-up time was 13.6 months. In all patients, union was accomplished. Implant failure and cut-out were not observed in any of the patients. The average Harris score at the final follow-up was 80.6. According to the HSS, four patients had excellent, 15 had good, and 5 had poor functional results.

Conclusion: Cement-augmented femoral nails can be used safely with a low complication rate in osteoporotic intertrochanteric femur fractures. In future studies, controlled studies should be conducted for this nail design.

Keywords: Cement augmented proximal femoral nail, Osteoporosis, Trochanteric

Introduction

Intertrochanteric fractures are common orthopedic injuries, most of which occur in elderly patients [1-3]. As the population ages and severe osteoporosis becomes more prevalent, the incidence of intertrochanteric fractures is expected to increase further [2-3]. The surgical treatment of intertrochanteric fractures aims to achieve early mobilization and restore functional capacity [1]. Management of this common injury is often challenging and controversial [1, 4]. Proximal femoral nail (PFN) fixation has long been considered an option for intertrochanteric fractures [4, 5]. Although PFN may be an attractive treatment method for unstable fractures in elderly patients, fixation with a nail in this age group is prone to complications due to osteoporosis, such as failure of fracture fixation and screw cut-out [4-7]. Poor bone quality results in insufficient mechanical stability [7]. Bone cement augmentation procedures effectively treat osteoporotic intertrochanteric fractures [8-9]. Cement-augmented fixation devices, including dynamic hip screw and on a nail have been used as a solution in unstable intertrochanteric fractures.

Our study uses a cement-augmented proximal femoral nail (PFN) design to assess the early functional, radiologic, and complication outcomes in osteoporotic trochanteric fractures.

Materials and methods

The study was approved by the Istanbul Aydın University Clinical Research Ethics Committee (approval number: 2022-050.06.04/132) and adhered to the principles of the Declaration of Helsinki. Patients treated between September 2020 and December 2021 with cement-augmented PFNs due to intertrochanteric fracture were retrospectively analyzed. Patients under 65 years of age, patients with pathological fractures associated with lower limb fractures, and those without a follow-up for at least 6 months were excluded from the study. The osteoporosis severity of the patients included in the study was determined according to the Singh Index [10]. The Singh Index grades 1, 2, and 3 were included in the sample. The hip fracture types of the patients included in the study were determined according to the AO/OTA classification system. In addition, the database collected the age, gender, operation time, and intraoperative complications.

Surgical procedure

We used epidural, spinal, or general anesthesia during the surgical procedures. Following successful anesthesia, patients were placed on an orthopedic fracture table in the lateral decubitus position. Typically, internal rotation and longitudinal traction were initially used to attempt closed reduction. In patients who were unable to undergo a closed reduction, a mini-open incision and hook were used to reduce the fracture. A small longitudinal incision was made 5 cm proximal to the greater trochanter. The gluteal fascia was incised, and the gluteus medius was bluntly split longitudinally and reached the tip of the trochanter. The appropriate entry site of the nail was determined with the aid of fluoroscopy, and the guide wire was advanced from the trochanter type to the medulla. A cannulated drill was inserted to prepare the entry of the nail (Tasarım Medical, Istanbul, Turkey) (Figure 1). After the drilled proximal femur,

the nail (130° and 200 mm) was inserted into the femur. With controlling fluoroscopy, lag screw guides were placed as close to the calcar on the anteroposterior radiograph as central on the lateral radiographs. After the appropriate location was determined, the measurement was recorded, and the lag screw was inserted. Afterwards, the fixation was strengthened with an anti-rotation screw, and compression was performed when necessary. The nail was statically locked from the distal with one screw. Polymethylmethacrylate (PMMA) bone cement was mixed and placed in a specialized cement gun (Figure 2). The cement gun contains threads that can adapt to the lag screw, which was inserted into the screw (Figure 3). The cement was injected into the femoral head under fluoroscopy control (Figure 4). After injection, the cement gun was removed, and the hole of the lag screw was closed with a screw. Postoperatively, the patients received standard prophylaxis for deep vein thrombosis. Patients were mobilized with weight bearing, as tolerated.

Figure 1: Design of cemented proximal nail. The white arrow indicates the holes at the tip of the lag screw.

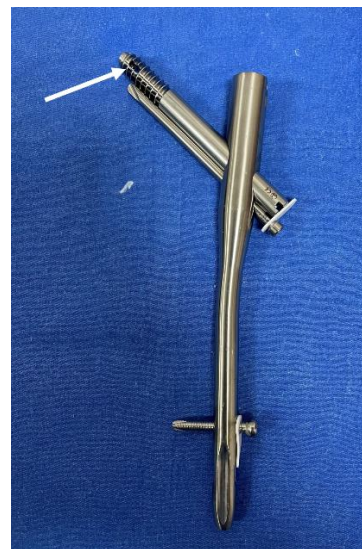

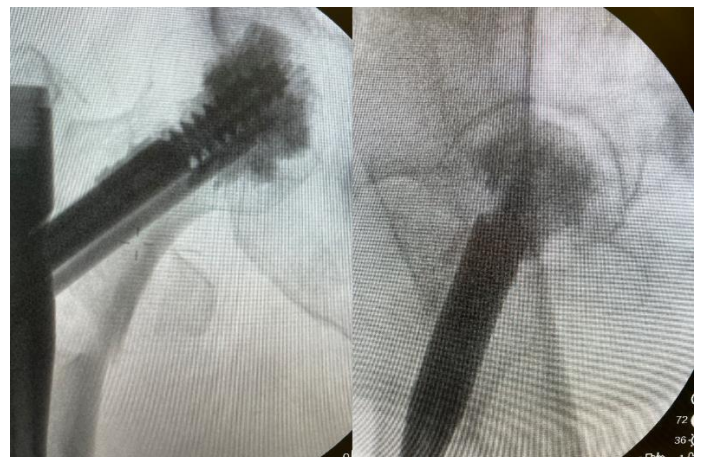Figure 2: Cement gun and the chamber in which the cement is placed.




Figure 3: Connection of cement gun with lag screw on nail.



Figure 4: Monitoring cement application with fluoroscopy.



Radiologic and clinical evaluation

Immediate postoperative radiographs were reviewed to reduction quality and to determine intra-articular leakage of cement. The postoperative reduction quality of the patients was determined as good, acceptable, or poor according to the reduction criteria defined by Baumgaertner et al. [11]. During follow-up, radiographs were reviewed for implant failure and union. Implant failure was defined as lag screw cut-out or perforation.

At the final follow-up, the functional level was estimated using the Harris Hip Score (HSS; <70 = poor, 70–89 = fair/good, and >90 = excellent) [12] and the visual analog scale (VAS) score [13].

Statistical analysis

SPSS version 23.0 program was used to perform statistical analyses (IBM Corp., Armonk, NY). For continuous variables, descriptive data were reported as mean (standard deviation), or median (min–max), and as number and frequency for categorical variables. The categorical variables were also compared using the chi-square test.

Results

A cemented augmented PFN was used as a surgical intervention for 34 intertrochanteric fractures. One patient died due to COVID-19 infection on postoperative day 12; 2 patients died due to pulmonary complications at 1 month postoperation; and 1 patient died due to cardiac failure in the third postoperative month. Of the remaining patients, 24 who had at least 6 months of follow-up were included in the study. Fourteen of these patients were female and 11 were male, with a mean (standard deviation) age of 73.8 (6.9) years. The mean follow-up period duration was 13.6 months. The mean time between surgery and admission was 2.3 (1.2) days.

The mean surgical time was 45.5 (12.4) minutes. According to the AO classification; 10 patients had AO 31-A 2.2, 7 had AO 31-A 2.3, 4 had AO31-A3.1, and 3 had AO 31-A3.2 type fractures. According to the Singh Index, the degree of osteoporosis was classified as stage 3 in 11 patients, as stage 2 in 9 patients, and as stage 1 in 4 patients (Table 1).

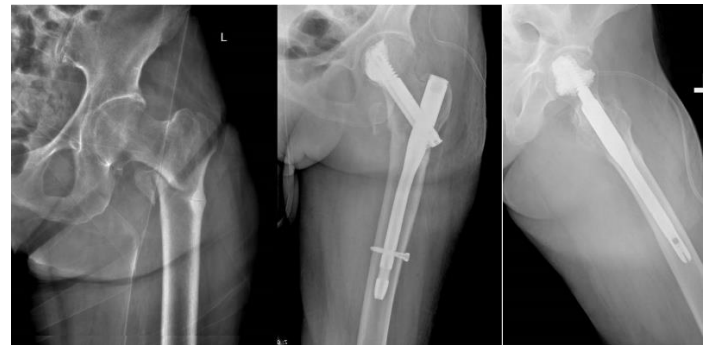
In the intraoperative evaluation, the mean blood loss was determined as 320.4 cc. Intraoperative erythrocyte suspension transfusion was applied to 8 patients. No complications developed in any of the patients during cement injection.

Early postoperative radiographs revealed an excellent reduction of intertrochanteric fracture in 15 patients and a good reduction in 9 patients. Cement leakage was observed in the joint in 1 patient (Figure 5). The average HSS at the final follow-up was 80.6. According to the HHS, 4 patients had excellent, 15 had good, and 5 had poor functional results. The mean VAS was found to be 2.3. In the final radiologic control, no patient had a screw cut out, perforation, or implant failure. Union was achieved in all patients (Figure 6).

Figure 5: Cement leakage in the joint following cement application.

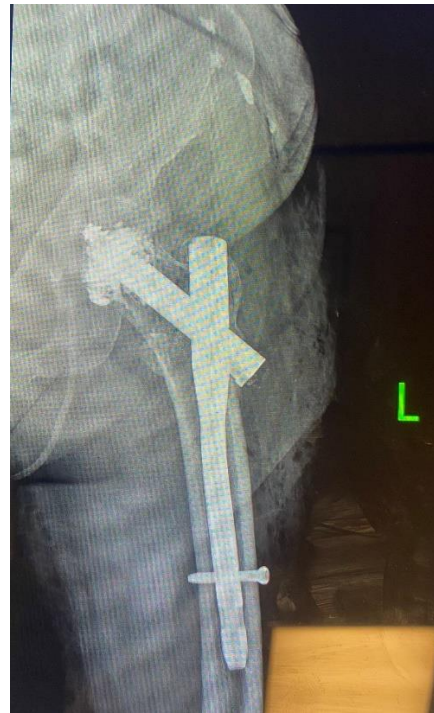

Figure 6: Pre- and postoperative radiologic images of a 69-year-old female patient.



Discussion

Insufficient fixation strength due to poor bone quality in osteoporotic intertrochanteric fractures remains the leading cause of implant failure [1]. The radiologic and clinical results of high-grade osteoporotic patients with intertrochanteric fractures treated with a novel cement-augmented PFN were the subject of this study. Our results indicate that cement-augmented PFNs can be a valuable option to prevent failure in osteoporotic intertrochanteric fracture.

Surgery to treat osteoporotic and unstable intertrochanteric fractures remains problematic in orthopedic practice [4]. Due to their biomechanical benefits, intramedullary implants are frequently utilized to treat unstable pertrochanteric fractures [2, 5, 14]. Although adequate stabilization is obtained with intramedullary nailing, implant failure, cut-out, and screw penetration are significant complications in osteoporotic patients [7, 14]. Poor bone quality is one of the major causes of mechanical complications [14–16]. Reduction in the mechanical properties of the bone due to osteoporosis predisposes fracture failure [2]. In patients with an osteoporotic bone, achieving adequate strength of the bone–implant construct may not be feasible [7, 17]. To address this problem, cement-augmented nails have become increasingly popular in recent years. In a recent prospective trial, Kammerlander et al. [18] evaluated patients with closed unstable intertrochanteric fractures treated

by proximal femoral nail anti-rotation (PFNA) with and without cement augmentation, finding that non-augmented PFNA may have the potential to prevent re-operations by strengthening the osteosynthesis construct. A biomechanical cadaver study confirmed that cement augmentation with PFNA has higher implant stability than the non-augmented group [19]. Another biomechanical study discovered that femoral heads that had been supplemented showed greater rotational stability and pull-out resistance than femoral heads that had not been augmented [20]. Implant failure and cut-out were not observed in any of the patients in our cohort group, which supports the proposition that cement augmentation increases implant stability in osteoporotic intertrochanteric fractures.

Some complications in cement augmentation may include bone cement implantation syndrome and cement leakage [21-23]. Bone cement implantation syndrome is a deadly complication of orthopedic procedures involving bone cement, and it is characterized by hypoxia, hypotension, cardiac arrhythmias, and cardiac arrest [21].

No patients in our study had a 20% reduction in blood pressure perioperatively, and none had SpO₂ <88. Anesthesia teams are cautioned to apply anesthetics slowly and with low pressure, to prevent bone cement implantation syndrome before cement injection. A cement leak occurred in 1 patient in the study; however, no complications were observed in this patient in the follow-up period. Care should be taken not to perforate the femoral head of the guide wire of the lag screw in order to prevent cement leakage. During cement injection, it should be ensured that sufficient cement has reached the femoral head using anterior, posterior, and lateral fluoroscopy images.

Limitations

This study has some limitations. Firstly, the sample size of the experimental group was relatively small. Secondly, the follow-up period was relatively brief. Thirdly, a comparison group was absent. Thus, future studies are encouraged to use larger sample sizes and longer follow-ups.

Conclusion

This study demonstrated that this PFN design, which offers cement augmentation, is likely to provide mechanical advantages and reduce implant failure. It can be a valuable option for treating osteoporotic intertrochanteric fractures with a low complication rate.

References

1. Stramazzo L, Ratano S, Monachino F, Pavan D, Rovere G, Camarda L. Cement augmentation for trochanteric fracture in elderly: a systematic review. *Journal of Clinical Orthopaedics and Trauma*. 2020 Oct 20;15:65-70.
2. Sandmann G, Biberthaler P. Pertrochanteric femoral fractures in the elderly. *Unfallchirurg*. 2015 May;118(5):447-60.
3. Azagra R, López-Expósito F, Martín-Sánchez JC, Aguyé A, Moreno, Cooper C, et al. Changing trends in the epidemiology of hip fracture in Spain. *Osteoporos Int*. 2014 Apr;25(4):1267-74.
4. Lenich A, Vester H, Nerlich M, Mayr E, Stöckle U, Füchtmeier B. Clinical comparison of the second and third generation of intramedullary devices for trochanteric fractures of the hip-blade vs screw. *Injury*. 2010 Dec;41(12):1292-6.
5. Russel TA. Rockwood and Green's fractures in adults. Philadelphia: Wolters Kluwer Health; 2015. Intertrochanteric fractures of the hip. pp. 2075-129. In: Court-Brown CM, Heckman JD, McQueen MM, Ricci WM, Tornetta III Paul, McKee MD, editors
6. Andruszkow H, Frink M, Frömke C, Matiyahu A, Zeckey C, Mommsen P. Tip Apex Distance, Hip Screw Placement, and Neck Shaft Angle as Potential Risk Factors for Cut-Out Failure of Hip Screws After Surgical Treatment of Intertrochanteric Fractures. *Int Orthop*. 2012 Nov;36(11):2347-54.
7. Kashigar A, Vincent A, Gunton MJ, Backstein D, Safir O, Kuzyk PR. Predictors of failure for cephalomedullary nailing of proximal femoral fractures. *Bone Jt J*. 2014 Aug;96-B(8):1029-34.
8. Gupta RK, Gupta V, Gupta N. Outcomes of osteoporotic trochanteric fractures treated with cement-augmented dynamic hip screw. *Indian J Orthop*. 2012 Nov;46(6):640-5.
9. Dall'Oca C, Maluta T, Moscola A, Lavini F, Bartolozzi P. Cement augmentation of intertrochanteric fractures stabilised with intramedullary nailing. *Injury*. 2010 Nov;41(11):1150-5.
10. Singh M, Nagrath AR, Maini PS. Changes in trabecular pattern in the upper end of the femur as an index of osteoporosis. *J Bone Joint Surg Am*. 1970 Apr;52(3):457-67.

11. Baumgaertner M, Curtin S, Lindskog D, Keggi J. The value of the tip-apex distance in predicting failure of fixation of pertrochanteric fractures of the hip. *J Bone Joint Surg*. 1995 Jul;77(7):1058-64.
12. Banaszkiwicz, Paul A. "Traumatic arthritis of the hip after dislocation and acetabular fractures: treatment by mold arthroplasty: an end-result study using a new method of result evaluation." *Classic papers in orthopaedics*. Springer, London, 2014. 13-17.
13. Jensen MP, Chen C, Brugger AM. Interpretation of visual analog scale ratings and change scores: a reanalysis of two clinical trials of postoperative pain. *J Pain*. 2003 Sep;4(7):407-14.
14. Gazotti, Gabriele Matino G, Tsatsis C, Sacchetti G, Baudi P, Catani F. Causes and treatments of lag screw's cut out after intramedullary nailing osteosynthesis for trochanteric fractures. *Acta Bio-Medica: Atenei Parmensis*, 2014 Aug 20;85(2):135-43.
15. Bojan A, Beimel C, Taglang G, Collin D, Ekholm C, Jönsson A. Critical factors in cut-out complication after Gamma Nail treatment of proximal femoral fractures. *BMC Musculoskeletal Disorders*. 2013 Jan 2;14:1.
16. Bonnaire F, Weber A, Bösl O, Eckhardt C, Schwieger K, Linke B. "Cutting out" in pertrochanteric fractures—problem of osteoporosis? *Unfallchirurg*. 2007 May;110(5):425-32.
17. Larsson Sune. Cement augmentation in fracture treatment. *Scandinavian Journal of Surgery*. 2006 May;95(2):111-8.
18. Kammerlander C, Hem ES, Klopfer T, Gebhard F, Sermon A, Dietrich M, et al. Cement augmentation of the Proximal Femoral Nail Antirotation (PFNA)—A multicentre randomized controlled trial. *Injury*. 2018 Aug;49(8):1436-44.
19. Fensky F, Nüchtern JV, Kolb JP, Huber S, Rupprecht M, Jauch SY, et al. Cement augmentation of the proximal femoral nail antirotation for the treatment of osteoporotic pertrochanteric fractures a biomechanical cadaver study. *Injury*. 2013 Jun;44(6):802-7.
20. Erhart S, Schmoelz W, Blauth M, Lenich A. Biomechanical effect of bone cement augmentation on rotational stability and pull-out strength of the Proximal Femur Nail Antirotation. *Injury*. 2011 Nov;42(11):1322-7.
21. Donaldson AJ, Thomson HE, Harper NJ, Kenny NW. Bone cement implantation syndrome. *British Journal of Anaesthesia*. 2009 Jan;102(1):12-22.
22. Schuetze K, Ehinger S, Eickhoff A, Dehner C, Gebhard F, Richter PH. Cement augmentation of the proximal femur nail antirotation: is it safe? *Archives of Orthopaedic and Trauma Surgery*. 2021 May;141(5):803-11.
23. Wu MH, Lee PC, Peng KT, Wu CC, Huang TJ, Hsu R WW. Complications of cement-augmented dynamic hip screws in unstable type intertrochanteric fractures—a case series study. *Chang Gung Med J*. 2012 July;3(4):345-53.

The National Library of Medicine (NLM) citation style guide has been used in this paper.