

Does sodium phosphate enema use cause electrolyte disorder?

Songül Tomar Güneysu ¹, Okşan Derinöz Güleriyüz ¹, Nazmi Mutlu Karakaş ², Özlem Çolak ¹

¹ Gazi University Faculty of Medicine,
Department of Pediatrics, Division of Pediatric
Emergency, Ankara, Turkey

² Gazi University Faculty of Medicine,
Department of Pediatrics, Ankara, Turkey

ORCID  of the author(s)

STG: <https://orcid.org/0000-0003-0573-978X>
ODG: <https://orcid.org/0000-0001-7348-0656>
NMK: <https://orcid.org/0000-0003-4286-7086>
ÖÇ: <https://orcid.org/0000-0001-7939-8506>

Abstract

Constipation is one of the most common symptoms in childhood. Sodium-phosphate enemas are frequently preferred for the treatment of constipation and bowel cleansing. We present a case of a 5-year-old boy who presented to the Pediatric Emergency Department with complaints of constipation, abdominal pain, abdominal distension and vomiting; had been constipated for about two years and had poor nutrition, and received a full dose of CT enema® twice in the last 12 hours before admission to the hospital. Upon arrival at the Pediatric Emergency Department, the patient was given a pediatric fleet enema because he had dense stools according to radiographic evidence. Poisoning due to Sodium-phosphate enema was considered due to severe hyperphosphatemia and hypocalcemia in the laboratory evaluation. Rapid intravenous hydration and 1 mL/kg calcium gluconate intravenous infusion were started. Electrolytes returned to the normal range at the 14th hour of follow-up without the need for additional treatment. This case is presented to emphasize that due to the widespread use of sodium-phosphate enemas in the treatment of chronic constipation, these enemas can cause phosphate poisoning even when used in healthy patients at therapeutic doses.

Keywords: sodium-phosphate enema, hyperphosphatemia, hypocalcemia, constipation

Introduction

Constipation is a common symptom that occurs in more than 10% of children. In chronic constipation, gastrointestinal, endocrine, neurological, and metabolic system abnormalities are primarily investigated. When no cause is found, the patient is diagnosed with functional constipation [1].

Sodium-phosphate (Na-P) enemas are frequently used in the treatment of chronic constipation and fecaloma in primary care, with hospitalized children, and in emergency departments due to their small volume, effectiveness in relieving constipation, ease of use, and safety [2–3]. Poisoning is rare after rectally administered hypertonic phosphate solutions in healthy children [4]. Phosphate enema poisoning causes electrolyte disturbances, and hyperphosphatemia is the most common [5].

This case is presented to emphasize that due to the widespread use of Na-P enemas in the treatment of chronic constipation, these enemas can cause phosphate poisoning, even when used in healthy patients at therapeutic doses.

Corresponding Author

Songül Tomar Güneysu

Division of Pediatric Emergency, Department of
Pediatrics, Gazi University Faculty of Medicine,
Ankara, Turkey

E-mail: tomarsongul@gmail.com

Informed Consent

The authors stated that the written consent was
obtained from the parents of the patient presented
with images in the study.

Conflict of Interest

No conflict of interest was declared by the
authors.

Financial Disclosure

The authors declared that this study has received
no financial support.

Published

2024 March 16

Copyright © 2024 The Author(s)



This is an open-access article distributed under the terms of the
Creative Commons Attribution-NonCommercial-NoDerivatives
4.0 International (CC BY-NC-ND 4.0).

<https://creativecommons.org/licenses/by-nc-nd/4.0/>



Case presentation

A five-year-old male patient was admitted to the pediatric emergency department with complaints of constipation, abdominal pain, abdominal distension, and vomiting. The patient, who did not have stool for about 15 days, also had widespread abdominal pain and vomiting seven times, including what he ate. From his history, it was learned that he had constipation for two years, irregularly used oral laxatives, and had poor nutrition. The family often induces defecation through enema.

He was a child with normal neurological development. It was learned from his family history that he had second-degree parental consanguinity. His mother had 10 pregnancies, three of which died in the intrauterine period, and three died at the age of one due to spinal muscular atrophy (SMA). Two of the other children were healthy, and one had a history of operation due to vesicourethral reflux.

At the initial evaluation, body temperature was 36°C, pulse rate was 96/min, respiratory rate was 24/min, blood pressure was 100/60 mmHg, and oxygen saturation was 96%. On physical examination, the general appearance was good, and there was no sign of dehydration. In his gastrointestinal examination, the abdomen was distended, and there was no tenderness, defense, rebound, or palpable mass. There was a small amount of stool output during the rectal examination. Other system examinations were normal. His body weight was 10th percentile (16 kilograms), and his height was in the 10–25 percentile (105 centimeters).

In the standing direct abdominal X-ray, there was a dense stool appearance and dilated bowel loops (Figure 1). The pediatric surgery department was consulted because of abdominal distention, lack of stool output, and preliminary diagnosis of intestinal pseudo-obstruction, anorectal malformations, and Hirschsprung's disease. A Fleet pediatric enema® was applied to the patient who was recommended to have an enema, and there was copious stool output after 10 minutes. There was an increase in the appearance of dense stool and dilated bowel loops in the standing straight abdominal X-ray taken after the enema was applied, and no distal transition was observed (Figure 2). Abdominal ultrasonography revealed a "globe vesical, rectum wall thickness of 6 mm".

In laboratory examination, blood gas was normal, blood glucose 102 mg/dL, calcium 6.4 mg/dL (8.8-10.8), ionized calcium 0.69, phosphorus 18.9 mg/dL (4–7), and magnesium was in the normal range. The laboratory results and history of the patient were re-evaluated, and it was learned that a full dose of CT enema® was administered twice in the last 12 hours in an external center. The patient was diagnosed with hyperphosphatemia and hypocalcemia due to Na-P enemas based on his history, physical examination, and laboratory results. Half saline intravenous (IV) hydration at 3000 mL/m²/day was started, and 1 mL/kg calcium gluconate IV infusion was given. Phosphorus level at the second hour of hydration was 11.3 mg/dL, at 6 hours 7.2 mg/dL, normal limits at the 14th hour.

Electrocardiogram (ECG) follow-ups were always normal. The patient, who did not need intensive care, was admitted to the pediatrics service and followed up to regulate the etiology and treatment of constipation.

Figure 1: Standing Abdominal X-ray taken in the emergency service

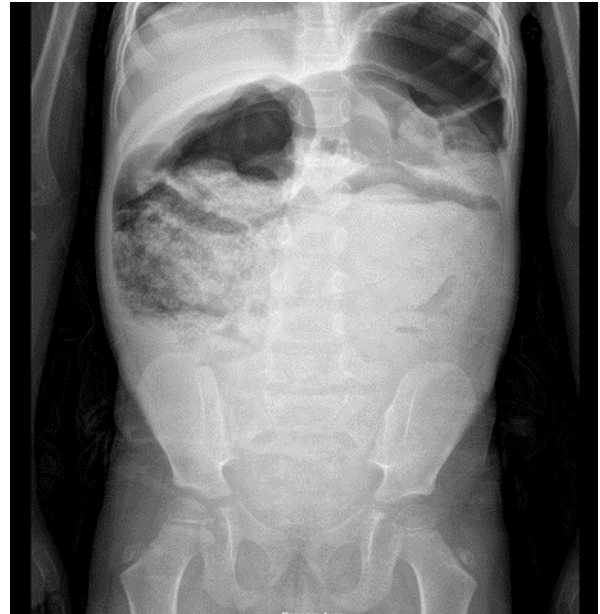
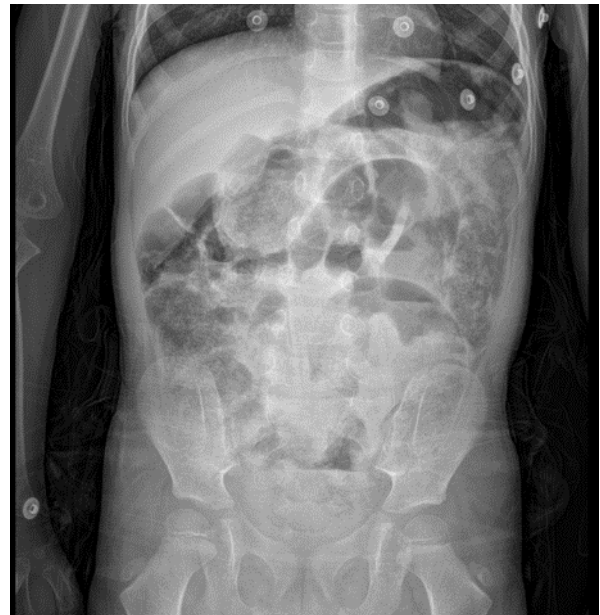

Figure 2: Standing Abdominal X-ray taken following the administration of the enema



In the examinations for the etiology of constipation, there were no atypical cells in the peripheral smear; creatine kinase (CK), lactate dehydrogenase (LDH), uric acid, and bilirubin values were within normal limits. Thyroid function tests and thyroid ultrasonography, vitamin D and parathormone, urinalysis, and metabolic tests were normal.

Abdominal computed tomography for possible abscess, malignancy, and mass exclusion noted the following: "Rectum, sigmoid colon, more prominent in the transverse colon, diffuse diameter increase in the colon, in the lumen in the distal part of the rectum, with an enlarged appearance secondary to feces and gas content, in the thickest part of the rectum wall on the left lateral A wall thickness increase of 8 mm (secondary to constipation)". SMA gene analysis was sent due to sibling history, and it was normal.

No significant disease was found in etiology, and functional constipation was considered. The patient was started regularly on lactulose as a treatment for constipation. In hospital follow-up, it was observed that the patient did not have toilet habits, and with pelvic floor muscle group exercises and toilet training, defecation occurred spontaneously many times. He was

discharged without sequelae on the fifth day with oral lactulose treatment. Table 1 summarizes the patient's laboratory follow-up chart.

Table 1: Laboratory follow-up chart

	Reference values	0 th hour	5 th hour	9 th hour	14 th hour	Discharge
Sodium (mmol/L)	135-145	145	142	140	137	139
Potassium (mmol/L)	3.5-5.5	3.2	3.1	3.4	3.6	4.1
Phosphorus (mg/dL)	4-7	18.9	11.3	7.2	6	4.2
Calcium (mg/dL)	8.8-10.8	6.4	9.3	8.4	8.7	9.5
Ionized calcium (mmol/L)	1.1-1.3	0.69			0.91	
pH	7.35-7.45	7.39			7.49	
Magnesium (mg/dL)	1.8-2.6	3.2			2.4	1.9

Verbal informed consent was obtained from the family of the patient participating in the study.

Discussion

The occurrence of hyperphosphatemia due to Na-P enema ingestion, which presents with different results, ranging from complete recovery to severe neurological deficits, has been included in the literature, with many case reports over 45 years. In one study, a case series of children who developed severe hyperphosphatemia after administration of Na-P containing laxatives between 1968 and 2010 was presented, and a systematic review of the literature was made. In that study, 28 publications with a mean age of 2.83 years (8 days–17 years) were examined. When the indications for administration were evaluated, it was reported that 26 cases were due to acute or chronic constipation, and 21 patients were administered rectally as the route of administration. Considering the underlying diseases, four patients had Hirschsprung's disease, four patients had a congenital anorectal malformation, three patients had chronic constipation, one patient had gastroschisis, one patient had Crohn's disease, and nine patients had systemic diseases, such as urological pathology and congenital syndromes. Ten patients were previously reported to be healthy [5]. While our patient was being evaluated with chronic constipation and abdominal distension, electrolyte disturbance was detected, the history was questioned again and it was learned that multiple rectal enemas were performed.

The most common cause of hyperphosphatemia is renal failure. Because the cellular content of phosphorus is higher than that of plasma phosphorus, it can release significant amounts of phosphorus in cell lysis. This explains the etiology and pathophysiology of hyperphosphatemia in tumor lysis syndrome (TLS), rhabdomyolysis and acute hemolysis. Diabetic ketoacidosis, vitamin D poisoning, hypoparathyroidism, hyperthyroidism and excessive cow's milk intake in infants are involved in the etiology of hyperphosphatemia [6]. Our case did not have a history of chronic disease that could cause elevated phosphorus. Renal function tests, CK, LDH, uric acid and bilirubin values were within normal limits. Thyroid function tests and thyroid ultrasonography, vitamin D and parathormone, as well as urine and metabolic tests were normal. There were only three enemas in the last 12 hours, which could explain the etiology.

Constipation is a common problem in childhood. Although its prevalence is 10%, it constitutes 3% of general pediatric consultations and 25% of gastroenterology consultations. One out of every three children with functional constipation experiences an attack of fecaloma. Although there are other options such as oral or enteral osmotic laxatives, osmotic

enemas, lubricants and glycerin suppositories for their cleaning, Na-P enemas are commonly used in emergency departments [3]. We also use pediatric fleet enema® or Na-P enemas in our pediatric emergency clinic.

Sodium-phosphate enemas are widely used for constipation because they are hyperosmolar and are considered safe [1]. Hypertonicity causes a large movement of fluid into the intestinal lumen and the formation of a third space that allows evacuation of rectosigmoid fecal contents. Dehydration due to high osmolar effect and hypocalcemia secondary to high phosphorus absorption occur as a result of errors in dosing, administration and elimination of the enema. Phosphorus is often absorbed in the duodenum and jejunum, but it is important to note that colonic absorption may also occur at high concentrations in the rectum. The rapid increase in phosphorus can lead to calcium chelation and precipitation of calcium phosphate salts in soft tissues and kidneys, which causes acute hypocalcemia. Excess phosphorus as inorganic acid and loss of bicarbonate in the intestinal lumen causes metabolic acidosis [3].

Hyperphosphatemia may develop in individuals who receive appropriate doses of Na-P enemas, with an average increase in serum phosphorus level of 1-1.3 mEq/L [7]. Changes in serum phosphorus and calcium levels occur within approximately 40 minutes of ingestion of a phosphate-containing enema [2]. Various factors play a role in the pathophysiology of hyperphosphatemia. Increased intake of sodium and phosphate, possibly due to gastrointestinal pathologies, or decreased elimination due to impaired renal function are two of the mechanisms implicated [5]. Poisoning due to the use of phosphate enemas is especially seen in children younger than 5 years old. Conditions that alter intestinal motility such as constipation, intestinal pseudo-obstruction, paralytic ileus, anorectal malformations, Hirschsprung's disease, myelomeningocele, colostomy, muscle abnormalities including SMA, and kidney failure may increase the risk of toxicity. In rare cases, it can occur in healthy children. In this case, the most common cause is dose error [3,8]. Our patient had chronic constipation as a risk factor, and in addition, adult dose BT enema® and pediatric fleet enema® were administered twice in the last 12 hours. The SMA gene analysis yielded normal results.

Symptoms of phosphate poisoning can range from mild gastrointestinal symptoms to life-threatening fatal arrhythmias. The most common symptoms include abdominal bloating, vomiting, hypernatremic dehydration, QT prolongation and arrhythmias. In severe cases, severe hypocalcemia may lead to neurological symptoms such as irritability, paresthesia, tetany, laryngospasm, altered consciousness, coma, and hyperthermia due to hypothalamic dysfunction. The symptoms manifest within a timeframe ranging from 30 minutes to 4 hours after the administration of the enema [3]. Our patient had intermittent enema intake. Electrolyte disturbances were detected in the examinations performed 30 minutes after the last enema. Our case had no symptoms secondary to hypocalcemia and hyperphosphatemia.

The most common electrolyte imbalance in phosphate poisoning is hyperphosphatemia, which may cause hypertonic dehydration, hypocalcemia, hypokalemia and hypernatremia [4,9]. First of all, if necessary, treatment should focus on

emergency airway management and cardiovascular resuscitation. Once hemodynamic stabilization is achieved, the treatment should first focus on restoring fluid status and normalizing electrolytes. Initial fluid therapy is crucial to ensure adequate perfusion and glomerular filtration rate [4-5,9]. In our patient, rapid IV hydration was administered first.

The effectiveness and safety of parenteral calcium administration are still controversial because it causes Ca-P precipitation in the kidney and other tissues, which remains a dilemma for clinicians. In a study, approximately 70% of the cases received IV calcium gluconate therapy to alleviate the symptoms of hypocalcemia [5]. Another publication reported that parenteral calcium replacement should be applied in patients with neuromuscular symptoms and cardiac arrhythmias [10]. Despite having hypocalcemia, our case was lucky because he did not have neurological or cardiovascular symptoms.

Conclusion

Sodium-phosphate enemas are commonly used in chronic constipation. However, their use can lead to life-threatening and even fatal consequences including hyperphosphatemia and secondary hypocalcemia. They should be used with more caution, especially in patients with underlying gastrointestinal or renal abnormalities. Physicians should be aware that phosphate poisoning may occur in healthy patients, even at therapeutic doses, due to rectal administration of a phosphate-containing enema. Neurological and cardiovascular symptoms should be carefully monitored, even in patients who have tolerated phosphate-containing enemas. The first step in treatment is intravenous hydration and diuresis.

References

1. Rubin G, Dale A. Chronic constipation in children. *BMJ*. 2006;18;333(7577):1051-5. doi: 10.1136/bmj.39007.760174.47.
2. Akyıldız B, Kondolot M, Yikilmaz A, Arslan D, Kurtoglu S. Ileus and intra-abdominal hypertension due to phosphate-containing enema. *Indian J Pediatr*. 2016;83(11):1346-8. doi: 10.1007/s12098-016-2166-3.
3. Nunez Sanchez MJ, Leighton Swaneck S, Diaz F. Severe tetany due to phosphate enemas use, case report. *Rev Chil Pediatr*. 2017;88(3):383-7. doi: 10.4067/S0370-41062017000300011.
4. Biebl A, Grillenberger A, Schmitt K. Enema-induced severe hyperphosphatemia in children. *Eur J Pediatr*. 2009;168(1):111-2. doi: 10.1007/s00431-008-0705-2.
5. Ladenhauf HN, Stundner O, Spreitzhofer F, Deluggi S. Severe hyperphosphatemia after administration of sodium-phosphate containing laxatives in children: case series and systematic review of literature. *Pediatr Surg Int*. 2012;28(8):805-14. doi: 10.1007/s00383-012-3124-4.
6. Greenbaum LA. Hyperphosphatemia. In: R.M. Khlegman, J.W.ST. Geme III editors, *Nelson Textbook of Pediatrics*, 21 edition. pp. 2123-2124.
7. Adamcewicz M, Bearely D, Porat G, Friedenberg FK. Mechanism of action and toxicities of purgatives used for colonoscopy preparation. *Expert Opin Drug Metab Toxicol*. 2011;7(1):89-101. doi: 10.1517/17425255.2011.542411.
8. Marraffa JM, Hui A, Stork CM. Severe hyperphosphatemia and hypocalcemia following the rectal administration of a phosphate-containing Fleet pediatric enema. *Pediatr Emerg Care*. 2004;20(7):453-6. doi: 10.1097/01.pec.0000132217.65600.52.
9. Pawlik W, Drzonek P, Nowak K. Severe Hyperphosphatemia As The Adverse Effect Of Sodium-Phosphate Enemas Use: Case Report And Review Of The Literature. In: *The Book Of Articles National Scientific Conference "1st Summer Scientific On-Line School"*. 2020. pp. 68.
10. Szoke D, Dolci A, Genderini A, Panteghini M. Fatal electrolyte abnormalities following enema administration. *Clin Chem*. 2012;58(11):1515-8. doi: 10.1373/clinchem.2011.170183.

Disclaimer/Publisher's Note: The statements, opinions, and data presented in all publications are exclusively those of the individual author(s) and contributor(s), and do not necessarily reflect the views of JOSAM, SelSistem and/or the editor(s). JOSAM, SelSistem and/or the editor(s) hereby disclaim any liability for any harm to individuals or damage to property that may arise from the implementation of any ideas, methods, instructions, or products referenced within the content.