

# Radiological approach to multinodular and vacuolating neuronal tumor: Two case report

Şükriye Firuze Ocak Karataş<sup>1</sup>, Murat Beyhan<sup>2</sup>, Erkan Gökçe<sup>2</sup>

<sup>1</sup> Department of Radiology, Bezmialem Vakıf University, Dragos Hospital, İstanbul, Turkey

<sup>2</sup> Department of Radiology, Tokat Gaziosmanpaşa University, Faculty of Medicine Hospital, Tokat, Turkey

## ORCID ID of the author(s)

ŞFOK: 0000-0002-9878-1065  
MB: 0000-0002-8630-4632  
EG: 0000-0003-3947-2972

## Corresponding Author

Murat Beyhan

Tokat Gaziosmanpaşa University, Faculty of Medicine, Department of Radiology, 60250, Tokat, Turkey

E-mail: muratbeyhan79@gmail.com

## Informed Consent

The authors stated that the written consent was obtained from the patients presented with images in the study.

## Conflict of Interest

No conflict of interest was declared by the authors.

## Financial Disclosure

The authors declared that this study has received no financial support.

## Published

2023 June 22

Copyright © 2023 The Author(s)

Published by JOSAM

This is an open access article distributed under the terms of the Creative Commons Attribution-NonCommercial-NoDerivatives License 4.0 (CC BY-NC-ND 4.0) where it is permissible to download, share, remix, transform, and buildup the work provided it is properly cited. The work cannot be used commercially without permission from the journal.



## Abstract

Multinodular and vacuolating neuronal tumors (MVNT) are indolent, low-grade, superficial neuronal tumors of the cerebrum that consist only of neuronal cells in adults. They were first reported in 2013 by Huse et al. and defined by the World Health Organization in 2016. MVNT is characterized by vacuolated tumor nodules with glial and/or neuronal differentiation histopathologically. MVNT is most commonly located in the temporal lobe. Radiologically, it has a subcortical, soap-bubble morphology, sometimes extending to the cortex, and is almost as hyperintense as cerebrospinal fluid on T2-weighted images. Its signal is not suppressed on the FLAIR sequence, and there is no diffusion restriction on diffusion-weighted images. Usually, there is no enhancement after gadolinium injections, but a few reports show weak enhancement in the literature. In the first case, we present a 22-year-old female with MVNT who underwent MRI for a complaint of dizziness which was detected incidentally. MRI showed a clustered multinodular lesion in the left superior frontal gyrus that was hyperintense on T2-weighted/FLAIR series and isointense with gray matter on T1-weighted images. There was no diffusion restriction or contrast enhancement on MRI. In the second case, a 51-year-old female with complaints of numbness and pain in her left arm had an MRI that showed a lesion in the right cerebral hemisphere at the temporoparietal junction. The lesion did not cause edema or mass effect and was distributed in the cortical-subcortical area. The lesion was hyperintense in T2-weighted and FLAIR series and consisted of many millimetric nodular components in close intensity with gray matter in the T1-weighted series. No contrast enhancement was detected. Knowing the characteristic imaging findings of MVNT is important in avoiding aggressive diagnosis and treatment approaches in asymptomatic cases. In conclusion, MVNT is a newly identified tumor that appears hyperintense on the FLAIR sequence and should not be operated on.

**Keywords:** magnetic resonance imaging, multinodular, neuronal, tumor, vacuolating

## Introduction

A multinodular and vacuolating neuronal tumor (MVNT) is a low-grade cerebral neuronal tumor defined as a "unique cytoarchitectural pattern of gangliocytoma" with an "uncertain class assignment" according to the 2016 World Health Organization (WHO) classification of central nervous system tumors [1-4]. It is unclear whether MVNT is a dysplastic or neoplastic cerebral lesion [2,3]. A cluster of nodular lesions is located within the superficial subcortical white matter and deep cortical ribbon [1,2]. MVNT can be unifocal, multifocal, bilateral or diffuse [5], asymptomatic, and detected incidentally. Sometimes, epileptic seizures can occur as symptoms. MVNT is typically stable with or without excision on follow-up, and recurrence is rare, even following incomplete resection [4,6-8]. It has been referred to as a "don't touch lesion" and "leave me alone lesion" by Nunes et al. [2] and De Wandeler et al. [9], respectively.

The diagnosis of MVNT is based on magnetic resonance imaging (MRI). Computed tomography (CT) may not detect small lesions. However, it can be seen as low-attenuation, non-calcified and non-enhanced lesions in subcortical white matter on CT [10]. MRI provides a more detailed examination than CT. On MRI, MVNT appears as a multinodular clustered lesion that hyperintense on T2-weighted images/fluid-attenuated inversion recovery (FLAIR) and iso-

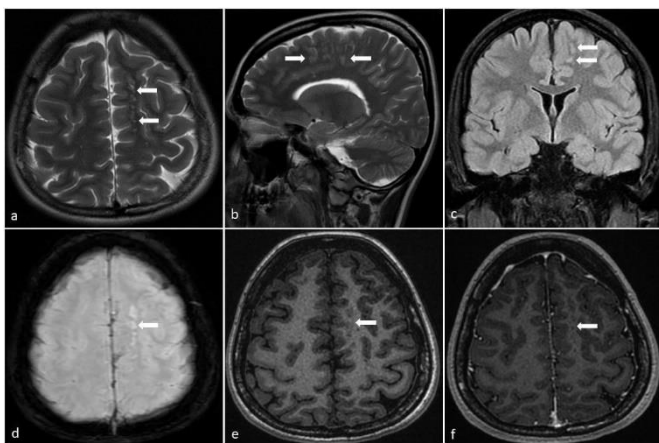
hypointense on T1-weighted images in the subcortical white matter without peripheral edema. There is usually no enhancement after gadolinium injections, but a few reports show weak enhancement in the literature [1,6]. MVNTs lacked IDH mutations (like infiltrating gliomas), and BRAF mutations (like ganglion cell tumors) in all cases reported [6-8]. MEK1 mutation has been reported in only one MVNT case [1,5]. HuC/HuD neuronal antigens were detected in tumor cells by nuclear immunolabeling in all cases [6]. We present our experience in two cases below.

## Case presentation

### Patient 1

The first case involved a 22-year-old female patient who underwent a 1.5T contrast-enhanced brain MRI due to dizziness that had been ongoing for three months. The MRI revealed a lesion approximately 4×3×1 cm in size, consisting of millimetric nodular components that did not cause edema or mass effect in the left superior frontal gyrus and distributed in the subcortical area. The multinodular clustering lesion was hyperintense on T2-weighted (Figure 1a, b)/ FLAIR (Figure 1c) and eSWAN (Figure 1d) series, similar to the intensity of gray matter on T1-weighted (Figure 1e) series, and did not enhance (Figure 1f) after gadolinium injections. The lesion did not have diffusion restriction on diffusion-weighted images. The lesion's appearance and stability in the follow-up MRI examination performed 16 months later support the diagnosis of MVNT. The patient was excluded from our follow-up after the last control MRI examination. Because the MR images used in the study did not contain any identifying information about the patient and because of the study's retrospective nature, informed consent was not obtained from the patients.

Figure 1: MR images of a 22-year-old female patient with dizziness. (a) Axial T2-weighted, (b) sagittal T2-weighted, (c) coronal FLAIR, and (d) eSWAN images shows hyperintense lesion; (e) axial T1-weighted images show the same intensity with grey matter, (f) and images taken after gadolinium injection show non-enhanced clustering multinodular lesion located in subcortical area of the left superior frontal gyrus.

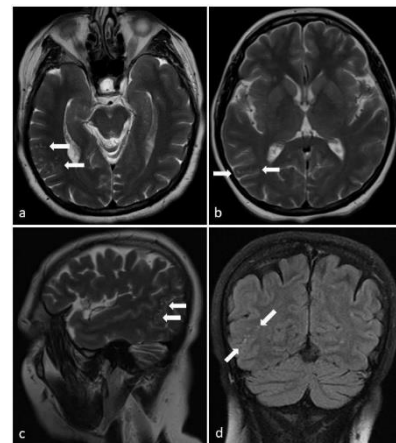


### Patient 2

In the second case, a 51-year-old female patient underwent a 1.5T contrast-enhanced brain MRI due to complaints of numbness and pain in her left arm. The MRI revealed a mass lesion consistent with an extra-axially located meningioma in the right frontal region. Incidentally, multinodular millimetric lesions distributed approximately 3.5×2×1.5 cm in the cortical-subcortical area were noted in the right cerebral hemisphere at the temporoparietal junction on MRI examination. The lesions did not cause edema or mass effect. The lesion was hyperintense on the T2-weighted (Figure 2a-c) and FLAIR (Figure 2d) series,

isointense with the grey matter on the T1-weighted series, and did not enhance after contrast administration. The appearance of the lesion was compatible with MVNT based on the previous MRI examination. There was no difference in the appearance of the MVNT lesion in the first-year follow-up MRI examination of the patient who underwent surgery for meningioma. Informed consent was not obtained from the patients because the MR images used in the study did not contain any identifying information about the patient and because of the study's retrospective nature.

Figure 2: MR images of a 51-year-old female patient with complaints of numbness and pain in her left arm (a) and (b) axial T2-weighted, (c) sagittal T2-weighted, (d) coronal FLAIR images show a hyperintense multinodular lesion (arrows) located in subcortical area of the right temporoparietal area.



## Discussion

MVNT typically occurs in the temporal lobe of elderly patients with seizures and has no common mutations [4]. It is usually discovered incidentally through MRI. The exact prevalence of MVNT may be unknown, as most lesions are not removed in asymptomatic individuals [2]. There have been a few "out of the ordinary" lesions; however, MTVN is defined in the literature as a non-enhanced, non-progressive cerebral lesion. Agarwal et al. [11] reported three cerebellar lesions. Huse et al. [6] reported 20% (2 out of 10 patients), and Alsufayan et al. [5] reported 11% (2 out of 24 patients) contrast-enhancement lesions. Additionally, Alsufayan et al. [5] reported progression in 6.7% of lesions monitored by MRI, which goes against the literature.

Although the most common clinical presentation was seizure episodes, Nunes et al. [2] observed seizures in only 19% of patients in their study. In the study by Alsufayan et al. [5], which involved 24 patients, 50% had a headache, 25% had visual symptoms, 20-25% had seizures, 17% had paresthesia, and 17% had cognitive difficulties. Gökçe [1] also reported that one of the patients had epilepsy and the other had a headache in his study of two cases. In Huse et al.'s [6] study, 70% of the lesions were found in the temporal lobe, whereas in Alsufayan et al.'s study [5], 50% of the lesions were found in the frontal lobe, 23% in the parietal lobe, 10% in the occipital lobe, 6% in the temporal lobe, and 6% in the frontotemporal lobes. Our cases were located in the frontal and temporoparietal areas.

It is unclear whether MVNTs are dysplastic or neoplastic. Histologically, MVNTs consist of multinodular tissue with a vacuolated stroma populated by the irregular proliferation of neuronal cells of uncertain phenotype containing ganglion-like cells [7]. Secondary features, such as perivascular lymphocytic infiltrate, Rosenthal fibers, eosinophilic granular bodies, and

microcalcifications commonly found in ganglion cell tumors, are entirely absent in MVNTs [12]. On the other hand, they have shown negativity or mild positivity for neuronal markers such as neurofilament proteins, neuronal nuclear antigen, and synaptophysin, which are related to mature neurons [1,6-8,10].

Thom et al. [4] also found that these lesions were more similar to dysplastic lesions than to true neoplasms in their study. MVNTs have some overlapping imaging findings with dysembryoplastic neuroepithelial tumors (DNETs), malformations of cortical development such as focal cortical dysplasia (FCD), and enlarged Virchow-Robin perivascular spaces (VRPVS). All of these should be considered in the differential diagnosis of MVNTs [1,2,10].

Dysembryoplastic neuroepithelial tumor (DNET) should be the first tumor to consider in the differential diagnosis of MVNT based on radiologic examinations [1]. Some studies have reported that at least 3 out of 12 MVNT cases were diagnosed with DNET radiologically [6,8]. DNET is a cortical, well-demarcated, wedge-shaped, lobulated contour lesion with low-isointense and a bright frame on T2/FLAIR images on MRI [1,5,7,13]. Calcification and hemosiderin staining can be seen on CT images in DNET, unlike MVNT. The absence of cortical involvement and predominance of deep white matter help distinguish MVNT from DNET [5]. However, histological analyses can differentiate between MVNTs and DNETs. MVNTs lack the "specific glioneuronal element" that is a signature finding in classic DNETs. Moreover, the combination of prominent vacuolation, lesion cells of indeterminate lineage, and multinodular coarse stroma that characterizes MVNTs is not seen in DNET [7,13]. Malformations of cortical development (MCD), such as nodular heterotopia or FCD type 2, may also be confused with MVNT [5,7]. Nodular heterotopia is characterized by the presence of mature gray matter in the white matter. Unlike MVNT, there are NeuN-positive mature neurons in nodular heterotopia [7,14]. FCD type 2 has a high T2 signal in the deep cortex, similar to MVNT. It is usually associated with a radial glial band (transmantle sign) extending towards the ventricle and having abnormal cortical thickness. MVNT can also resemble FCD when they extend towards the ventricle. However, MVNT shows a bubble-like extension rather than a band-like one [5]. Virchow-Robin perivascular spaces (VRPVS) may also have similar imaging features to MVNT. Although VRPVS may have the same location as MVNT, they are generally longer along the long axis of the vessel [2,5]. In some cases, a few cystic changes may be present in VRPVS, which may be confusing [5]. However, MVNT is typically seen as cerebrospinal fluid-like a signal on all series on MRI, while MVNTs are bright on FLAIR [2,5].

The major limitation of this case is the lack of pathological evidence, and it is based only on MRI. Fortunately, the MRI findings are almost pathognomonic [3]. In this case, the characteristic MRI findings of the lesion, such as the absence of structural or size changes on follow-up examinations, support that it is MVNT.

### Conclusion

MVNT is a newly defined entity often detected incidentally on MRI and is considered a "don't touch me lesion" with current knowledge. Understanding the characteristic imaging

findings of MVNT is crucial to avoid aggressive diagnostic and treatment approaches in asymptomatic case.

### References

- Gökçe E. Magnetic resonance imaging findings of two cases with multinodular and vacuolating neuronal tumor. *Acta Neurol Belg.* 2020;120(2):457-61.
- Nunes RH, Hsu CC, da Rocha AJ, do Amaral LLF, Godoy LFS, Watkins TW, et al. Multinodular and vacuolating neuronal tumor of the cerebrum: a new "leave me alone" lesion with a characteristic imaging pattern. *AJNR Am J Neuroradiol.* 2017;38(10):1899-904.
- Louis DN, Perry A, Reifenberger G, Von Deimling A, Figarella-Branger D, Cavenee WK, et al. The 2016 World Health Organization classification of tumors of the central nervous system: a summary. *Acta Neuropathol.* 2016;131(6):803-20.
- Thom M, Liu J, Bongaarts A, Reinten RJ, Paradiso B, Jäger HR, et al. Multinodular and vacuolating neuronal tumors in epilepsy: dysplasia or neoplasia? *Brain Pathol.* 2018;28(2):155-71.
- Alsufayan R, Alcaide-Leon P, De Tilly LN, Mandell DM, Krings T. Natural history of lesions with the MR imaging appearance of multinodular and vacuolating neuronal tumor. *Neuroradiology.* 2017;59(9):873-83.
- Huse JT, Edgar M, Halliday J, Mikolaenko I, Lavi E, Rosenblum MK. Multinodular and vacuolating neuronal tumors of the cerebrum: 10 cases of a distinctive seizure-associated lesion. *Brain Pathol.* 2013;23(5):515-24.
- Fukushima S, Yoshida A, Narita Y, Arita H, Ohno M, Miyakita Y, et al. Multinodular and vacuolating neuronal tumor of the cerebrum. *Brain Tumor Pathol.* 2015;32(2):131-6.
- Bodi I, Curran O, Selway R, Elwes R, Burrone J, Laxton R, et al. Two cases of multinodular and vacuolating neuronal tumour. *Acta Neuropathol Commun.* 2014;2(1):1-10.
- De Wandeler T, De Brucker Y, Jansen A, Vanderhasselt T. Multinodular and vacuolating neuronal tumor of the cerebrum (MVNT): do not touch. *Acta Neurol Belg.* 2020;120(3):747-8.
- Yamaguchi M, Komori T, Nakata Y, Yagishita A, Morino M, Isozaki E. Multinodular and vacuolating neuronal tumor affecting amygdala and hippocampus: a quasi-tumor? *Pathol Int.* 2016;66(1):34-41.
- Agarwal A, Lakshmanan R, Devagnanam I, Bynevelt M. Multinodular and Vacuolating Neuronal Tumor of the Cerebrum: Does the Name Require Review? *AJNR Am J Neuroradiol.* 2019;40(12):69-70.
- Becker AJ, Wiestler OD, Figarella-Branger D, Blumcke I. Ganglioglioma and gangliocytoma. In: Louis DN, Ohgaki H, Wiestler OD, Cavenee WK, editors. *WHO Classification of Tumours of the Central Nervous System.* 4th ed. Lyon: International Agency for Research on Cancer; 2007. pp. 103-5.
- Daumas-Duport C, Varlet P. Dysembryoplastic neuroepithelial tumors. *Rev Neurol.* 2003;159:622-36.
- Meroni A, Galli C, Bramerio M, Tassi L, Colombo N, Cossu M, et al. Nodular heterotopia: a neuropathological study of 24 patients undergoing surgery for drug-resistant epilepsy. *Epilepsia.* 2009;50(1):116-24.