

# Autistic child with abdominal pain caused by foreign body ingestion

## Yabancı cisim alımından kaynaklanan karın ağrısı olan otistik çocuk

Zerrin Özçelik<sup>1</sup>, Didem Gülcü Taşkın<sup>2</sup>

<sup>1</sup> Department of Pediatric Surgery, Adana City Training and Research Hospital, Istanbul, Turkey

<sup>2</sup> Department of Pediatric Gastroenterology, Adana City Education and Research Hospital, Istanbul, Turkey

ORCID ID of the author(s)

ZÖ: 0000-0003-3728-0846

DGT: 0000-0002-2746-3799

### Abstract

Foreign body ingestion is an important condition with a potentially high mortality rate that is encountered in pediatric emergency departments and outpatient polyclinics. Foreign body ingestion occurs in 80% of children, especially those between 6 months and 3 years of age. However, in patients with mental disorders, in this case, autism, foreign body ingestion may occur at any age. A 16-year-old autistic patient presented with complaints of discomfort and restlessness, with no history of ingestion, however, we discovered through further investigations that the patient had in fact swallowed a foreign object. In this case, we would like to emphasize that autistic patients of any age can ingest foreign bodies, even without any suspicious history.

**Keywords:** Foreign body, Intestinal perforation, Autism, Abdominal pain

### Öz

Yabancı cisim yutulması, pediatrik acil servislerinde ve genel polikliniklerde karşılaştığımız, potansiyel olarak yüksek ölüm oranına sahip olabilecek önemli bir durumdur. Yabancı cisim yutulması çocukların % 80'inde ve özellikle 6 ay ile 3 yaş arasındaki çocuklarda görülür. Ancak ruhsal bozukluğu olan hastalarda, özellikle bu olguda olduğu gibi otizimli çocuklarda, yabancı cisim yutulması her yaşta ortaya çıkabilir. 16 yaşındaki otistik bir hastada, rahatsızlık ve huzursuzluk şikayeti ile getirildi, öyküsünü sorguladığımızda bize yararlı bir bilgi yoktu, daha ileri incelemelerde hastanın aslında yabancı bir nesneyi yuttuğunu fark ettik. Bu durum nedeni ile her yaştaki otistik hastaların öykü alma sırasında herhangi bir şüphe duymadan yabancı cisim yutabileceğini vurgulamak istiyoruz.

**Anahtar kelimeler:** Yabancı cisim, İntestinal perforasyon, Otizim, Karın ağrısı

## Introduction

Foreign body ingestion is an important condition with a high mortality rate that we encounter in pediatric emergency departments and general polyclinics [1]. Foreign body ingestion occurs in 80% of children, especially in those between 6 months and 3 years of age. The incidence reported in the American Association of Poison Control Centers' National Poison Data System in 2016 is 1,810,030 patients per year [2]. However, in patients with mental disorders, in this case, autism, foreign body ingestion may occur at any age. A 16-year-old autistic patient presented with complaints of discomfort and restlessness, with no suspicious history, and we discovered through further investigations that the patient had in fact swallowed a foreign object. Based on this case, we would like to emphasize that autistic patients of any age can ingest foreign bodies even without any suspicions revealed during history taking.

Corresponding author / Sorumlu yazar:  
Zerrin Özçelik

Address / Adres: Adana Şehir Eğitim Araştırma Hastanesi, Kışla Mahallesi, Dr. Mithat Özsan Bulvarı, 4522. Sokak No:1, Yüreğir, Adana, Türkiye  
E-mail: zerrinozcelik@gmail.com

Informed Consent: The authors stated that the written consent was obtained from the parents of the patient presented with images in the study.  
Hasta Onamı: Yazarlar çalışmada görüntüleri ile sunulan hastanın ebeveynlerinden yazılı onam alındığını ifade etmiştir.

Conflict of Interest: No conflict of interest was declared by the authors.

Çıkar Çatışması: Yazarlar çıkar çatışması bildirmemişlerdir.

Financial Disclosure: The authors declared that this study has received no financial support.

Finansal Destek: Yazarlar bu çalışma için finansal destek almadıklarını beyan etmişlerdir.

Published: 10/28/2020  
Yayın Tarihi: 28.10.2020

Copyright © 2020 The Author(s)  
Published by JOSAM

This is an open access article distributed under the terms of the Creative Commons Attribution-Non Commercial-NoDerivatives License 4.0 (CC BY-NC-ND 4.0) where it is permissible to download, share, remix, transform, and build upon the work provided it is properly cited. The work cannot be used commercially without permission from the journal.



## Case presentation

A 16-year-old male patient was referred to the pediatric emergency service with complaints of discomfort and restlessness. He was not mentally healthy enough to explain his complaints or history. The family stated that he has been in discomfort for the last 10 days and had clear abdominal pain for the last 2 days. There was nothing suspicious in his history. Physical examination revealed abdominal tenderness, defense, and rebound. There were no findings in laboratory tests. The patient was sent for a Direct Abdominal X-Ray (Figure 1), which revealed a spoon in the duodenal region.

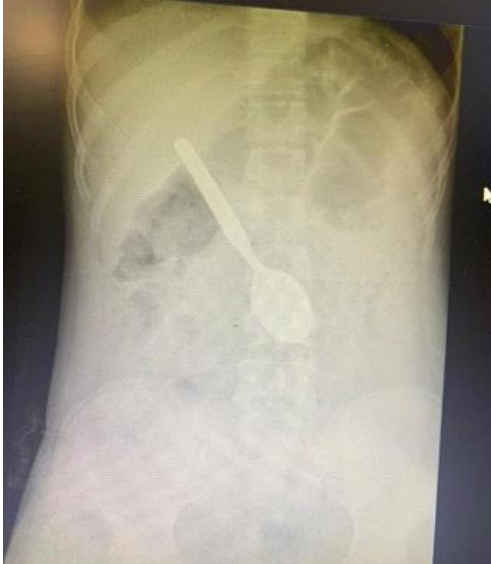

Figure 1: Patients first X-ray taken with the spoon visible

In the esophagogastroduodenoscopy, the spoon was observed in the 2<sup>nd</sup> part of the duodenum and removed. There was free air under the diaphragm in the direct graph obtained for control purposes (Figure 2). The patient was then transported to the operation room. Operative findings included perforation in the intestinal mucosa contacting the spoon (Figure 3). Primary repair was performed. The patient recovered uneventfully following the operation. His control examination was normal, and he had no complaints.

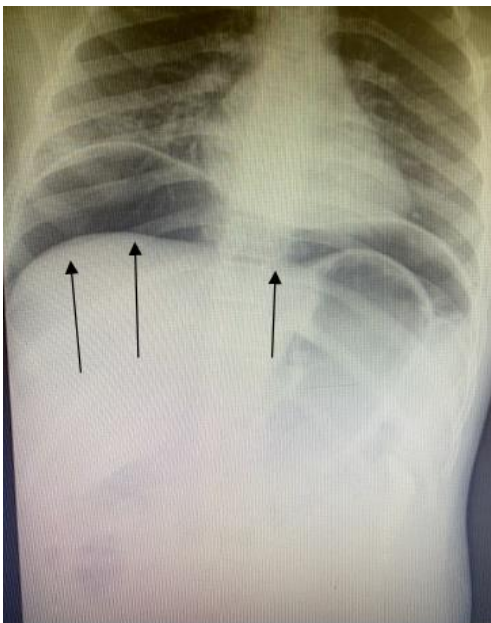


Figure 2: Post esophagogastroduodenoscopy X-ray shows free air under the diaphragm

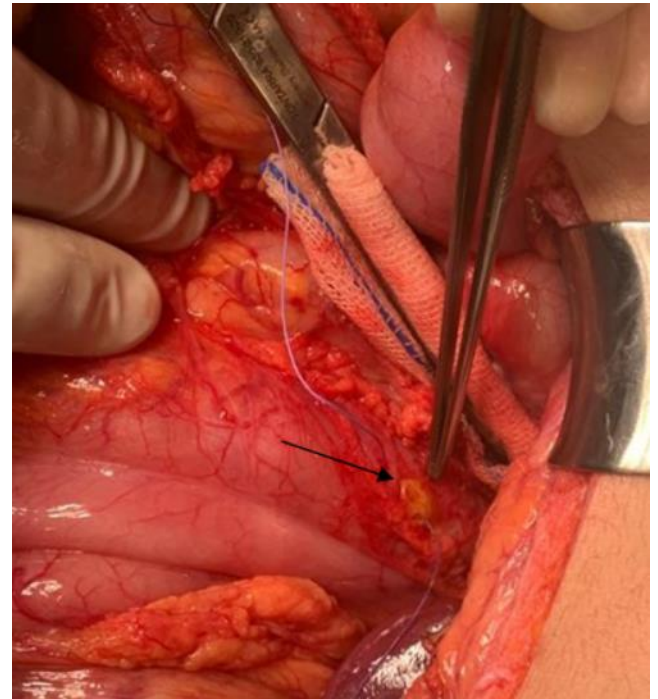


Figure 3: During the operation, the perforation was found in the 2<sup>nd</sup> part of the duodenum.

## Discussion

Foreign body ingestion, a clinical condition we frequently encounter in pediatric outpatient clinics and emergency departments, may have a high mortality. In 80% of the cases, the foreign bodies leave the body naturally by passing through the pylorus and ileocecal valve, while in 20%, endoscopic intervention is required. Surgical intervention is required in approximately 1% of cases due to complications such as obstruction, fistula and perforation [3,4]. Detailed history taking may not be possible in various patient groups, and such was the case in our patient with autism. In some cases, family members may not be aware of the event. A retrospective study reported that 40% of foreign body ingestion cases occurred without witnesses [5]. In cases where the patient cannot describe the situation, unexplained abdominal pain is an important symptom and one should always consider foreign bodies ingestion. The size and localization of the ingested body increases the risk of perforation. The period between ingestion and diagnosis varies, depending on the small age group and the absence of witnesses, which affects the development of perforation and fistula [3,4]. In our patient, we removed the foreign body, which was localized in the 2<sup>nd</sup> part of the duodenum, with an esophagogastroduodenoscope. Due to duodenal folds and peristalsis, the mucosal appearance may not be thoroughly evaluated macroscopically, and mucosal damage caused by foreign body may be overlooked. As in our patient, the perforated area could not be evaluated and was only noticed on the abdominal direct radiograph obtained postoperatively, which showed intraabdominal free air. With this case, we wanted to emphasize the need for radiological examination after removal of the foreign body. It is of foremost importance not to overlook the possible perforations.

## Conclusion

Foreign body ingestion can be seen in all pediatric age groups. Especially in patients brought to the emergency department with complaints of abdominal pain and discomfort

who cannot express themselves, foreign body ingestion should be investigated. We wanted to emphasize that after foreign bodies that are difficult to remove endoscopically, radiological examination is necessary to rule out perforation.

## References

1. Kim SY, Park B, Kong IG, Choi HG. Analysis of ingested foreign bodies according to age, type and location: A retrospective observational study. *Clin Otolaryngol.* 2016;41:640-5.
2. Gummin DD, Mowry JB, Spyker DA, Brooks DE, Fraser MO, Banner W. 2016 Annual Report of the American Association of Poison Control Centers' National Poison Data System (NPDS): 34th Annual Report. *Clin. Toxicol.* 2017;55:1072-52.
3. Pederiva F, Daniela C, Scarpa MG, Guida E, Dragovic D, Martelossi S. An Asymptomatic Multiple Magnet Ingestion with Transmesenteric Entero-Enteric Fistula. *APSP J Case Rep.* 2014;5(2):16.
4. Brown DJ. Small bowel perforation caused by multiple magnet ingestion. *J Emerg Med.* 2010;39:497-8.
5. Gün F, Günendi T, Kılıç B, Celik A. Multiple magnet ingestion resulting in small bowel perforation: a case report. *Turkish Journal of Trauma & Emergency Surgery.* 2013;19(2):177-9.

This paper has been checked for language accuracy by JOSAM editors.

The National Library of Medicine (NLM) citation style guide has been used in this paper.