

A rare cause of steal phenomenon and ischemic pain: A radial artery pseudoaneurysm

Çalma fenomeni ile iskemi ağrısının nadir bir nedeni: Radial arter psödoanverizması

Elif Coşkun Sungur¹, Ferit Kasımzade¹, Nuhcan Koçak¹

¹ Ankara City Hospital, Department of
Cardiothoracic Surgery, Cankaya, Ankara,
Turkey

ORCID ID of the author(s)

ECS: 0000-0002-2275-639X

FK: 0000-0003-3646-3181

NK: 0000-0002-1108-1868

Abstract

Catheter insertion and forearm arteriovenous shunts are the main reasons for pseudoaneurysms in the practice of cardiovascular surgery. Radial artery pseudoaneurysm from arterial wall disruption is an extremely rare complication of arterial approach. Herein, we report a case of radial pseudoaneurysm repair leading to steal phenomenon and ischemic pain which occurred following the closure of the arteriovenous fistula located between the radial artery and cephalic vein in the medial aspect of the right forearm in a 37-year-old male receiving regular hemodialysis for chronic renal failure.

Keywords: Radial pseudoaneurysm, Arteriovenous fistula, Steal phenomenon

Öz

Kalp ve damar cerrahisinde psödoanverizmaların en önemli nedeni, kateter uygulamaları ve ön kolda açılan arteriyovenöz şantlardır. Arteriyel duvar bozulmasından kaynaklanan radyal arter psödoanverizması, arteriyel yaklaşımın oldukça nadir görülen bir komplikasyonudur. Bu yazıda, kronik böbrek yetmezliği nedeniyle rutin hemodiyalize giren 37 yaşında erkek bir olguda, efektif çalışmayan sağ ön kol medial yüzde radial arter ve sefalik ven arasında arteriyovenöz fistülün kapatılması sonrasında oluşan ve çalma fenomeni nedeniyle iskemi ağrısı oluşturan radial arter psödoanverizma tamiri sunuldu.

Anahtar kelimeler: Radial psödoanverizma, Arteriyovenöz fistül, Çalma fenomeni

Introduction

Pseudoaneurysms usually occur at the site of needling/puncture or at the anastomoses and can be defined as hematomas communicating with the vascular lumen. They may develop into a fibrotic sac over time, which is devoid of an endothelium or vascular wall structure [1].

Risk factors include advanced age, diabetes, female sex, hypertension, fibrinolytic or anticoagulant therapy, peripheral vasculopathy, regular hemodialysis, repeated percutaneous interventions, long catheterization time, large catheter diameter, coagulation disorder, incomplete hemostasis, multiple puncture attempts, inadequate compression after the procedure, and vascular site infection [2-4].

In the few reported cases of radial artery pseudoaneurysms, surgical repair is the most commonly used treatment [5]. We herein report a case of radial pseudoaneurysm leading to steal phenomenon and ischemic pain which occurred following the closure of the arteriovenous fistula (AVF) located between the radial artery and cephalic vein in the medial aspect of the right forearm in a patient receiving regular hemodialysis for chronic renal failure.

Corresponding author / Sorumlu yazar:

Elif Coşkun Sungur

Address / Adres: Ankara Şehir Hastanesi, Kalp ve
Damar Cerrahisi Bölümü, Bilkent Entegre Sağlık
Kampüsü, Bilkent Caddesi, No: 1, Çankaya,
Ankara, Türkiye
E-mail: drelco@gmail.com

Informed Consent: The authors stated that the
written consent was obtained from the patients
presented with images in the study.

Hasta Onamı: Yazarlar çalışmada görüntüleri ile
sunulan hastalardan yazılı onam alındığını ifade
etmiştir.

Conflict of Interest: No conflict of interest was
declared by the authors.

Çıkar Çatışması: Yazarlar çıkar çatışması
bildirmemişlerdir.

Financial Disclosure: The authors declared that
this study has received no financial support.

Finansal Destek: Yazarlar bu çalışma için finansal
destek almadıklarını beyan etmişlerdir.

Published: 7/13/2020

Yayın Tarihi: 13.07.2020

Copyright © 2020 The Author(s)

Published by JOSAM

This is an open access article distributed under the terms of the Creative
Commons Attribution-Non Commercial-NoDerivatives License 4.0 (CC
BY-NC-ND 4.0) where it is permissible to download, share, remix,
transform, and buildup the work provided it is properly cited. The work
cannot be used commercially without permission from the journal.



Case presentation

A 37-year-old male patient was admitted to our outpatient clinic with a swollen wrist and severe pain in the right arm for one week. His medical history revealed renal transplantation a decade ago and rejection two years ago. The patient underwent several operations previously for the creation of an AVF in the right arm for hemodialysis, and the last AVF where the wrist swell was closed surgically four years ago. He was receiving clopidogrel 75 mg/kg/day, doxazosin 8 mg/day, and prednisolone 5 mg/day. Laboratory test results were as follows: Urea: 155 mg/dL, creatinine: 9,06 mg/dL, and erythrocyte sedimentation rate: 17/mm/h. Electrocardiography and chest X-ray showed normal findings. Visual inspection of the right arm demonstrated surgical scars including a 2-cm transverse scar in the snuffbox region, a 10-cm vertical scar in the radial aspect, and a 6-cm transverse scar in the antecubital region (Figure 1). Physical examination revealed a 3x3 cm pulsatile swelling in the radial aspect of the right hand above the surgical scar. Radial pulse was present proximal and distal to the swelling; however, no ulnar pulse was documented. On auscultation, there were murmur and a palpable thrill.

Superficial ultrasonography revealed a 15-mm pseudoaneurysm originating from the radial artery, mostly with a thrombosed lumen. Upper limb arteriography was performed to obtain a definite diagnosis of the pseudoaneurysm, probably located in the former AVF line, and evaluate its relationship with other vascular structures. According to the arteriography findings, there was a pseudoaneurysm in the fistula line of the radial artery, the palmar arch was filled by the radial artery, and ulnar artery was occluded (Figure 2). As the radial artery is the only source of arterial blood flow to the hand, closure using interventional radiological procedures was not preferred. Surgical repair of the pseudoaneurysm was decided and a written informed consent was obtained from the patient.

Skin incision was performed under local anesthesia and the pseudoaneurysm sac was reached. The radial artery, released from the proximal and distal ends, was rotated, and clamped after intravenous administration of heparin 80 IU/kg. The arterial continuity was disrupted in the distal segment. Dissection was performed and a vascular clamp was placed to the distal segment. The pseudoaneurysm sac was then excised. Specimens from both solid and fluid material inside the sac were collected for pathological and microbiological examination. As the proximal and distal ends of the radial artery were unable to be repaired in an end-to-end fashion, saphenous vein graft interposition was performed (Figure 3). The vascular clamps were released, and it was observed that radial artery was pulsatile with adequate microcirculation on palpation. No microorganism was isolated in the culture. Clinical diagnosis was confirmed by the pathological examination. The patient was uneventfully discharged from the hospital on postoperative day 2.

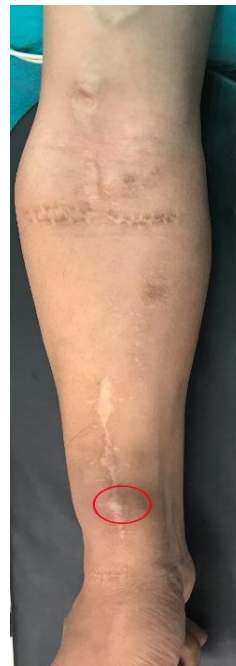

Figure 1: A preoperative image of surgical scars and swollen radial pseudoaneurysm in the right forearm (red circle)

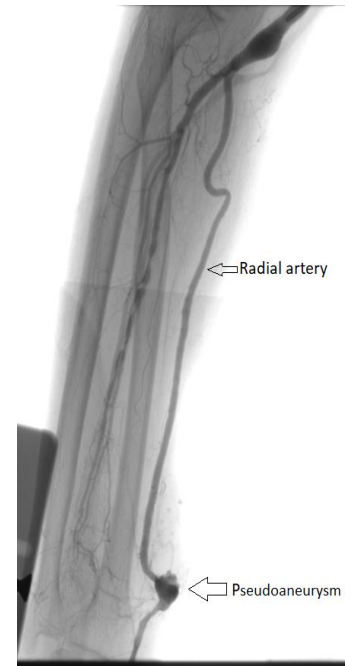


Figure 2: An arteriography image showing a radial pseudoaneurysm in the right upper limb

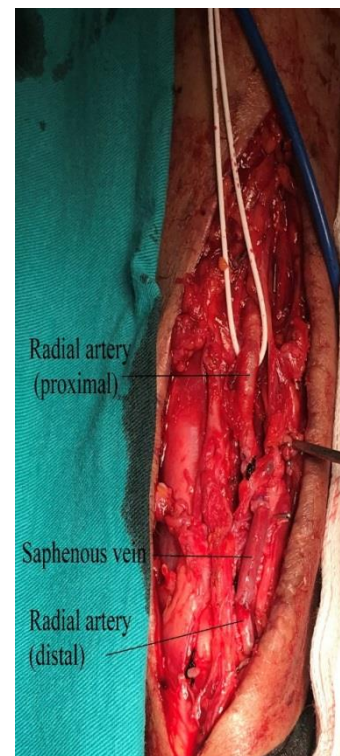


Figure 3: An intraoperative image of saphenous vein graft interposition of the radial artery after the excision of pseudoaneurysm sac

Discussion

Regular puncture and anticoagulation make pseudoaneurysms and true aneurysms relatively common complications in patients receiving hemodialysis [5]. Vascular access is essential to ensure effective hemodialysis treatment in dialysis patients. Unfortunately, vascular access complications are common, and many complications can threaten vascular access [1]. Pseudoaneurysms are one of these complications.

Clinical presentation of pseudoaneurysm varies depending on the localization, size, and growth rate of the pseudoaneurysm. The main goal of treatment of a radial pseudoaneurysm is to repair the wall lesion or discontinue the flow communication between the artery and the parenchymal

hematoma. In general, treatment depends on the etiology, location, symptoms, presence of thrombi, distal circulation, and collateral formation [3].

Surgical options to recover the AVF should be considered in AVF aneurysms. If the aneurysm is small and discrete in a tortuous AVF, it may reconstruct the AVF with a direct end-to-end anastomosis [6]. In case of larger aneurysms, either a bypass with a graft or an aneurysmorrhaphy can be performed [7,8]. To ensure the vascular continuity immediately in acute arterial pathologies which are not eligible for primary repair, autogenous veins with higher long-term patency rates that are highly resistant to infections should be preferred [9]. The small saccular pseudoaneurysms with narrow necks may be suitable to thrombin injection [10] or ultrasound compression [11]. This non-invasive technique can be attempted before the initiation of surgical or endovascular alternatives. In recent years, endovascular techniques have been also used widely in the treatment of AVF aneurysms [12].

In our case, there was a small, but a suddenly and rapidly growing pseudoaneurysm originating from the single artery which filled the palmar arch and, thereby, led to steal phenomenon and ischemic pain. Since the radial artery was the only source of arterial blood flow to the hand, non-surgical closure was not considered feasible. Therefore, the pseudoaneurysm sac was resected and the proximal and distal vascular defect was repaired using a saphenous vein graft.

Vascular complications such as pseudoaneurysms can easily occur in patients undergoing multiple vascular operations due to chronic renal failure, resulting in severe ischemic pain. In addition, patients should be educated and trained on modifiable risk factors after surgery, which is as important as the treatment itself.

References

1. Mudoni A, Cornacchiarri M, Gallieni M, Guastoni C, Mc Grogan D, Logias F, et al. Aneurysms and pseudoaneurysms in dialysis access. *Clin Kidney J.* 2015;8(4):363–7.
2. San Norberto Garcia EM, Gonzalez-Fajardo JA, Gutierrez V, Carrera S, Vaquero C. Femoral pseudoaneurysms post-cardiac catheterization surgically treated: evolution and prognosis. *Interact Cardiovasc Thorac Surg.* 2009;8(8):353-8.
3. Alerhand S, Apakama D, Nevel A, Nelson BP. Radial artery pseudoaneurysm diagnosed by point of care ultrasound five days after transradial catheterization: A case report. *World J Emerg Med.* 2018;9(3):223–6.
4. Kerr CD, Duffey TP. Traumatic false aneurysm of the radial artery. *J Trauma.* 1988; 28:1603–4.
5. Kongunattan V, Ganesh N. Radial Artery Pseudoaneurysm following Cardiac Catheterization: A Nonsurgical Conservative Management Approach. *Heart Views.* 2018;19(2):67–70.
6. Almehti A, Wang S. Partial aneurysmectomy is effective in managing aneurysm-associated complications of arteriovenous fistulae for hemodialysis: case series and literature review. *Semin Dial.* 2012;25:357–64.
7. Hossny A. Partial aneurysmectomy for salvage of autogenous arteriovenous fistula with complicated venous aneurysms. *J Vasc Surg.* 2014;59:1073-7.
8. Balaz P, Rokosny S, Klein D, Adamec M. Aneurysmorrhaphy is an easy technique for arteriovenous fistula salvage. *J Vasc Access.* 2008;9:81–4.
9. Becit N, Ateş A, Özyazicioğlu A, Ceviz M, Yilmaz M. Evaluation and Surgical Treatment in Peripheral Arterial Injuries. *Turk Gogus Kalp Dama.* 2000;8(1):540-4.
10. O'Neill JM, Jenkins DA, Ireland HM. Recurrence of dialysis shunt pseudoaneurysm following percutaneous thrombin embolization. *Cardiovasc Intervent Radiol.* 2001;24:441–2.
11. Witz M, Werner M, Bernheim J, Shnaker A, Lehmann J, Korzets Z. Ultrasound-guided compression repair of pseudoaneurysms complicating a forearm dialysis arteriovenous fistula. *Nephrol Dial Transplant.* 2000;15:1453–4.
12. Mantha ML, Baer R, Bailey GS, Wu RL, Killen JP. Endovascular repair of a hemodialysis fistula aneurysm with covered stents. *Kidney Int* 2009;76:918.

This paper has been checked for language accuracy by JOSAM editors.

The National Library of Medicine (NLM) citation style guide has been used in this paper.