

Bladder leiomyoma: A case report and brief review of literature

Mesane leiomyomu: Olgu sunumu ve kısa literatür derlemesi

Engin Köllükçü¹, Bekir Süha Parlaktas², Faik Alev Deresoy³, Murat Beyhan⁴, Latif Mustafa Özbek⁵

¹ Tokat State Hospital, Department of Urology, Tokat, Turkey

² Gaziosmanpaşa University, Department of Urology, Tokat, Turkey

³ Gaziosmanpaşa University, Department of Pathology, Tokat, Turkey

⁴ Tokat State Hospital, Department of Radiology, Tokat, Turkey

⁵ Iğdır State Hospital, Department of Urology, Iğdır, Turkey

ORCID ID of the author(s)

EK: 0000-0003-3387-4428

BSP: 0000-0001-8754-4155

FAD: 0000-0002-2243-9394

MB: 0000-0002-8630-4632

LMÖ: 0000-0002-0680-4451

Abstract

Leiomyomas are non-epithelial benign and rare lesions of bladder. Their symptoms vary considerably based on the size, localization and nature of the lesion. Recently, an optimal treatment option for bladder leiomyoma is still contradictive. Transurethral resection, segmental surgical excision or partial cystectomy are main treatment modalities. This study presents a 41 year-old male case who applied to our center with hematuria complaint and had leiomyoma diagnosis based on tissue sampling following transurethral resection.

Keywords: Bladder, Leiomyoma

Öz

Leiomyomlar mesanenin nonepitelyal benign lezyonları olup oldukça nadir olarak izlenmektedirler. Semptomatoloji olgular arasında lezyonun büyüklüğüne, lokalizasyonuna ve karakterine göre oldukça farklılıklar göstermektedir. Günümüzde mesane leiomyomu için optimal tedavi seçeneğinin konusundaki tartışmalar devam etmektedir. Transüretral rezeksiyon, segmental cerrahi eksizyon veya parsiyel sistektomi ana tedavi yöntemleri olarak gösterilmektedir. Bu çalışmada hematüri ile başvuran ve uygulanan transüretral rezeksiyon sonrası doku tanısı leiomyom olarak sonuçlanan 41 yaşındaki erkek olgunun sunulması amaçlanmıştır.

Anahtar kelimeler: Mesane, Leiomyom

Introduction

Leiomyomas are benign mesenchymal tumors originating from smooth muscles. They can be observed in any organ with smooth muscles. They frequently develop in one organ, and have a solitary character, but they may appear in several organs or as multiple lesions in one organ [1]. In genitourinary system, leiomyomas are most commonly found in renal capsule, but they are quite rare in bladder. They constitute less than 0.5% of all bladder tumors [2,3]. Some of the leiomyomas observed in bladder are diagnosed accidentally and these patients could have a wide range of clinical presentations such as hematuria, dysuria and pollakiuria [4].

Treatment of bladder leiomyomas is still controversial today. Localization, size and nature of these lesions are important for the treatment method of choice. Transurethral resection, segmental surgical excision or partial cystectomy are main treatment modalities used for the treatment of these cases [4-5]. The aim of the present study was to discuss in light of the literature a case who applied to our clinic with hematuria complaint and was diagnosed bladder localized leiomyoma.

Corresponding author / Sorumlu yazar:
Engin Köllükçü

Address / Adres: Üroloji Bölümü, Tokat Devlet Hastanesi, Gültekin Topçam Bulvarı, Yeni Cadde, Tokat, Türkiye

e-Mail: drenginkolukcu@gmail.com

Informed Consent: The authors stated that the written consent was obtained from the patient presented in the study.

Hasta Onamı: Yazar çalışmada sunulan hastadan yazılı onam alındığını ifade etmiştir.

Conflict of Interest: No conflict of interest was declared by the authors.

Çıkar Çatışması: Yazarlar çıkar çatışması bildirmemişlerdir.

Financial Disclosure: The authors declared that this study has received no financial support.
Finansal Destek: Yazarlar bu çalışma için finansal destek almadıklarını beyan etmişlerdir.

Published: 5/7/2019

Yayın Tarihi: 07.05.2019

Copyright © 2019 The Author(s)
Published by JOSAM

This is an open access article distributed under the terms of the Creative Commons Attribution-Non Commercial-NoDerivatives License 4.0 (CC BY-NC-ND 4.0) where it is permissible to download, share, remix, transform, and buildup the work provided it is properly cited. The work cannot be used commercially without permission from the journal.



Case presentation

Forty-one year old male patient applied to our clinic with complaints of muscle pain, fatigue and tea-colored urine. The patient had no comorbidities or surgical history. No pathological finding other than microscopic hematuria was observed in laboratory examinations. In contrast-enhanced whole abdomen tomography, on the other hand, a mass of 2 cm size was observed in bladder lateral wall (Figure 1). In urethroscopy, a solid lesion of about 2 cm size was found in right lateral wall of bladder. Except for this lesion, both ureter orifices, bladder neck and bladder mucosa excluding the area where mass was located appeared completely normal. Then, transurethral resection was performed under spinal anesthesia for the lesion observed in bladder. Catheter was removed on the third postoperative day and the patient was discharged without any problem. In microscopic examination of tissue specimens, a tumor development with poor cellularity extending in various directions as bundles and showing flow pattern (Figure 2). On the other hand, it was revealed that the lesion was composed of fine spindle cells with bipolar nuclei but had no mitosis and necrosis. However, adipose tissue foci and vascular structures were observed among cellular bundles. Besides, stromal myxoid changes were observed in background of some areas. Immunohistochemical analysis showed an extended and strong cytoplasmic expression of SMA (smooth muscle actin) stain applied to tissue (Figure 3). Based on all pathological data, case was diagnosed as bladder leiomyoma. The patient was taken to routine follow-up program and no recurrence was observed in follow-ups performed for two years.

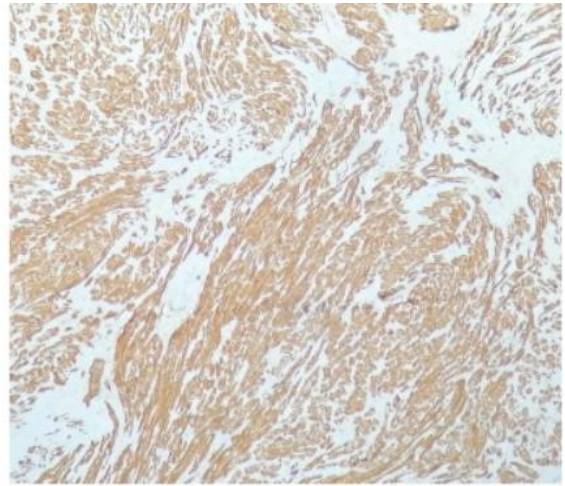


Figure 3: Immunohistochemical analyses of the bladder mass

Discussion

A detailed examination of the literature showed that many benign structures of bladder have been described such as inflammatory myofibroblastic tumor, postoperative spindle cell nodule, neurofibroma, schwannoma, leiomyoma and hemangioma [6]. However, most commonly observed benign mesenchymal tumors of these formations are leiomyomas [4]. Bladder leiomyoma was first described by Kretschmer et al. [7] in 1931. Nevertheless, etiology of leiomyomas has not been fully elucidated yet. Many factors such as infections, hormonal changes and chromosomal anomalies have been suspected in the etiology [4,8]. Leiomyomas could be found in all age groups. In women, they are more common in the third and fourth decade of the life [5]. Previous studies found that size of these benign lesions could vary enormously from millimeters to gigantic sizes of up to 30 cm [3,9]. Nature of these lesions in bladder could be of three types: endovesical, extravescical and intramural. Endovesical location is the most common form and is observed in 63-86% of the cases followed by extravescical form which is found in 11-30%. Intramural form, on the other hand, is least common one and constitutes 3-7% of all leiomyomas [9].

Clinical findings of bladder leiomyomas are closely associated with the location, size and nature of the lesion. The leiomyoma patients could present with hematuria, bacteriuria, frequently urinary system infection, flank pain and obstructive or irritative urinary symptoms. However, they can also be incidentally diagnosed [10,11]. Silva-Ramos et al. [12] performed a clinical study with 90 patients who had bladder leiomyoma and found that most frequent complaint of the patients was irritative urinary symptoms. Similarly, irritative urination was the most common complaint of the patients in another study by Jiang et al. [13]. Goluboff et al. [14], on the other hand, reported that obstructive symptoms were most common complaints of leiomyoma patients (49%). In the same study, 11% of the patients had hematuria and 38% had irritative urinary symptoms while 19% of them had incidental diagnosis.

Ultrasonography (USG), intravenous pyelography (IVP), computed tomography (CT) and magnetic resonance imaging (MRI) are major methods used for radiological evaluation of bladder leiomyomas. Leiomyoma is usually observed as homogeneous, hypoechoic and clearly bordered in USG and has small amount of hemorrhage in Doppler USG [16].

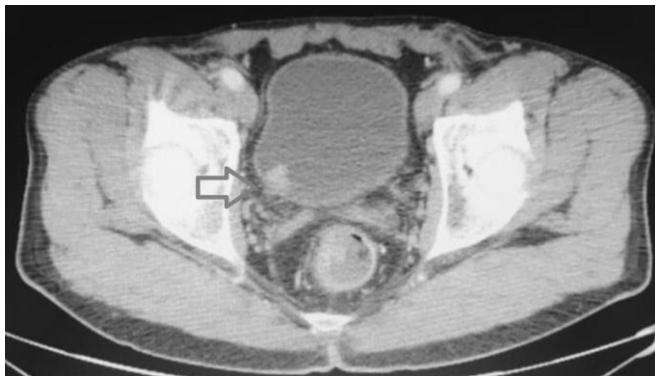

Figure 1: Computed tomography scan showing heterogeneously enhancing bladder mass (arrow)

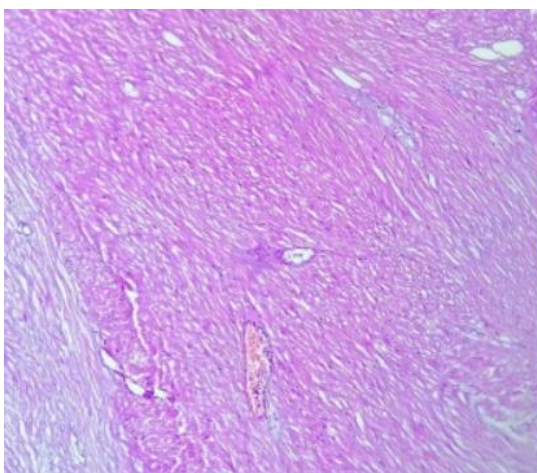


Figure 2: Histopathological examination of the bladder mass

Intravesical or submucosal leiomyomas have a filling defect or bladder contour irregularity in IVP [17]. In CT, bladder leiomyoma generally has an appearance of round hypodense mass with clear borders while centripetal homogeneous contrasting is observed in contrast-enhanced CT. It is observed as a mass with smooth surface and low signal intensity. Use of MRI is suggested more frequently for the diagnosis because of its better tissue contrast and higher resolution [18]. In bimanual examination, on the other hand, it is a palpable, smooth surfaced mobile lesion with elastic structure. Cystoscopy and tissue examination are absolutely necessary for the diagnosis [14]. Leiomyomas are grossly clear-bordered, thin-capsuled solid masses with yellow colored sectional surface. Microscopically, leiomyoma is made of intersecting smooth muscle fascicles surrounding vascular structures lined with normal endothelium and arranged as bundles extending in various directions. No mitotic activity, hemorrhage or necrosis foci are observed in these lesions. Immunohistochemically, they have positive staining with SMA (smooth muscle actin), MSA (muscle-specific actin), desmin, h-caldesmon and vimentin. In general, they are negative with keratins and EMA (epithelial membrane antigens). Four major pathologies are important in differential diagnosis of leiomyoma. These are leiomyosarcoma, solitary fibrous tumor, postoperative spindle cell nodule and inflammatory myofibroblastic tumor. Detrusor muscle invasion is the most significant factor in differential diagnosis with leiomyosarcoma. However, findings such as presence of nuclear atypia, high level of mitosis and tumor necrosis also help for the differential diagnosis. Postoperative spindle cell nodules generally appear a few weeks after the transurethral resections. Histologically, they resemble sarcomas because of cellularity and high number of mitosis. Although spindle cells are considered to originate from mesenchymal cells, histochemically they are positively stained with LMWCK (low molecular weight cytokeratin), vimentin, actin and desmin, but not with EMA. Inflammatory myofibroblastic tumors (inflammatory pseudotumors) are usually observed as polypoid masses in bladder during childhood. Histologically, they are diagnosed with the presence of spindle cells on myxoid and inflammatory background. Immunohistochemically, they are LMWCK negative. Solitary fibrous tumors are distinguished from leiomyomas with their cellularity and mitosis number, and histochemically with the presence of CD34, EMA and bcl-2 expressions [18-19].

Treatment modalities vary based on size, location and character of the lesion. Transurethral resection and fulguration are used in clinical practice as extremely minimally invasive treatment modality for small sized lesions which could be identified endoscopically. On the other hand, previous studies showed that repeating surgical interventions could be needed as secondary to incomplete resection in 18% of endovesical leiomyomas resected by transurethral method [20]. Especially for leiomyomas of intramural or extravesical nature which may have large sizes, open, laparoscopic or robotic mass enucleation and partial or total cystectomy are among the treatment modalities [4,20].

In conclusion, it is extremely important to perform cystoscopic examination for patients applying with hematuria

and to include benign lesions of bladder such as leiomyomas, though they are rare, in their differential diagnoses.

References

1. Tarhan H, Divrik RT, Koca O, Altok M, Zorlu F. Bladder Leiomyoma: Two Cases. *Turkiye Klinikleri J Urology*. 2010;1(3):91-4.
2. Dodia B, Mahajan A, Amlani D, et al. Leiomyoma of Urinary Bladder in Middle-Aged Female. *J Obstet Gynaecol India*. 2017;67:147-9.
3. Gok A. Transurethral resection of a large urinary bladder leiomyoma: a rare case report. *Urol J*. 2017;14:4052-4.
4. Çakmak Ö, Vermişli S, Yalbuzağ ON, Kahraman DS. Erkeklerde Mesane Leiomyomu: İki Olgu Sunumu ve Literatür Derlemesi. *Bulletin of Urooncology*. 2016;15:167-9.
5. Akay HÖ, Akay AF, Büyükbayram H, Şahin H. Bladder Leiomyoma: Case Report. *Dicle Tıp Dergisi*. 2004;31(2):62-4.
6. Yücel C, Keskin MZ. Rare Benign and Uncertain Malignant Potential Tumors of Bladder: Review of the Literature. *Bulletin of Urooncology*. 2017;16:123-6.
7. Kretschmer JL. Leiomyoma of the bladder with a report of a case and a review of the literature. *J Urol*. 1931;26:57.
8. Kim IY, Sadeghi F, Slawin KM. Dyspareunia: an unusual presentation of leiomyoma of the bladder. *Rev Urol*. 2001;3:152-4.
9. Singh O, Gupta SS, Hastir A. Laparoscopic enucleation of leiomyoma of the urinary bladder: a case report and review of the literature. *Urol J*. 2011;8:155-8.
10. Li A, Zhang P, Zhang M, et al. Transurethral Enucleation of Bladder Leiomyoma: A Series of Six Cases and Review of the Literature. *Urol Int*. 2019;102(1):102-8.
11. Haddad RG, Murshidi MM, Abu Shahin N, et al. Leiomyoma of urinary bladder presenting with febrile urinary tract infection: a case report. *Int J Surg Case Rep*. 2016;27:180-2.
12. Silva-Ramos M, Masso P, Versos R, Soares J, Pimenta A. Leiomyoma of the bladder. Analysis of a collection of 90 cases. *Actas Urol Esp*. 2003;27:581-6.
13. Jiang XZ, Xu C, Zhang NZ, et al. Influence of clinical characteristics and tumor size on symptoms of bladder leiomyoma: A pooled analysis of 61 cases. *Chin Med J (Engl)*. 2012;125:2436-9.
14. Goluboff ET, O'Toole K, Sawczuk IS. Leiomyoma of bladder: report of case and review of literature. *Urology*. 1994;43(2):238-41.
15. Park JW, Jeong BC, Seo SI, et al. Leiomyoma of the urinary bladder: a series of nine cases and review of the literature. *Urology*. 2010;76:1425-9.
16. Wu S. Imaging findings of atypical leiomyoma of the urinary bladder simulating bladder cancer: a case report and literature review. *Med Ultrason*. 2013;15:161-13.
17. Blasco Casares FJ, Sacristán Sanfelipe J, Ibarz Servio L, Batalla Cadira JL, Ruiz Marcellán FJ. [Characteristics of bladder leiomyoma in our setting]. *Arch Esp Urol*. 1995;48:987-90.
18. Chen M, Lipson SA, Hricak H. MR imaging evaluation of benign mesenchymal tumors of the urinary bladder. *AJR Am J Roentgenol*. 1997;168:399-403.
19. Goldman HB, MacAhran SE, MacLennan GT. Leiomyoma of the urethra and bladder. *J Urol*. 2007;177(5):1890.
20. Chen CC, Huang CH, Chu CH, et al. Leiomyoma of the urinary bladder: a case report. *Kaohsiung J Med Sci*. 2003;19:141-5.

The National Library of Medicine (NLM) citation style guide is used in this paper.

Suggested citation: Patrias K. Citing medicine: the NLM style guide for authors, editors, and publishers [Internet]. 2nd ed. Wendling DL, technical editor. Bethesda (MD): National Library of Medicine (US); 2007-[updated 2015 Oct 2; cited Year Month Day]. Available from: <http://www.nlm.nih.gov/citingmedicine>