

# Critical stab injury due to anatomical variation caused by retroperitoneal lipoblastoma: A case report

## Retroperitoneal lipoblastomanın neden olduğu anatomik varyasyona bağlı kritik bıçakla yaralanma: Olgu sunumu

Mehmet Gündüz<sup>1</sup>, Ahmet Yalçın<sup>1</sup>, Erdem Karadeniz<sup>2</sup>

<sup>1</sup> Department of Radiology, Faculty of Medicine, Erzincan Binali Yıldırım University, Erzincan, Turkey

<sup>2</sup> Department of General Surgery, Faculty of Medicine, Ataturk University, Erzurum, Turkey

ORCID ID of the author(s)

MG: 0000-0002-8934-5499

AY: 0000-0002-9708-0988

EK: 0000-0001-6319-1754

### Abstract

Lipoblastoma and lipoblastomatosis are rare soft tissue neoplasms that are derived from fetal adipose tissue and that are seen in infants and young children. They transform into mature lipomas as the patients age. We present a 23 years old male patient stabbed from left abdominal flank and had a lipoid lesion on the right side of retroperitoneum. Due to malposition of intraabdominal organs in the stabbing site, patient had various vascular and serosal injuries as well as intestinal perforations.

**Keywords:** Lipoblastoma, Stab wound, Computed tomography

### Öz

Lipoblastoma ve lipoblastomatozis, fetal yağ dokudan köken alan nadir yumuşak doku neoplazileri olup süt çocuklarında ve küçük çocuklarda görülür. Hasta yaşı ilerledikçe matür lipomlara dönüşürler. Retroperiton sağ yarısında lipoid lezyona sahip karın sol yandan bıçaklanan 23 yaşındaki erkek hastayı sunduk. Bıçaklanma düzeyindeki intraabdominal organların malpozisyonu nedeni ile hastada, vasküler ve serozal yaralanmaların yanı sıra intestinal perforasyon mevcut idi.

**Anahtar kelimeler:** Lipoblastoma, Delici kesici alet yarası, Bilgisayarlı tomografi

### Introduction

Retroperitoneal fat containing lesions represent wide spectrum of entities. Lipomas are frequently seen as an intraabdominal mass however, if the origin is retroperitoneum, lipoma can hardly be the diagnosis [1,2]. List of differential diagnosis is reduced when pediatric population is considered. The condition of abdominal wall muscles can give clue about the mass as it has been shown that, in rare diseases, abdominal wall atrophy is secondary to fetal abdominal distention [3]. Lipoblastoma and lipoblastomatosis are rare soft tissue neoplasms that are derived from fetal adipose tissue and that seen in infants and young children [1]. We present a case who is 23 years old male stabbed from left abdominal flank and had a lipoid lesion on the right side of retroperitoneum. Due to malposition of intraabdominal organs in the stabbing site, patient had various vascular and serosal injuries as well as intestinal perforations.

### Case presentation

A 23 years old male was admitted to emergency room with stab wound. He had no history of previous surgery. Perinatal and childhood history was uneventful. Physical examination revealed left flank stab wound with minimal leakage of blood and abdominal distention. He had a body temperature of 37.6 °C, blood pressure of 100/70 mmHg, and heart rate of 110 beats per minute. Laboratory test results showed decreased hemoglobin levels (10.3 g/dL, range: 12.9–18.1) as well as red blood cell count ( $3.80 \times 10^6$  /uL, range: 4.06–6.13).

Abdominal ultrasonography was performed to investigate the extent of the injury. Sonographic result revealed intra-abdominal, peri-intestinal fluid collection with mildly increased wall thickness of left sided intestinal loops. Furthermore, there was a large echogenic mass with obscured borders that was located in the right upper and lower quadrant. Abdominal computed tomography (CT) examination was performed to solve the ambiguity.

Corresponding author / Sorumlu yazar:

Mehmet Gündüz

Address / Adres: Barbaros Mah. 482. Sok. No:39,  
D: 5, Merkez, Erzincan, Türkiye  
e-Mail: mtgndz@hotmail.com

Informed Consent: The author stated that the written consent was obtained from the patient presented in the study.

Hasta Onamı: Yazar çalışmada sunulan hastadan yazılı onam alındığını ifade etmiştir.

Conflict of Interest: No conflict of interest was declared by the authors.

Çıkar Çatışması: Yazarlar çıkar çatışması bildirmemişlerdir.

Financial Disclosure: The authors declared that this study has received no financial support.

Finansal Destek: Yazarlar bu çalışma için finansal destek almadıklarını beyan etmişlerdir.

Published: 4/11/2019

Yayın Tarihi: 11.04.2019

Copyright © 2019 The Author(s)

Published by JOSAM

This is an open access article distributed under the terms of the Creative Commons Attribution-Non Commercial-NoDerivatives License 4.0 (CC BY-NC-ND 4.0) where it is permissible to download, share, remix, transform, and buildup the work provided it is properly cited. The work cannot be used commercially without permission from the journal.



CT images showed a mass with fat density which filled the right side of the abdomen (Figure 1A). There were no any intestinal or colonic loops on the lesion side. Atrophy of the abdominal wall muscles and septa in the mass were also detected (Figure 1B). Imaging findings on the left side were concordant with sonographic results (Figure 1C).

Patient was immediately prepared for laparotomy. On the right side, a bulky retroperitoneal mass composed of fat was observed (Figure 2A). The whole mass was extracted (Figure 2C) and sent for histopathologic examination. Result was consistent with mature encapsulated lipoma. On the left side, at the level of the stab wound entry, six distinct intestinal perforation sites along with injured mesentery were detected (Figure 2B). Resection and anastomosis were performed. Additionally, various serosal injuries involving the caecum, ascending and descending colon were observed. Bleeding from small mesenteric vessels was also controlled. Postoperative course of the patient was uneventful. The written consent was obtained from the patient presented in this study.

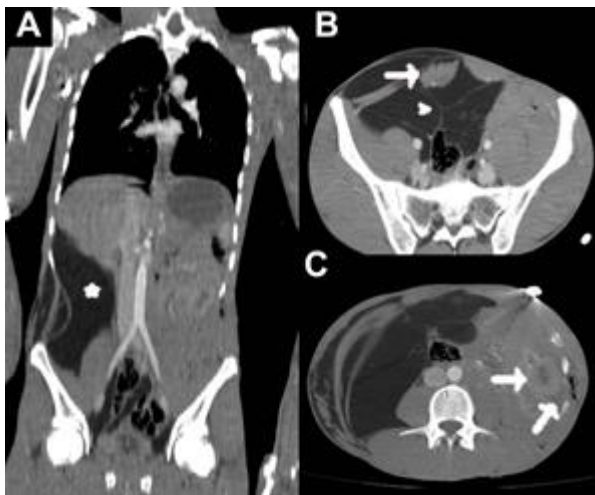


Figure 1: Coronal CT image (A) shows a fat density mass on the right side (asterisk) with all intestinal and colonic loops are seen on the left of abdomen. Axial image from pelvic level (B) shows right sided atrophy of the abdominal wall muscles (arrow) and septa within the lipoid mass (arrowhead). At the level of stab wound, axial image (C) shows increased wall thickness of the intestinal loops along with peri-intestinal fluid collection (arrows).

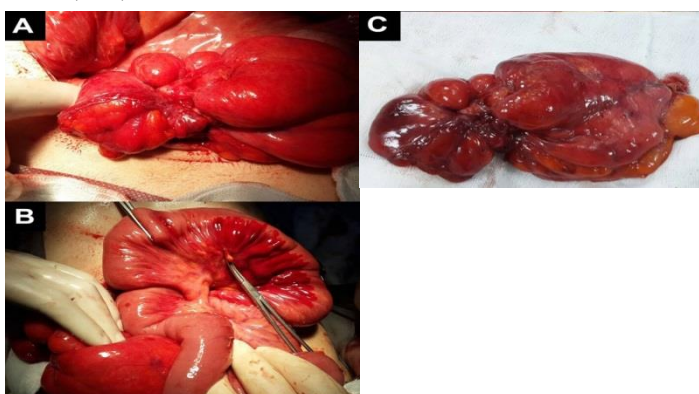


Figure 2: Photos taken during laparotomy. Macroscopic view of the mass before (A) and after resection (C). One of injured intestinal loop along with its mesentery (B).

## Discussion

In this paper, we demonstrated a case of intestinal malposition due to an intraabdominal mass and critical damage from stabbing due to presence of such anatomical variation. In our case, many bowel loops were injured due to stabbing. Even the caecum, which should have been localized on the right side of the abdomen, was injured. This is unlikely to be happened in a normal individual who had caecum at the right and stabbed from

the left. Our patient had right sided lipoblastoma, which displaced the entire bowel including caecum and made the left sided stabbing to cause more damage than expected.

Penetrating trauma to the back or flank less likely poses a significant injury compared to anterior abdominal wounds [4]. However, these injuries can be challenging by means of imaging techniques and clinical evaluation. Focused abdominal sonographic examination for trauma as well as physical examination is unreliable in retroperitoneal imaging [4]. For patients who have sustained a penetrating injury to the abdomen, treatment choice is always non-operative follow-up unless patient is unevaluable, presence of hemodynamic instability, peritonitis, or evisceration. Patients who represent those findings should undergo immediate exploration whereas imaging should be performed to remaining. If the injury mechanism is an abdominal gunshot wound, situation can be easily delineated by CT because trajectory of the foreign body and crossings of this trajectory to intraabdominal structures can be determined. However, the lack of soft tissue disruption makes visualizing the tract of the stab wound and any associated injuries difficult and renders the role of CT imaging less potent [5]. On the other hand, CT imaging is useful for investigating the presence of other comorbid situations and accompanying anatomical variations as in our case.

Lipoblastomas commonly presents with painless mass in asymptomatic children. However, older patients have a more mature lipoblastoma in which immature fat cells are replaced by mature ones [1]. Furthermore, circumscribed form of lipoblastoma mimics the typical lipoma with its well-defined borders. Lipoblastomas differ from lipomas by having fibrous septa which retain as the patients ages [1]. Although histopathologic examination was consistent with lipoma in our case, imaging and histopathologic characteristics such as retroperitoneal location, retained fibrous septa, atrophy of the abdominal wall muscles and presence of external capsule indicate that this lipoma was the transformed form of lipoblastoma.

Lipoblastoma is a rare retroperitoneal lipid mass and that transforms into lipoma in adulthood. CT imaging is helpful in the diagnosis. Adjacent structures should be examined carefully as they provide useful information about the origin and the extent of the mass.

## References

1. Craig WD, Fanburg-Smith JC, Henry LR, Guerrero R, Barton JH. Fat-containing lesions of the retroperitoneum: radiologic-pathologic correlation. *Radiographics*. 2009;29:261–90.
2. Genchellac H, Demir MK, Ozdemir H, Unlu E, Temizoz O. Computed tomographic and magnetic resonance imaging findings of asymptomatic intra-abdominal gastrointestinal system lipomas. *J Comput Assist Tomogr*. 2008;32:841–7.
3. Moerman P, Frys JP, Goddeeris P, Lauweryns JM. Pathogenesis of the prune-belly syndrome: a functional urethral obstruction caused by prostatic hypoplasia. *Pediatrics*. 1984;73:470–5.
4. Biffl WL, Leppaniemi A. Management guidelines for penetrating abdominal trauma. *World J Surg*. 2015;39:1373–80.
5. Inaba K, Okoye OT, Rosenheck R, Melo N, Branco BC, Talving P, et al. Prospective evaluation of the role of computed tomography in the assessment of abdominal stab wounds. *JAMA Surg*. 2013;148:810–6.

The National Library of Medicine (NLM) citation style guide is used in this paper. Suggested citation: Patrias K. Citing medicine: the NLM style guide for authors, editors, and publishers [Internet]. 2nd ed. Wendling DL, technical editor. Bethesda (MD): National Library of Medicine (US); 2007-[updated 2015 Oct 2; cited Year Month Day]. Available from: <http://www.nlm.nih.gov/citingmedicine>