

Long-term results of laparoscopic Heller myotomy with Dor-fundoplication in surgical treatment of achalasia: A single-center experience

Ali Surmelioglu¹, Dogukan Akkus²

¹ Department of Gastrointestinal Surgery, Haydarpasa Numune Training and Research Hospital, University of Health Sciences, Istanbul, Turkey

² Department of General Surgery, Haydarpasa Numune Training and Research Hospital, University of Health Sciences, Istanbul, Turkey

ORCID ID of the author(s)

AS: 0000-0002-7697-0930
DA: 0000-0003-2259-6944

Corresponding Author

Ali Surmelioglu
Department of Gastrointestinal Surgery, Haydarpasa Numune Training and Research Hospital, University of Health Sciences, Tibbiye cad. No:23 34668 Uskudar, Istanbul, Turkey
E-mail: surmeliiali@yahoo.com

Ethics Committee Approval

Haydarpasa Numune Training and Research Hospital Clinical Research Ethics Committee (HNEAH-KAEK 2021/212).

All procedures in this study involving human participants were performed in accordance with the 1964 Helsinki Declaration and its later amendments.

Conflict of Interest

No conflict of interest was declared by the authors.

Financial Disclosure

The authors declared that this study has received no financial support.

Published

2021 September 22

Copyright © 2021 The Author(s)

Published by JOSAM

This is an open access article distributed under the terms of the Creative Commons Attribution-NonCommercial-NoDerivatives License 4.0 (CC BY-NC-ND 4.0) where it is permissible to download, share, remix, transform, and buildup the work provided it is properly cited. The work cannot be used commercially without permission from the journal.



Abstract

Background/Aim: Laparoscopic Heller myotomy with Dor fundoplication (LHD) is a widely used surgical method in achalasia treatment. However, it has not been well studied in terms of symptomatic relief effect and anti-reflux success in the long term. This study aimed to investigate the long-term success of LHD on symptom relief and acid reflux control.

Methods: Patients who underwent LHD between February 2011 and June 2020 were included in this retrospective cohort study. Patients' demographics, post-operative follow-up outcomes and esophagitis signs on endoscopy were retrieved from the institutional database. Eckardt scores of all study patients were calculated. Those with insufficient follow-up data were excluded. Disease free rates were calculated using the Kaplan-Meier analysis.

Results: A total of 24 patients, 11 males and 13 females, were included. The mean age of all patients was 47.9 (11.3) years. The median follow-up time was 71.0 (12.0-117.0) months. Cumulative symptomatic relief (Eckardt ≤ 3) rate of LHD was 87.5% (21/24). Kaplan-Meier analysis showed that the time-dependent probability of Eckardt score being ≤ 3 at 3 and 5 years after the surgery were 100% and 94.7%, respectively. The mean expected survival time with Eckardt score ≤ 3 was 102.5 (95% CI: 87.6-117.3) months. The post-LHD esophagitis rate was 20.8% (5/24). The probability of no reflux esophagitis at 3 and 5 years after the surgery were 95.0% and 89.4%, respectively. The mean expected esophagitis-free survival was 94.2 (95% CI: 80.6-107.7) months.

Conclusion: LHD seems successful and safe in terms of long-term symptomatic relief and acid reflux control in the surgical treatment of achalasia.

Keywords: Achalasia, Laparoscopic Heller-myotomy with Dor-fundoplication, Long-term results, Esophagitis

Introduction

Achalasia is a rare primary esophageal motility disorder characterized by the lack of peristaltic activity and partial or total loss of lower esophageal sphincter (LES) relaxation in response to swallowing [1]. Selective degeneration of inhibitory neurons in the myenteric plexus responsible for esophageal peristalsis and LES relaxation is the culprit mechanism. Since a functional obstruction occurs in gastroesophageal junction, esophageal dilatation is seen. The most common complaints include dysphagia, regurgitation, chest pain and weight loss. Diagnosis is made by esophagogastroduodenoscopy, barium esophagogram and manometry [2].

Treatment protocols are not curative, and the primary goal is to relieve symptoms and help foods pass through esophagus by decreasing LES pressure. Non-surgical approaches include pharmacological agents, endoscopic botulinum toxin injection, pneumatic dilatation and peroral endoscopic myotomy (POEM). The surgical treatment methods are Heller myotomy and esophagectomy [3].

The gold standard surgical treatment is laparoscopic Heller myotomy (LHM) with added partial anti-reflux procedures. Although some centers suggest a myotomy of 3 cm on the gastric side, performing a myotomy of at least 6 and 2.5 cm on the esophageal and gastric sides, respectively, is a well-accepted approach [2, 4]. The partial anti-reflux procedure to be preferred is not clear. The most used partial fundoplication methods include Toupet (posterior, 270 degrees) and Dor (anterior, 180 degrees). In Toupet, the edges of the myotomy are kept separate, the abdominal esophagus is totally mobilized and gastrica breves are totally cut to obtain a mobile fundus [4]. In Dor fundoplication, however, the mucosa exposed following the myotomy is covered by the fundus and since total mobilization of abdominal esophagus is not necessary, posterior dissection is useless. Plus, gastrica breves are not necessarily cut given no need of extended fundal mobilization [5]. Toupet versus Dor fundoplication procedures were compared in randomized controlled studies with no significant differences in terms of post-operative reflux [6-8]. These results suggest that the fundoplication method of choice is at the surgeon's discretion. We prefer LHM with Dor fundoplication (LHD) in our center. In this context, we designed this study to report our experiences in terms of intra and post-operative complications, long-term symptomatic relief and success of acid reflux control.

Materials and methods

Patients with achalasia who presented with LHD between February 2011 and June 2020 were included in this retrospective cohort study. Diagnoses of all included patients were made based on esophagogastroduodenoscopy, esophagogram and esophageal manometry findings. The patients' demographics, pre- and post-operative weights, disease durations, esophageal dilatation size, operation notes, intra- and post-operative complications, and duration of post-operative follow-up and endoscopic findings were retrieved from the institutional database. Eckardt scores were calculated. Those with insufficient follow-up data were excluded. The study was conducted in accordance with the Helsinki Declaration and

approved by Haydarpasa Numune Training and Research Hospital Clinical Research Ethics Committee (HNEAH-KAEK 2021/212).

Preoperative esophagograms were obtained with barium until 2018. Since it was not available in our country from that year on, water-soluble opaque agents were used. Japanese Esophageal Society (JES) classification was used to determine the dilatation degree in the esophagogram [9]. Accordingly, the patients were divided into three, as those with grade I (maximal esophageal diameter of less than 3.5 cm), grade II (between 3.5 and 6 cm) and grade III (more than 6 cm) dilation. Manometry was performed with the conventional method (5-channel catheter).

Eckardt score is a widely used and well-established grading system in the assessment of symptom and treatment effectiveness [10]. Four major symptoms are inquired (dysphagia, regurgitation, chest pain and weight loss) and graded between 0-4. A total score of equal to or lower than 3 is considered successful in the evaluation of the treatment. Those with post-operative Eckardt scores of >3 were asked when their first complaint began and the duration between surgery and the beginning of complaints was considered successful post-surgical time. Time to detection of post-operative esophagitis via endoscopy was also noted. The Los Angeles classification was used to determine severity of esophagitis in our center [11]. Los Angeles grade A or higher (B, C, D) was defined as endoscopic esophagitis.

Statistical Analysis

Data analysis was performed using IBM SPSS Statistics version 25.0 software (IBM Corporation, Armonk, NY, US). Categorical data were expressed as numbers (n) and percentage (%) while quantitative data were given as mean (SD) and median (min-max). The clinical success (Eckardt score ≤ 3) and esophagitis-free survival rates were displayed by the Kaplan-Meier survival curves. Cumulative survival rates for 3 and 5 years, and the mean expected duration of life without reflux were also calculated at a 95% confidence interval.

Results

A total of twenty-four patients, 11 males (48.8%) and 13 females (51.2%), had undergone LHD between February 2011-June 2020. The mean age of the patients was 47.9 (11.3) years. Half of patients had undergone pneumatic dilatation before surgery. Preoperative degree of dilatations were grade I in 3 (12.5%), grade II in 15 (62.5%) and grade III in 6 (25%) patients. Table 1 shows the patients' characteristics.

Table 1: Baseline characteristics of patients

	n=24
Age (years)	47.9 (11.3)
Gender	
Male	11 (45.8%)
Female	13 (54.2%)
Pre-op BMI (kg/m ²)	23.0 (5.6)
Duration of disease (months)	48.0 (12.0-360.0)
Prior history of pneumatic dilation	12 (50.0%)
Maximum esophageal diameter (cm)	5.12 (1.04)
Pre-op ECKARDT score	8.5 (5.0-12.0)
Degree of dilation	
Grade I (<3.5 cm)	3 (12.5%)
Grade II (≥ 3.5 cm <6.0 cm)	15 (62.5%)
Grade III (≥ 6.0 cm)	6 (25.0%)

Three trocars of 5 mm and 2 trocars of 12 mm (5 ports in total) were used in LHD. The median operation time was 150

(120-210) minutes. Mucosal injury occurred in 2 patients (8.3%) and were repaired. One (4.2%) patient had a bleeding of 300 cc and 1 (4.2%) patient had vagal injury. Operation was switched to open surgery in 1 patient owing to adhesions secondary to previous intra-abdominal surgery. The median duration of hospital stay was 4 (3-5) days. Among post-operative complications, 1 (4.2%) patient had atelectasis and 1 (4.2%) had wound infection (open surgery case). No perforation or delayed peritonitis was noted in the post-operative period. The median follow-up time was 71 (12-117) months (Table 2).

Table 2: Other clinical findings

Parameter	Value
Operative time (min)	150.0 (120.0-210.0)
Blood loss (ml)	0.0 (0.0-300.0)
Intraoperative complications	4 (16.7%)
Esophageal/gastric mucosal injury	2 (8.3%)
Blood loss > 200 ml	1 (4.2%)
Vagus nerve injury	1 (4.2%)
Length of hospital stay (days)	4.0 (3.0-5.0)
Postoperative complications	2 (8.3%)
Atelectasis	1 (4.2%)
Surgical site infections	1 (4.2%)
Post-op BMI (kg/m ²)	26.4 (4.5)
Post-op Eckardt score	2.0 (0.0-5.0)
Post-op Eckardt score >3	3 (12.5%)
Post-op esophagitis	5 (20.8%)
Follow-up time (months)	71.0 (12.0-117.0)

LHD resulted in symptomatic relief in 21 of 24 patients (87.5%) (Eckardt ≤ 3). We had 3 patients with a post-operative Eckardt score of more than 3 (12.5%). Kaplan-Meier analysis showed that the time-dependent probability of Eckardt score ≤ 3 at 3 and 5 years after surgery were 100% and 94.7%, respectively (Figure 1). The mean expected survival time with Eckardt score ≤ 3 was 102.5 (95% CI: 87.6 – 117.3) months. Five (20.8%) of 24 patients had post-operative esophagitis. Severity was Los Angeles grade A in 4 patients and B in one. Figure 2 shows the Kaplan-Meier esophagitis-free survival curve. Accordingly, the probability of no reflux esophagitis at 3 and 5 years after the surgery were 95.0% and 89.4%, respectively. The mean expected esophagitis-free survival time was 94.2 (95% CI: 80.6 – 107.7) months.

Figure 1: Kaplan-Meier analysis on time-dependent probability of patients with Eckardt score ≤ 3

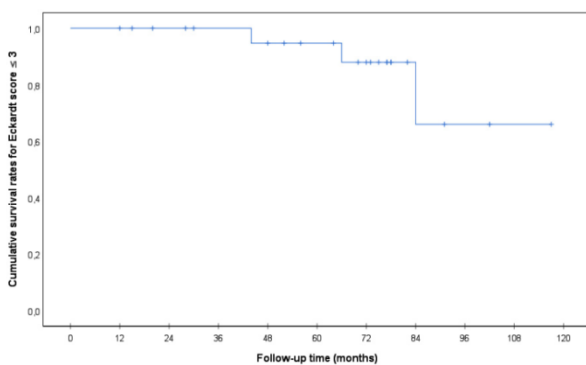
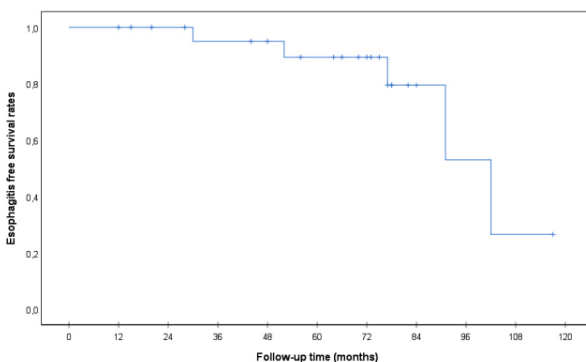


Figure 2: Kaplan-Meier analysis on esophagitis-free survival



Discussion

Dr. Heller first performed the transabdominal myotomy in the gastric cardia and esophagus approximately 100 years ago [12]. The myotomy technique was modified over the years. The first LHM was performed by Shimi et al. [13] in 1991. Post-operative reflux rates were reported as high as 60% when Heller myotomy was performed alone; however, thanks to the addition of Dor fundoplication, this rate decreased down to 17% [14]. Eventually, the gold standard treatment was established as Heller myotomy plus partial anti-reflux procedures. Since it does not necessitate posterior dissection and covers the exposed esophageal mucosa, we prefer the Dor fundoplication (anterior, 180 degrees).

LHM has favorable results. Zaninotto et al. [15] reported a success rate of 90% in their study with a median follow-up duration of 2.5 years covering 407 patients. Schlottmann et al. [16] noted a 87% success rate (Eckardt ≤ 3) in a study including 147 patients with a median follow-up duration of 22 months. In their study on 896 patients with a median follow-up duration of 5.2 years, Costantini et al. [17] reported that LHM resulted in esophageal symptom control in 84.3% of patients over 10 years. Fukushima et al. reported the success rates of LHM as 95.3%, 86.5% and 73.5% over 1, 5 and 10 years, respectively, in their study on 530 patients with a median follow-up duration of 50.5 months [18]. In our study with 70.1 months of median follow-up duration, which included 24 patients, the cumulative symptom relief rate of LHM (Eckardt ≤ 3) was %87.5. Kaplan-Meier analysis showed that the probability of Eckardt score ≤ 3 over 3 and 5 years were 100% and 94.7%, respectively. Mean expected survival time with Eckardt score ≤ 3 was 102.5 (95% CI: 87.6 – 117.3) months. In light of these data, it can be concluded that LHM is still one of the most effective methods in long-term achalasia treatment.

We had 3 patients with a post-operative Eckardt score >3 . One of these underwent pneumatic dilatation because of severe dysphagia. Two (one of them who underwent pneumatic dilatation) of these 3 patients were consistent with JES grade I (<3.5 cm), while the other one was consistent with JES grade III. Fukushima et al. reported that JES grade I patients had the highest risk of recurrent dysphagia [18]. High-resolution manometry (HRM) has recently been used in the diagnosis of achalasia. Achalasia was divided into three in the Chicago classification based on HRM findings for a better treatment algorithm, as type I, II and III [19]. Type III is also named as spastic achalasia. Studies suggest that the risk of recurrent dysphagia following LHM is the highest in type III patients. Besides, the vast majority of those with type III disease correspond to JES grade I (<3.5 cm) [18]. Costantini et al. [17] reported that symptomatic recurrences mostly occurred in type III disease. Of the 3 patients with Eckardt score >3 following LHD in our study, 2 were in the JES grade I group, suggesting that these patients had type III spastic achalasia. Although similar results were recently reported in the study comparing the newly popular POEM versus LHM in terms of symptom control, in Type III spastic achalasia, POEM is preferred over LHM since it yields a longer myotomy line [20]. We would probably recommend POEM if we have had the chance to know whether these two cases to had type III disease or not. However, it should

be kept in mind that POEM carries a risk of reflux esophagitis in 50% of cases [2]. Nowadays, POEM seems to be preferable in recurrent cases and in the primary treatment of type III achalasia.

Nearly all centers add partial anti-reflux procedures to LHM to better control the reflux. Rawling et al. [6] conducted a multicenter randomized controlled study to investigate which partial fundoplication should be performed. They noted no difference between Dor and Toupet regarding acid reflux symptoms. These data were confirmed by two additional randomized controlled studies and two meta-analyses [7, 8, 21, 22]. Considering these data, which fundoplication method to be used was left to the surgeon's preference. We have been using the Dor fundoplication. Post-LHD reflux esophagitis occurrence rates vary between 6-35% [18, 23-25]. This wide range of recurrence rates may be due to the different times elapsed until post-operative endoscopy and follow-up durations. Fukushima et al. [18] reported the rate of post-LHD reflux esophagitis as 34.4% in those with a follow-up duration of more than 10 years. In our study with a median of 71 month-follow-up time, the post-LHD esophagitis rate was 20.8%. Although this finding seems relatively high, 4 of 5 patients had mild (Los Angeles grade A) and 1 had moderate (Los Angeles grade B) esophagitis. No one had Los Angeles grade C or D disease. The Kaplan-Meier analysis predicted an esophagitis-free survival of 3 and 5 years as 95% and 89.4%, respectively. Besides, the mean expected esophagitis-free survival was 94.2 (95% CI: 80.6 – 107.7) months. All these data suggest that LHD is successful in long-term acid reflux control.

Limitations

Limitations of the study include its retrospective design, lack of HRM, confirmation of reflux esophagitis findings without 24 h ambulatory pH monitoring and low sample size. Its non-comparative nature is another limitation. Although self-reporting of symptoms may yield a potential bias regarding objectivity, we used the Eckardt scoring system, which is widely used in the symptom assessment of achalasia.

Conclusion

LHD seems successful and safe in terms of symptomatic relief and acid reflux control in the surgical treatment of achalasia. However, determining the subtypes of achalasia via HRM before the treatment may possibly lead to more successful results. Further studies with a higher patient number and longer follow-up period are needed to verify our findings.

References

- Schlottmann F, Neto RML, Herbella FAM, Patti MG. Esophageal achalasia: Pathophysiology, clinical presentation, and diagnostic evaluation. *Am Surg*. 2018;4:84:467–4.
- Schlottmann F, Patti MG. Esophageal achalasia: current diagnosis and treatment. *Expert Rev Gastroenterol Hepatol*. 2018;12:711–21. doi: 10.1080/17474124.2018.1481748.
- Zaninotto G, Bennett C, Boeckxstaens G, Costantini M, Ferguson MK, Pandolfino JE, et al. The 2018 ISDE achalasia guidelines. *Dis Esophagus*. 2018;31. doi: 10.1093/dote/doy071.
- Inaba CS, Wright AS. Laparoscopic Heller myotomy and Toupet fundoplication for achalasia. *J Laparoendosc Adv Surg Tech*. 2020;30. doi:10.1089/lap.2020.0158
- Schlottmann F, Nurczyk K, Patti MG. Laparoscopic Heller Myotomy and Dor Fundoplication: How I Do It? *J Laparoendosc Adv Surg Tech A*. 2020 Jun;30(6):627–9. doi:10.1089/lap.2020.0157.
- Rawlings A, Soper NJ, Oelschlagel BK. Laparoscopic Dor versus Toupet fundoplication following Heller myotomy for achalasia: Results of a multicenter, prospective, randomized-controlled trial. *Surg Endosc*. 2012;26:18–26. doi: 10.1007/s00464-011-1822-y. Epub 2011 Jul 26.
- Kumagai K, Kjellin A, Tsai JA, Thorell A, Granqvist S, Lundell L, et al. Toupet versus Dor as a procedure to prevent reflux after cardiomyotomy for achalasia: Results of a randomised clinical trial. *Int J Surg*. 2014;12:673–80. doi: 10.1016/j.ijsu.2014.05.077. Epub 2014 Jun 2.
- Torres-Billalobos G, Coss-Adame E, Furuzawa-Carballeda J, Romero-Hernandez F, Blancas-Brena B, Torres-Landa S, et al. Dor vs Toupet fundoplication after laparoscopic Heller myotomy: Long-term randomized controlled trial evaluated by high-resolution manometry. *J Gastrointest Surg*. 2018;22:13–22. doi: 10.1007/s11605-017-3578-8. Epub 2017 Sep 18.
- Japan Esophageal Society. Descriptive rules for achalasia of the esophagus, June 2012: 4th edition. *Esophagus*. 2017;14:275–89. doi: 10.1007/s10388-017-0589-1

- Eckardt VF, Aignherr C, Bernhard G. Predictors of outcome in patients with achalasia treated by pneumatic dilation. *Gastroenterology*. 1992;103:1732–8. doi: 10.1016/0016-5085(92)91428-7.
- Lundell L, Dent J, Bennett J, Blum A, Armstrong D, Galmiche J, et al. Endoscopic assessment of oesophagitis: clinical and functional correlates and further validation of the Los Angeles classification. *Gut*. 1999;45:172–80. doi: 10.1136/gut.45.2.172.
- Heller E. Extramuköse cardioplastik beim chronischen kardiospasmus mit dilatation des oesophagus. *Mitt Grenzgeb Med Chir*. 1914;27:141–9.
- Shimi S, Nathanson LK, Cuschieri A. Laparoscopic cardiomyotomy for achalasia. *J R Coll Surg Edinb*. 1991;36(3):152–4.
- Patti MG, Pellegrini CA, Horgan S, Arcerito M, Omelanczuk P, Tamburini A, et al. Minimally invasive surgery for achalasia: an 8-year experience with 168 patients. *Ann Surg*. 1999;230(4):587–93. doi: 10.1097/00000658-199910000-00014.
- Zaninotto G, Costantini M, Rizzetto C, Zanatta L, Guirrolle E, Portale G, et al. Four hundred laparoscopic myotomies for esophageal achalasia: a single centre experience. *Ann Surg*. 2008;248(6):986–93. doi: 10.1097/SLA.0b013e3181907bdd.
- Schlottmann F, Andolfi C, Kavitt RT, Konda VJA, Patti MG. Multidisciplinary approach to esophageal achalasia: a single center experience. *J Laparoendosc Adv Surg Tech A*. 2017;27(4):358–62. doi: 10.1089/lap.2016.0594
- Costantini M, Salvador R, Capovilla G, Vallesse L, Costantini A, Nicoletti L, et al. A thousand and one laparoscopic heller myotomies for esophageal achalasia: a 25-year experience at a single tertiary center. *J Gastrointest Surg*. 2019;23:23–35. doi: 10.1007/s11605-018-3956-x
- Fukushima N, Masuda T, Yano F, Omura N, Tsuboi K, Hoshino M, et al. Over ten year outcomes of laparoscopic Heller myotomy with Dor fundoplication with achalasia: single center experience with annual endoscopic surveillance. *Surg Endosc*. 2020;Nov 13. doi: 10.1007/s00464-020-08148-5. Online ahead of print.
- Pandolfino JE, Ghosh SK, Rice J, Clarke JO, Kwiatek MA, Kahrilas PJ. Classifying esophageal motility by pressure topography characteristics: a study of 400 patients and 75 controls. *Am J Gastroenterol*. 2008;103(1):27–37. doi: 10.1111/j.1572-0241.2007.01532.x
- Kumbhari V, Tieu AH, Onimaru M, El Zein MH, Teitelbaum EN, Ujiki MB, et al. Peroral endoscopic myotomy (POEM) vs laparoscopic Heller myotomy (LHM) for the treatment of type III achalasia in 75 patients: a multicenter comparative study. *Endosc Int Open*. 2015;3(3):E195–201. doi: 10.1055/s-0034-1391668
- Aiolfi A, Tornese S, Bonitta G, Cavalli M, Rausa E, Micheletto G, et al. Dor versus Toupet fundoplication after laparoscopic Heller myotomy: Systematic review and Bayesian meta-analysis of randomized controlled trials. *Asian J Surg*. 2020;43:20–8. doi: 10.1016/j.asjsur.2019.03.019
- Siddaiah-Subramanya M, Yunus RM, Khan S, Memon B, Memon MA. Anterior Dor or posterior Toupet with Heller myotomy for achalasia cardia: A systematic review and meta-analysis. *World J Surg*. 2019;43:1563–70. doi: 10.1007/s00268-019-04945-9
- Boeckxstaens GE, Anness V, des Varannes SB, Chaussade S, Costantini M, Cuttitta A, et al. Pneumatic Dilation versus Laparoscopic Heller's Myotomy for Idiopathic Achalasia. *N Engl J Med*. 2011;364:1807–16. doi: 10.1056/NEJMoa1010502
- Campos G, Vittinghof E, Rabl C, Takata M, Gadenstätter M, Lin F, et al. Endoscopic and surgical treatments for achalasia: a systematic review and meta-analysis. *Ann Surg*. 2009;249:45–57. doi: 10.1097/SLA.0b013e31818e43ab
- Costantini A, Familiari P, Costantini M, Salvador R, Valmasoni M, Capovilla G, et al. Poem versus laparoscopic heller myotomy in the treatment of esophageal achalasia: a case control study from two high volume centers using the propensity score. *J Gastrointest Surg*. 2020;24:505–15. doi: 10.1007/s11605-019-04465-w.

This paper has been checked for language accuracy by JOSAM editors.
The National Library of Medicine (NLM) citation style guide has been used in this paper.