

Primary T-cell non-Hodgkin's lymphoma of the larynx: A case report

Sercan Çıkrıkçı¹, Secaattin Gülşen², Cengiz Durucu³

¹ Department of Otolaryngology, Head and Neck Surgery, Yozgat City Hospital, Yozgat, Turkey
² Department of Otolaryngology, Head and Neck Surgery, Dr. Ersin Arslan Training and Reserch Hospital, Gaziantep, Turkey
³ Department of Otolaryngology, Head and Neck Surgery, Private Düztepe Yaşam Hospital, Gaziantep, Turkey

ORCID ID of the author(s)

SC: 0000-0002-3327-3959
SG: 0000-0003-0687-6057
CD: 0000-0001-7607-6421

Abstract

Lymphoma is a malignant disease of lymphatic cells. Despite numerous sub-types, the disease is generally divided into two main groups: Hodgkin and non-Hodgkin lymphoma. Primary laryngeal non-Hodgkin lymphoma accounts for less than 1% of all laryngeal tumors. We herein present a 43-year-old male patient with difficulty swallowing due to a laryngeal mass. Morphological and immunohistochemical examination revealed T cell lymphoma according to the World Health Organization classification. The patient was referred for chemo-radiotherapy. Primary lymphoma of the larynx is a rare, and primary T-cell laryngeal lymphoma is an even rarer tumor.

Keywords: Larynx, Lymphoma, Non-Hodgkin, T-cell

Introduction

Lymphomas are malignant diseases originating from lymph nodes and other lymphatic tissues. Despite numerous sub-types, the disease is generally divided into two main groups: Hodgkin and non-Hodgkin lymphoma. NHL can also be seen in extranodal regions, with the head and neck (salivary gland, larynx, nose and paranasal region, etc.) being the second most NHL involvement area. Less than 1% of laryngeal tumors are non-Hodgkin lymphoma. It is more common in males compared to females [1, 2]. Laryngeal involvement is usually found in the supraglottic area (aryepiglottic folds or epiglottis). There are also a few cases with primary subglottic involvement in the literature [3].

We aimed to present this rare disease and review the literature.

Corresponding Author

Sercan Çıkrıkçı
Yozgat State Hospital, Erdoğan Akdag avenue,
Vienna street, No:8, Yozgat, Turkey
E-mail: drsrc46@gmail.com

Informed Consent

The authors stated that the written consent was obtained from the patient presented with images in the study.

Conflict of Interest

No conflict of interest was declared by the authors.

Financial Disclosure

The authors declared that this study has received no financial support.

Published

2021 April 15

Copyright © 2021 The Author(s)

Published by JOSAM

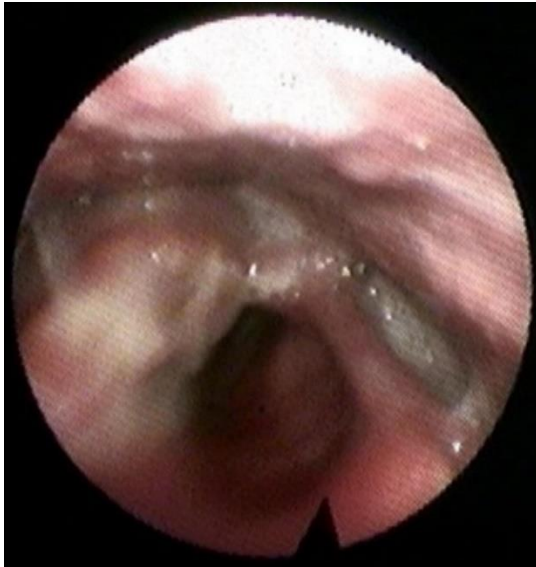This is an open access article distributed under the terms of the Creative Commons Attribution-Non Commercial-NoDerivatives License 4.0 (CC BY-NC-ND 4.0) where it is permissible to download, share, remix, transform, and buildup the work provided it is properly cited. The work cannot be used commercially without permission from the journal.



Case presentation

A 43-year-old male patient was admitted to our clinic with a feeling of something stuck and pain on the right side of the throat. The patient had had a swelling in the neck before presentation, which had spontaneously resolved. He had no smoking history. He had hoarseness, and no fever, weight loss and night sweats. In indirect laryngoscopy, a lesion was seen to extend from the right arytenoid to the epiglottis (Figure 1).

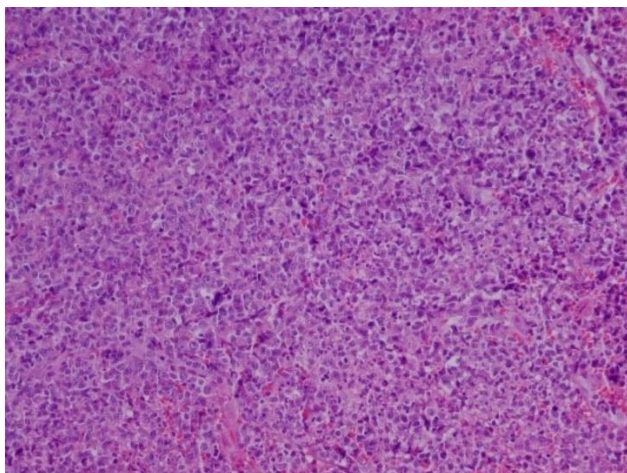
Figure 1: Flexible fiberoptic view of the larynx



After obtaining patient consent, direct laryngoscopy was performed under general anesthesia. On the laryngeal face of the epiglottis, there was a mass extending from the right epiglottic fold to the root of the tongue. A biopsy was obtained.

In histopathological examination, neoplastic cells stained positive for CD3, CD5, CD4, focally positive for CD30 and negative for pancytokeratin, CD20, CD8, Alk-1, Bcl-2, Bcl-6, CD10, CyclinD1, CD79a and CD2. The proliferative index was 70% with Ki-67. The tumor was consistent with T cell lymphoma according to the World Health Organization classification system (Figure 2).

Figure 2: Staining with Hematoxylin eosin (200)



After consultation with medical oncology, the patient was referred for chemo-radiotherapy. He died two years after the diagnosis. Written consent was obtained from the relative of the patient presented in the study.

Discussion

If there is no smoking history, non-SCC laryngeal cancers may be the cause of hoarseness and difficulty in swallowing. In such patients, adenocarcinoma, sarcomas, lymphoma are the first malignancies that come to mind. If there are systemic complaints (fever, night sweats, weight loss etc.), lymphoma is considered first.

Laryngeal lymphomas tend to remain localized and asymptomatic for a long time. Classical laryngeal lymphoma symptoms include lymphadenopathy, dysphagia, dyspnea, and hoarseness. Systemic symptoms are less common [4]. In a retrospective cohort study of 200 cases with laryngeal lymphoma, Scott et al. found the mean age to be 64.2 years (range: 4-82 years) [2]. Other publications in the literature state that laryngeal lymphoma occurs more frequently in 7th decade of life [5,6]. The patient in our case report was 43 years old.

Laryngeal lymphomas are extremely rare malignancies since the larynx contains a relatively small amount of lymphoid tissue compared to other tissues. Most laryngeal lymphomas were detected in the supraglottic region, because this area contains relatively more follicular lymphoid tissue than other parts of the larynx [7]. In his epidemiological study, Scott et al. reported that the tumor was supraglottic in 51.5% of cases [2].

The majority of extranodal lymphomas in the head and neck region are NHLs [8]. Among the cases of NHL affecting the larynx, the most common classifications described in the literature include mucosa-associated lymphoid tissue (MALT) lymphoma, plasmacytoma, and diffuse large B cell lymphoma [9].

In the literature, approximately 70% of laryngeal lymphomas are B-cell non-Hodgkin lymphoma [2, 3, 6]. The diagnosis of primary NHL with peripheral T cells is very rare [10].

Radiologically, primary laryngeal lymphomas are defined as soft submucosal masses, and ulceration occurs vary rarely. [3].

Macroscopically, these tumors typically appear as flat or non-polypoid ulcer masses in endoscopy [3, 4]. Histopathological examination is required for definitive diagnosis. According to the literature, more than one biopsy may be required to make an accurate diagnosis [11].

Chemotherapy and radiotherapy are the most common treatment strategies advocated worldwide in the treatment of laryngeal lymphoma. Laryngeal lymphomas are highly radiosensitive [12].

Although supraglottic lymphomas are more common than lymphomas originating from the glottic or subglottic regions of the larynx, they do not have a better or worse prognosis. It was concluded that survival in laryngeal lymphoma patients is not significantly affected by the primary site of the tumor [2]. Patients with T cell NHL and lymph node involvement show poor prognosis [1]. Primary laryngeal peripheral T cell lymphoma appears to be worse than its nodal counterparts [13].

Conclusion

Laryngeal lymphomas are rare, and T-cell lymphomas are even rarer than other types. Laryngeal lymphomas are usually limited to the larynx, so they remain asymptomatic for a long time. There may be difficulties in diagnosis due to its atypical

clinical presentation. This case report and presentations of other laryngeal lymphomas in the literature can help create a database.

References

1. Zhao P, Zhou Y, Li J. Primary Laryngeal Lymphoma in China: A Retrospective Study of the Last 25 Years. *J Laryngol Otol*. 2019;19:1-4. doi: 10.1017/S0022215119001622.
2. Scott AH, Bobby AT, Sunah C, Inna AH. Epidemiology and Prognostic Indicators in Laryngeal Lymphoma: A Population-Based Analysis. *Laryngoscope*. 2018;128(9):2044-9. doi: 10.1002/lary.27074.
3. Siddiqui NA, Branstetter BF, Hamilton BE, Ginsberg LE, Glastonbury CM, Harnsberger HR et al. Imaging characteristics of primary laryngeal lymphoma. *AJNR Am J Neuroradiol*. 2010;31(7):1261-5. doi: 10.3174/ajnr.A2085.
4. Kim KH, Kim RB, Woo SH. Individual participant data meta-analysis of primary laryngeal lymphoma: focusing on the clinical characteristics and prognosis. *Laryngoscope*. 2015;125(10):2741-8. doi: 10.1002/lary.25391.
5. Junior NT, Zago TM, Pauna HF, Crespo AN. Non-Hodgkin lymphoma in supraglottis: case report. *Otolaryngol (Sunnyvale)*. 2017;7:285. doi: 10.4172/2161-119X.1000285
6. Picard A, Cardinne C, Denoux Y, Wagner I, Chabolle F, Bach C-A. Extranodal lymphoma of the head and neck: a 67-case series. *Eur Ann Otorhinolaryngol Head Neck Dis*. 2015;132(2):71-5. doi: 10.1016/j.anorl.2014.07.005
7. Quimby AE, Cautley L, Rodin D, Purgina B, Eapen L, Shier L, et al. Primary Burkitt lymphoma of the supraglottic larynx: a case report and review of the literature. *J Med Case Rep*. 2017;11(1):65. doi: 10.1186/s13256-017-1209-3.
8. Ishak A, Mat Saad A, Wan Sulaiman W, Husin A, Halim A. Anterior chest wall reconstruction for cutaneous involvement of Hodgkin's lymphoma. *J Surg Med*. 2019;3(12):888-90. doi: 10.28982/josam.592917.
9. Vega F, Lin P, Medeiros LJ. Extranodal lymphomas of the head and neck. *Ann Diagn Pathol*. 2005;9(6):340-50. doi: 10.1016/j.anndiagpath.2005.09.020.
10. Smith MS, Browne JD, Teot LA. A case of primary laryngeal T-cell lymphoma in a patient with acquired immunodeficiency syndrome. *Am J Otolaryngol*. 1996;17(5):332-4. doi: 10.1016/s0196-0709(96)90020-4
11. Tardio JC, Moreno A, Perez C, Hernandez-Rivas JA, Lopez-Carreira M. Primary laryngeal T/NK-cell lymphoma, nasal-type: an unusual location for an aggressive subtype of extranodal lymphoma. *Eur Arch Otorhinolaryngol*. 2008;265(6):705-8. doi: 10.1007/s00405-007-0497-4.
12. Yilmaz M, Ibrahimov M, Mamanov M, Rasidov R, Oktem F. Primary marginal zone B-cell lymphoma of the larynx. *J Craniofac Surg*. 2012;23(1):1-2. doi: 10.1097/SCS.0b013e318242055a
13. Paleri V, Stafford FW, Sammut MS. Laser debulking in malignant upper airway obstruction. *Head Neck*. 2005;27(4):296-301. doi: 10.1002/hed.20153.

This paper has been checked for language accuracy by JOSAM editors.

The National Library of Medicine (NLM) citation style guide has been used in this paper.