

Fournier gangrene in a puerperal woman: An unusual presentation

Necati Hançerlioğulları¹, Esin Merve Koç¹, Selen Yaman¹, Yeliz Çolakoğlu¹, Berkcan Demir², Ahmet Şimşek²

¹ Ankara City Hospital, Department of Obstetrics and Gynecology, Ankara, Turkey

² Ankara City Hospital, Department of General Surgery, Ankara, Turkey

ORCID of the author(s)

NH: <https://orcid.org/0000-0002-5744-7992>
EMK: <https://orcid.org/0000-0001-7686-9149>
SY: <https://orcid.org/0000-0001-5247-6615>
YÇ: <https://orcid.org/0000-0001-7987-1260>
BD: <https://orcid.org/0009-0000-1809-9780>
AŞ: <https://orcid.org/0000-0001-7936-4840>

Corresponding Author

Necati Hançerlioğulları
Department of Obstetrics and Gynecology,
Ankara Bilkent City Hospital, 06600 Ankara,
Turkey
E-mail: necatihancerliogullari@gmail.com

Informed Consent

The authors stated that the written consent was obtained from the patient presented with images in the study.

Conflict of Interest

No conflict of interest was declared by the authors.

Financial Disclosure

The authors declared that this study has received no financial support.

Published

2025 February 19

Copyright © 2025 The Author(s)



This is an open-access article distributed under the terms of the Creative Commons Attribution-NonCommercial-NoDerivatives 4.0 International (CC BY-NC-ND 4.0).

<https://creativecommons.org/licenses/by-nc-nd/4.0/>



Abstract

Fournier's gangrene (FG) is a localized form of necrotizing fasciitis that originates in the perineum and external genitalia. Its incidence is low, at 1.6 per 100,000, contributing to less than 0.02% of hospitalizations, and it is particularly rare in women. This report focuses on a case of FG in a 34-year-old woman who had recently undergone a cesarean delivery. The patient, a second-time mother with one previous birth, arrived at our hospital complaining of hip pain during her full-term pregnancy. Post-delivery, she was diagnosed with FG. Her most likely risk factor was a prior anal fissure and home-applied herbal therapy to the affected area. It is important to keep in mind that FG should be considered if an abscess develops in the urogenital region. FG is a potentially fatal infection that necessitates immediate diagnosis and treatment. Its effective management typically includes frequent and thorough debridement, broad-spectrum antibiotics, and diligent wound care.

Keywords: anal fissure, Fournier gangrene, infections, wound therapy, vacuum-assisted closure

Introduction

Fournier's gangrene (FG) is a condition involving a skin, fascia, and subcutaneous tissue infection. Contributing risk factors include prior surgical procedures, diabetes mellitus, intravenous drug use, physical trauma, chronic illnesses, and alcohol abuse [1].

The initial infection begins in the genitourinary system and can spread rapidly. If not addressed, it can lead to toxic shock syndrome, sepsis, and multi-organ failure. Diagnosis techniques include clinical examination, imaging methods to detect gas in soft tissue, and tissue culture. Therapies for treatment include surgical debridement, broad-spectrum antibiotics, and vacuum-assisted closure therapy [2].

The Laboratory Risk Indicator for Necrotizing Fasciitis (LRINEC) is a scoring system utilized to determine the prognosis after diagnosing this condition. The system, first introduced by Wong C and his team [3], signifies a high risk of necrotizing fasciitis when the score reaches 6 or more. The assessment involves six factors: leukocyte count, hemoglobin and sodium levels, glucose and serum creatinine measures, and C-reactive protein value. As indicated by a study conducted by Kincius et al. [4], a LRINEC score above 5 can potentially be fatal. This report aims to document a case of necrotizing fasciitis in a 34-year-old woman post-cesarean delivery.

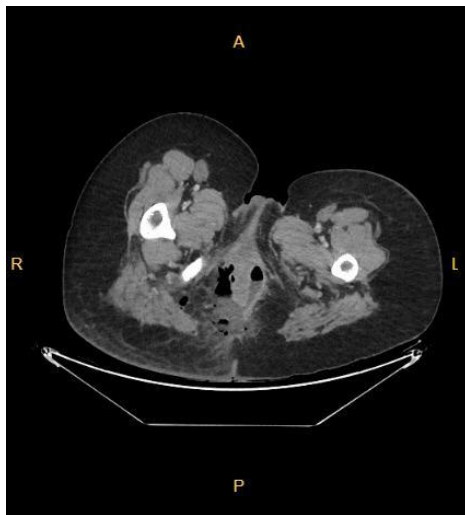
Case presentation

A 34-year-old woman, who had previously given birth via cesarean section and was pregnant for the second time, attended our emergency department. She complained of hip pain and vaginal leakage. Given her history of cesarean section and membrane rupture, another cesarean section was performed. A necrotic skin area was identified in the right gluteal region 12 h post-operation, accompanied by severe infection, discharge, and a sizeable, hardened abscess (Figure 1). A computerized tomography (CT) scan was carried out on her abdomen, and a diagnosis of FG was made (Figure 2).

Figure 1: The gluteal region at the 12th hour postoperation, when symptoms first begin.

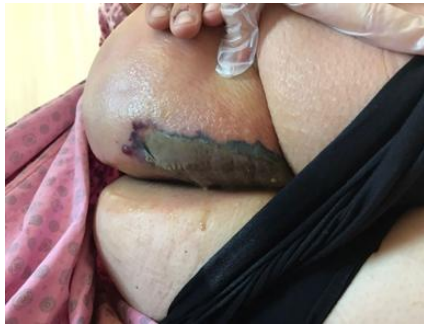

Figure 2: CT scan image showing gas bubbles in the perianal soft tissue



Air values were observed in the subcutaneous soft tissue in the perineal region, in both ischioanal fossae and in the right gluteal region, and diffuse heterogeneity was observed in the subcutaneous adipose tissue. Also, fluid collection was noted in the perineum at the 3–9 o'clock position, compatible with an abscess. Heterogeneity was observed in the perirectal fat tissue. The mesorectal fascia was thick. The bone structures in the section looked natural.

The LRINEC score that is used for The patient's LRINEC prognosis score stands at 8. The leukocyte count is $22 \times 10^3/\text{mm}^3$, and the C-reactive protein (CRP) measurement is 188 mg/dL. The infection consultant recommended that the patient receive piperacillin+tazobactam at 4×4.5 g intravenously and teicoplanin at 1600 mg intravenously every 12 h. A culture from the wound site showed growth of *Enterobacter cloacae*.

The patient was transferred to the general surgery department, where she was sedated and her abscess was drained. No connection to the rectum was discovered during a rectal tap. The wound was regularly debrided and re-dressed every other day in surgery. On non-surgical days, dressing changes were carried

out at the patient's bedside (Figure 3). Upon further investigation into her medical history, it was revealed that she had applied a stinging nettle solution to her anal region a week prior due to a long-term anal fissure.

The patient's infectious process subsided, prompting the application of a vacuum-assisted closure (VAC) to the wound area. VAC replacements occurred every 2 to 3 days, with continuous monitoring of the wound. Despite the patient's FG's proximity to the perianal region, a colostomy was not performed due to the patient's young age. Instead, frequent wound dressing changes and close monitoring were employed. As the VAC treatment proceeded, granulation tissue developed at the wound site. The wound's size gradually decreased until it was able to be secondarily sutured (Figure 4). The wound eventually completely healed and the patient was discharged. Consent for publishing the patient's images was properly obtained both verbally and in written form.

Figure 3: Debridement and vacuum-assisted closure application every other day in the general surgery service

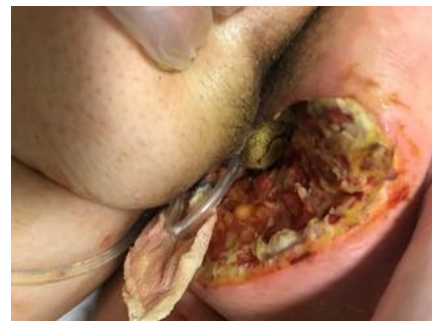
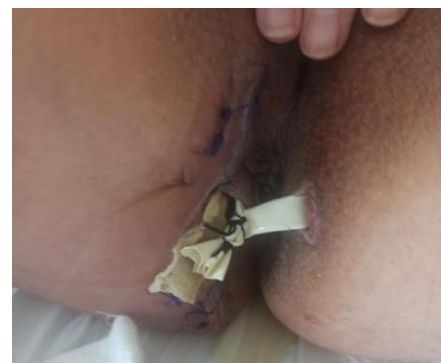
Figure 4: After debridement, vacuum-assisted closure application and suture application



Discussion

The mortality rate for FG is 8.3%. Factors such as a high body mass index, abnormal leukocyte, CRP and platelet counts, as well as impaired renal function, are determinants of infection severity [5]. A study indicated that a poor prognosis is likely due to elevated urea levels, along with low albumin and hematocrit levels [6]. Similarly, in our case, we observed high CRP levels together with low albumin and hematocrit levels.

Fournier gangrene is typically observed in individuals over the age of 50, yet research suggests that advanced age is not a direct contributing factor to the disease [7]. The condition is more common in men, with a reported male-to-female incidence ratio of 5.3:1 [8]. This is attributed to more effective secretion drainage in the female pelvic region. However, the absence of Colles' fascia on a woman's anterior wall can lead to severe spread to the anterior abdominal wall. Thankfully, our patient is young and shows no signs of abdominal wall involvement.

The spread of infection locally is crucial in the disease's pathogenesis. Uncommon in the normal flora of the anogenital region, anaerobic bacteria are often found in wound cultures, along with Gram-negative and Gram-positive pathogens. Frequent pathogens include *Escherichia coli*, *Enterococcus faecium*, *Staphylococcus aureus*, and *Pseudomonas aeruginosa* [9]. In our patient's case, the present bacteria was *Enterobacter cloacae*. A multiple antibiotic regime is typically recommended, including third-generation cephalosporins, 5-nitroimidazole derivative antibiotics, and aminoglycoside [8]. We advised our patient to commence treatment of piperacillin, Tazobactam (4 × 4.5 g iv), and teicoplanin (1600 mg iv), administered every 12 h initially for the first three doses. These therapies are given empirically and should be adjusted based on culture and antibiogram reports. The regulation of blood sugar in diabetes mellitus (DM) is linked with disease progression, so particular attention needs to be paid to predisposing conditions such as DM and kidney failure. Our patient did not have diabetes or other systemic diseases. The most likely risk factor for our patient was a history of anal fissure and herbal therapy applied to that region by the patient.

Early diagnosis is crucial for effectively treating FG. The differential diagnosis can sometimes be challenging, as the infection progresses at a rate of up to 2–3 cm/h and is linked to a high mortality rate. Septicemia can develop within 1 h of disease onset. Early diagnosis depends on evaluating clinical signs, radiological findings, and laboratory analyses. A lack of gas image in the soft tissue during an ultrasound examination does not categorically exclude FG as a diagnosis. In our case, a CT scan was performed immediately as the patient's symptoms emerged, which was pivotal for diagnosis.

In doubtful cases, it is recommended to adopt an aggressive surgical procedure due to the invasive infection's tendency to spread through the fascial planes. The purpose of the surgical intervention is to effectively drain the infection and eliminate any necrotic tissue. However, the debridement should not stop at the normal skin surface but instead continue until a healthy fascia tissue layer is exposed. In the case described, General Surgeons implemented VAC for effective drainage and wound care. The wound was debrided and freshly dressed on alternate days, whereas the VAC was replaced every 2–3 days.

The use of fecal diversion is currently a controversial topic. Despite the patient's FG being situated near the perianal area, a colostomy was not carried out due to her young age. Instead, we adopted a comprehensive follow-up approach that included frequent wound dressings. Through regular patient monitoring and the application of VAC, granulation tissue developed at the wound site, leading to wound regression. Subsequently, the wound was sutured. In our case, care was taken to meticulously execute all surgical procedures.

Conclusions

FG is a serious infectious disease requiring swift diagnosis and aggressive surgical treatment. High-risk patients should be diagnosed through clinical evaluation, imaging, and LRINEC score. The treatment involves aggressive surgical debridement, usage of broad-spectrum antibiotics, careful wound care, and wound closure procedures.

References

- Sorensen MD, Krieger JN, Rivara FP, Broghammer JA, Klein MB, Mack CD, et al. Fournier's gangrene: population based epidemiology and outcomes. *J Urol*. 2009 May;181(5):2120-6. doi: 10.1016/j.juro.2009.01.034.
- El-Qushayri AE, Khalaf KM, Dahy A, Mahmoud AR, Benmelouka AY, Ghozy S, et al. Fournier's gangrene mortality: a 17-year systematic review and meta-analysis. *Int J Infect Dis*. 2020 Mar;92:218-225. doi: 10.1016/j.ijid.2019.12.030.
- Wong CH, Khin LW, Heng KS, Tan KC, Low CO. The LRINEC (laboratory risk indicator for necrotizing fasciitis) score: a tool for distinguishing necrotizing fasciitis from other soft tissue infections. *Crit Care Med*. 2004 Jul;32(7):1535-41. doi: 10.1097/01.ccm.0000129486.35458.7d.
- Kinciş M, Telksnys T, Trumbeckas D, Jievaltys M, Milonas D. Evaluation of LRINEC scale feasibility for predicting outcomes of Fournier gangrene. *Surg Infect (Larchmt)*. 2016 Aug;17(4):448-53. doi: 10.1089/sur.2015.076.
- Park SJ, Kim DH, Choi CI, Yun SP, Kim JH, Seo HI, et al. Necrotizing soft tissue infection: analysis of the factors related to mortality in 30 cases of a single institution for 5 years. *Ann Surg Treat Res*. 2016 Jul;91(1):45-50. doi: 10.4174/ast.2016.91.1.45.
- Doluoğlu ÖG, Karagöz MA, Kılınc MF, Karakan T, Yüçetürk CN, Sarıcı H, et al. Overview of different scoring systems in Fournier's gangrene and assessment of prognostic factors. *Turk J Urol*. 2016 Sep;42(3):190-6. doi: 10.5152/tud.2016.14194.
- Tang LM, Su YJ, Lai YC. The evaluation of microbiology and prognosis of Fournier's gangrene in past five years. *Springerplus*. 2015 Jan 13;4(1):14. doi: 10.1186/s40064-014-0783-8. eCollection 2015.
- Czymek R, Hildebrand P, Kleemann M, Roblick U, Hoffmann M, Jungbluth T, et al. New Insights into the Epidemiology and Etiology of Fournier's Gangrene: A Review of 33 Patients. *Infection*. 2009 Aug;37(4):306-12. doi: 10.1007/s15010-008-8169-x.
- Uluğ M, Gedik E, Girgin S, Celen MK, Ayaz C. The evaluation of microbiology and Fournier's gangrene severity index in 27 patients. *Int J Infect Dis*. 2009 Nov;13(6):e424-30. doi: 10.1016/j.ijid.2009.01.021.

Disclaimer/Publisher's Note: The statements, opinions, and data presented in publications in the Journal of Surgery and Medicine (JOSAM) are exclusively those of the individual author(s) and contributor(s) and do not necessarily reflect the views of JOSAM, the publisher, or the editor(s). JOSAM, the publisher, and the editor(s) disclaim any liability for any harm to individuals or damage to property that may arise from implementing any ideas, methods, instructions, or products referenced within the content. Authors are responsible for all content in their article(s), including the accuracy of facts, statements, and citations. Authors are responsible for obtaining permission from the previous publisher or copyright holder if re-using any part of a paper (e.g., figures) published elsewhere. The publisher, editors, and their respective employees are not responsible or liable for the use of any potentially inaccurate or misleading data, opinions, or information contained within the articles on the journal's website.