

# Evaluation of 39 pediatric cases who underwent open and laparoscopic splenectomy: A retrospective cohort study

Çocuklarda açık ve laparoskopik splenektomi yapılan olguların 39 olgu eşliğinde değerlendirilmesi: Retrospektif kohort çalışması

Özgur Çağlar<sup>1</sup>, Binali Fırınacı<sup>1</sup>, Agah Koray Mansıroğlu<sup>1</sup>, Meriban Karadoğan<sup>2</sup>, Ömer Topuz<sup>3</sup>, Murat Yiğiter<sup>1</sup>, Ahmet Bedii Salman<sup>1</sup>

<sup>1</sup> Department of Pediatric Surgery, Medical Faculty of Ataturk University, Erzurum/Turkey  
<sup>2</sup> Health Sciences University Faculty of Medicine, Kayseri Training and Research Hospital, Department of Pediatric Hematology, Kayseri, Turkey  
<sup>3</sup> Health Sciences University Faculty of Medicine, Kayseri Training and Research Hospital, Department of General Surgery, Kayseri, Turkey

ORCID ID of the author(s)

ÖÇ: 0000-0003-4000-4308  
BF: 0000-0002-0852-2458  
AKM: 0000-0002-8175-7747  
MK: 0000-0002-8024-7876  
ÖT: 0000-0001-8086-4682  
MY: 0000-0002-4310-0752  
ABS: 0000-0002-7435-6865

Corresponding author/Sorumlu yazar:

Özgur Çağlar

Address/Adres: Atatürk Üniversitesi Tıp Fakültesi, Çocuk Cerrahisi Anabilim Dalı, Erzurum, Türkiye  
E-mail: drozgurcağlar@yahoo.com

Ethics Committee Approval: The study was approved by The Ethical Committee of Ataturk University (3/26/2020-03-06). All procedures in this study involving human participants were performed in accordance with the 1964 Helsinki Declaration and its later amendments.

Etik Kurul Onayı: Çalışma Atatürk Üniversitesi Etik Kurulu Başkanlığı (26.03.2020-03-06) tarafından onaylandı. İnsan katılımcıların katıldığı çalışmalardaki tüm prosedürler, 1964 Helsinki Deklarasyonu ve daha sonra yapılan değişiklikler uyarınca gerçekleştirilmiştir.

Conflict of Interest: No conflict of interest was declared by the authors.

Çıkar Çatışması: Yazarlar çıkar çatışması bildirmemişlerdir.

Financial Disclosure: The authors declared that this study has received no financial support.

Finansal Destek: Yazarlar bu çalışma için finansal destek almadıklarını beyan etmişlerdir.

Published: 7/8/2020

Yayın Tarihi: 08.07.2020

Copyright © 2020 The Author(s)

Published by JOSAM

This is an open access article distributed under the terms of the Creative Commons Attribution-NonCommercial-NoDerivatives License 4.0 (CC BY-NC-ND 4.0) where it is permissible to download, share, remix, transform, and build upon the work provided it is properly cited. The work cannot be used commercially without permission from the journal.



## Abstract

**Aim:** In children, aside from trauma-related splenic injury and splenic cysts, splenectomy is frequently performed in hematological diseases due to splenomegaly and thrombocytopenia. The most preferred method in children in the past years was open splenectomy. Today, laparoscopic splenectomy has become a preferred method by pediatric surgeons due to increasing laparoscopic surgical experience. The aim of this study is to present the results of the case series who underwent laparoscopic and open splenectomy in our clinic.

**Methods:** All patients who underwent laparoscopic and open splenectomy between 2008-2019 in our clinic were included in the study. Four ports were used in the laparoscopic splenectomy procedure and port locations differed according to patient age and spleen size. The completely liberated spleen was taken into the specimen removal bag and removed after morcellation. Open surgical method was preferred in cases where the long axis of the spleen was 200 mm or higher. Demographic data, splenectomy indications, surgical techniques and postoperative follow-up data were evaluated retrospectively.

**Results:** Splenectomy was performed laparoscopically in 24 of 39 patients (16 male, 23 female) and with the open method in 15 patients. Surgical indications included hereditary spherocytosis (n=15), idiopathic thrombocytopenic purpura (n=6), beta-thalassemia (n=3) in laparoscopically operated patients and hereditary spherocytosis (n=8), idiopathic thrombocytopenic purpura (n=4) and beta-thalassemia (n=3) in patients operated with the open method. Simultaneous cholecystectomy was performed in 11 cases due to cholelithiasis. The duration of the surgery was significantly longer [132 (47) and 90 (21) min., respectively  $P<0.001$ ], and time until oral feeding [2.3 (0.8) and 3.9 (1.1) days, respectively  $P<0.001$ ] as well as the length of hospitalization were significantly shorter in laparoscopic surgery compared to open surgery [3.80 (1.3) vs. 5.5 (1.2) days, respectively  $P<0.001$ ].

**Conclusion:** Laparoscopic splenectomy is a safe method that should be preferred primarily in experienced centers for earlier feeding, shorter hospitalization times and better cosmetic results.

**Keywords:** Children, Open splenectomy, Laparoscopic splenectomy

## Öz

**Amaç:** Çocuklarda splenektomi sıklıkla travmaya bağlı dalak hasarı, dalak kistleri dışında, splenomegali ve trombositopeni nedeni ile hematolojik hastalıklarda yapılmaktadır. Çocuklarda geçmiş yıllarda daha çok tercih edilen yöntem açık splenektomiydi. Günümüzde laparoskopik cerrahi deneyimlerinin artması sonucunda laparoskopik splenektomi çocuk cerrahları tarafından da tercih edilen bir yöntem haline gelmiştir. Bu çalışmanın amacı kliniğimizde laparoskopik ve açık cerrahi yöntemle dalak cerrahisi yapılan olgu serisinin sonuçlarını sunmaktır.

**Yöntemler:** Kliniğimizde 2008-2019 yılları arasında laparoskopik ve açık yöntemle splenektomi yapılan tüm olgular çalışmaya dahil edildi. Laparoskopik splenektomi işleminde 4 port kullanıldı, port yerleşimleri hasta yaşı ve dalak boyutuna göre farklılıklar gösterdi. Tamamen serbestleştirilen dalak spesimen çıkarma torbası içine alınarak parçalanarak çıkartıldı. Dalak uzun aksının 200 mm ve üzerinde olduğu olgularda açık cerrahi yöntem tercih edildi. Olguların demografik verileri, splenektomi endikasyonları, ameliyat teknikleri ve ameliyat sonrası takip verileri retrospektif olarak değerlendirildi.

**Bulgular:** Çalışmaya alınan 39 hastanın (16 erkek, 23 kadın) 24'üne laparoskopik, 15'ine açık yöntemle splenektomi yapıldı. Ameliyat endikasyonları; laparoskopik splenektomi yapılan olgularda herediter sfersitoz (n=15), idiopatik trombositopenik purpura (n=6), Beta-talasemi (n=3), açık cerrahi splenektomi yapılan olgularda ise herediter sfersitoz (n=8), idiopatik trombositopenik purpura (n=4), Beta-talasemi (n=3) idi. Kolelithiazis nedeniyle 11 olguya eşzamanlı kolesistektomi yapıldı. Laparoskopik cerrahide ameliyat süresi açık cerrahiye göre anlamlı derecede daha uzundu [sırasıyla 132 (47)'e karşılık 90 (21) dk,  $P<0.001$ ]. Laparoskopik cerrahide oral beslenmeye kadar geçen süre açık cerrahiye göre anlamlı derecede daha kısaydı [sırasıyla 2,3 (0,8)'e karşılık 3,9 (1,1) gün,  $P<0.001$ ]. Ayrıca, hastanede yatış süresi laparoskopik cerrahide açık cerrahiye göre anlamlı olarak daha kısaydı [sırasıyla 3,8 (1,3)'e karşılık 5,5 (1,2) gün,  $P<0.001$ ].

**Sonuç:** Laparoskopik splenektomi; oral beslenmeye geçiş sürelerinin daha kısa, hastanede yatma sürelerinin ve kozmetik sonuçlarının daha iyi olması nedeniyle deneyimli merkezlerde öncelikli olarak tercih edilmesi gereken güvenli bir yöntemdir.

**Anahtar kelimeler:** Çocuk, Açık splenektomi, Laparoskopik splenektomi

## Introduction

In children, splenectomy is performed in traumatic rupture, splenic cysts, hematological diseases such as hereditary spherocytosis, idiopathic thrombocytopenic purpura, thalassemia, sickle cell disease and autoimmune hemolytic anemia, and rarely, in tumors [1,2]. Traditionally, until the 1990s, splenectomy was performed with the open method in children and adults. Laparoscopic splenectomy is a technically challenging and demanding procedure, especially in children. With pediatric surgeons' increasing experience in laparoscopic surgery in the recent years, laparoscopic splenectomy became an effective and safe surgical technique [3].

The aim of this study is to present the results of the case series of laparoscopic and open splenectomy procedures performed in our clinic.

## Materials and methods

Ethical approval for this study (Ethics Committee Ataturk University- file no: B.30.2.ATA.0.01.00/152) was granted by the Ethics Committee of Ataturk University, Erzurum, Turkey on 26 March 2019. The study involved 39 patients who underwent open or laparoscopic splenectomy surgery in our clinic between 2008 and 2019. Demographic data of the cases, indications for splenectomy, surgical techniques, complications, duration of surgery, time until postoperative oral feeding and hospitalization times were recorded. The patients were divided into two groups as those who underwent laparoscopic and open surgery. These two groups were compared in terms of complications, duration of surgery, time until postoperative oral feeding, and length of hospital stay.

### Statistical analysis

Statistical analysis was performed with SPSS Statistics version 20.0 (IBM, Armonk, NY, USA). Normal distribution of data was assessed with the Kolmogorov–Smirnov test or histogram. Descriptive statistics included the mean with standard deviation or percentages depending on the characteristics of the data. Continuous variables were expressed as mean and standard deviation (SD). The groups were compared using the t-test for normally-distributed independent variables, and the Mann–Whitney U test for non-normally distributed data. Nominal variables were compared using the Chi-square test. A *P*-value of less than 0.05 was considered statistically significant.

## Results

Splenectomy was performed laparoscopically in 24 of the 39 patients (16 males, 23 females) and with the open method in 15 cases. There were no statistically significant differences between the laparoscopic and open surgeries in terms of gender (male:11 / female:13 and male:5 / female:10, respectively, *P*=0.440) and age [10.5 (3.4) and 10.3 (2.9), respectively, *P*=0.839]. Surgical indications included hereditary spherocytosis (n=15), idiopathic thrombocytopenic purpura (n 6), Beta-thalassemia (n=3) in laparoscopically operated patients and hereditary spherocytosis (n=8), idiopathic thrombocytopenic purpura (n=4) and Beta-thalassemia (n=3) in patients operated with the open method (Table 1).

## Surgical method

In patients undergoing laparoscopic splenectomy, 4 ports were used, and port locations differed according to patient age and spleen size. In ultrasonographic measurements, the mean long axial length of spleen was 141.00 (32.05) mm, the longest being 210 mm. In 2 of the patients who underwent laparoscopic splenectomy, the peripheral veins were sealed with Ligasure cautery without ligation of the splenic artery and vein. In the others, splenic artery and vein were isolated, ligated with the hem-o-lok clips (Figure 1), after which the spleen was dissected from surrounding tissue. The completely liberated spleen was taken into the specimen removal bag and removed after morcellation.

The open surgical method was performed in cases when total splenectomy was planned, in patients with spleens longer than 150mm during the former period when laparoscopic surgical experience was insufficient, and in those with spleens longer than 200 mm. In the open surgical method, the spleen was removed by entering the abdomen through a left subcostal incision, and after ligation of the splenic artery and vein.

Cholecystectomy was performed in 11 cases with concomitant cholelithiasis, 4 of which were performed in addition to laparoscopic splenectomy, and 7 of which accompanied open surgery.

### Perioperative findings

All patients were included in the routine vaccination program (*Streptococcus Pneumoniae*, *Haemophilus Influenzae*, and *Neisseria Meningitidis*) one month before the operation. In a patient who underwent splenectomy with open surgical method because of a large-sized spleen (210 mm), blood transfusion was required due to perioperative bleeding. None of the other patients had any perioperative complications. Accessory spleen was observed and removed in two cases. The duration of the surgery was significantly longer [132 (47) and 90 (21) min., respectively *P*<0.001], and time until oral feeding [ 2.3 (0.8) and 3.9 (1.1) days, respectively *P*<0.001] as well as the length of hospitalization were significantly shorter in laparoscopic surgery (Table 1). During the postoperative period, 11 patients with platelet values between 747-1490 ( $10^3/\mu\text{L}$ ) were administered anticoagulant therapy due to thrombocytosis and none developed venous thrombosis. Transfusion rate was low in patients with hereditary spherocytosis and Beta thalassemia during postoperative follow-up. Thrombocytopenia continued in one of the patients with ITP and the other patients were cured. No complications were detected in the patients during the 1 year follow-up period.

Table 1: Demographic data and perioperative findings

	Laparoscopic (n=24)	Open method (n=15)	<i>P</i> -value
Gender (M/F)	11/13	5/10	0.440*
Age [mean. (SD)] (years)	10.5 (3.5)	10.3 (2.9)	0.839**
Surgical indications			
Hereditary spherocytosis (n)	15	8	0.787*
Idiopathic thrombocytopenic purpura (n)	6	4	
Beta-thalassemia (n)	3	3	
Spleen size	141 (32)	158 (38)	0.184**
Duration of surgery (minutes)	132 (47)	90 (21)	<0.001**
Time until oral feeding (days)	2.3 (0.8)	3.9 (1.1)	<0.001**
Duration of hospitalization (days)	3.8 (1.3)	5.5 (1.2)	<0.001**
Follow-up duration (years)	3.4 (2.1)	6.0 (0.9)	<0.001**

All values are presented as mean (SD: Standard Deviation) or n, M: Male, F: Female, \* Chi-Square test, \*\* Mann-Whitney U test

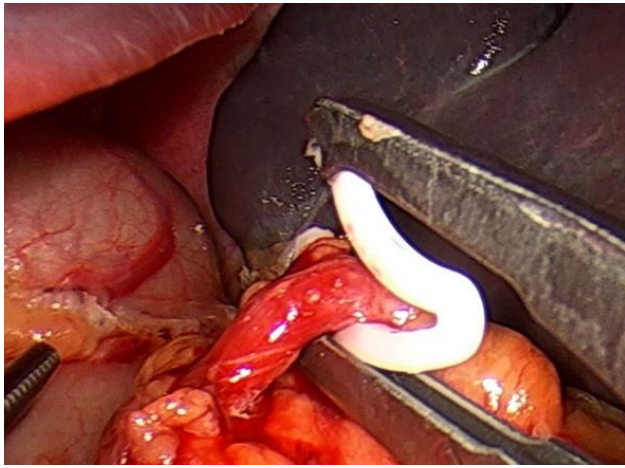


Figure 1: Clipping of splenic artery with hem-o-lok clips

## Discussion

The major key findings of this study were the shortened duration of hospitalization and time until oral feeding with laparoscopic surgery.

In children, splenectomy is performed due to traumatic rupture, splenic cysts, hematological diseases such as hereditary spherocytosis, idiopathic thrombocytopenic purpura, sickle cell disease and autoimmune hemolytic anemia, and rarely, tumors [1,2,4-6]. With the increase in laparoscopic experience of pediatric surgeons in the recent years, laparoscopic surgery has been used more frequently in all pediatric surgery fields. Laparoscopic splenectomy is a safe and effective procedure with shorter hospital stay and lower complication rates in children who require splenectomy for hematological disorders and other reasons [3]. During open and laparoscopic splenectomy, hemorrhage control can be highly challenging, especially in large spleens [7,8]. For hemorrhage control during laparoscopic splenectomy, we first clipped the splenic artery, then the splenic vein [8]. Since the diameter of the splenic vascular structures is small in young children, hemorrhage control can be safely achieved by directly sealing the hilar vascular branches with the vein sealing device without the need for dissection of the splenic artery and vein. In 2 patients who underwent laparoscopic splenectomy (5 and 6 years old), we ligated the peripheral small vessels by using vessel sealing devices without using any clips. In a patient with a large spleen who underwent open total splenectomy, perioperative transfusion was required due to bleeding. None of the laparoscopically operated cases had uncontrolled bleeding, required transfusion or transition to open surgery due to bleeding.

Laparoscopic splenectomy and cholecystectomy are convenient and safe methods in concomitant pathologies of the spleen and gallbladder [9,10]. Since 11 of our cases also had cholelithiasis, cholecystectomy was performed simultaneously, among which four were performed laparoscopically, and seven, in addition to open surgical procedure.

The mean operative times for laparoscopic splenectomy were reported as 97 minutes by Targorona et al. [11], 120 minutes by Deng et al. [12], 80 minutes by Ates et al. [3], and 133 minutes by Ultria et al. [10]. In our study, the mean operative duration was 132 minutes for laparoscopic surgery, and 90 minutes for open surgery, which were both consistent with the literature. The duration of laparoscopic surgery is longer,

especially during the former period when laparoscopic experience is less, in cases where the spleen is over 150 mm in size and in those with concomitant cholecystectomies. The mean duration of operation was significantly shorter in open surgery. Removal of the spleen by morcellation after placement in the specimen removal bag is one of the principal factors which prolongs the process.

Early postoperative oral intake, and short hospitalization time are among the most preferred reasons for laparoscopic surgery. The mean duration of hospitalization was reported as 4 days by Targorona et al. [11], and 5 days by Deng et al. [12]. In our series, mean time until oral feeding in patients who underwent laparoscopic and open splenectomy were 2.32 and 3.93 days, respectively, and mean hospital stay, 3.80 days and 5.53 days, respectively. The duration until oral feeding and hospital stay were significantly shorter in laparoscopic surgery.

Those with large spleens are particularly at risk in terms of laparoscopic surgical technique and venous thrombosis. Thrombocytosis and portal venous thrombosis are important problems in the post-operative period in patients undergoing splenectomy [13]. Venous thrombosis in children is rarer than adults, but since the risk factors are not clear, platelet values should be closely monitored after the surgery. The increase in the number of platelets after splenectomy can be used as a marker for venous thrombosis [14,15]. Portal venous Doppler should be performed to exclude portal venous thrombosis in patients with severe or unexplained abdominal pain, fever and vomiting after splenectomy. Doppler ultrasonography can be performed routinely for control purposes in asymptomatic patients as well, especially in those with large spleens [13]. In our study, intravenous hydration and anticoagulation treatment was administered to 11 patients who developed postoperative thrombocytosis. Venous thrombosis did not develop in any of the patients, who were all followed up with Doppler ultrasonography.

## Limitations

The main limitations of this study are its retrospective nature and small sample size. Less biased results can be obtained with prospective studies. However, our study is important because it compares open and laparoscopic surgical methods in terms of duration of surgery, complications, transition to oral feeding, and hospital stay. Although we have stated that a large spleen constitutes a major difficulty in laparoscopic surgery, especially at the beginning of the learning curve, the fact that we have not performed a thorough analysis on the subject and limited number of patients are among the major limitations of this study. The reason we could not analyze the effect of spleen size is because we preferred open surgery, especially when our laparoscopic experience was not sufficient, in patients with spleens of  $\geq 150$  mm in size at the beginning, and  $\geq 200$  mm in size later in the learning curve.

## Conclusions

The complication rate is exceptionally low in laparoscopic splenectomy in children. Laparoscopic splenectomy, a minimally invasive approach with increased surgical experience, is far superior to open surgical procedure in terms of faster postoperative recovery, earlier feeding, shorter hospital stays, better cosmetic results, and perioperative and

postoperative advantages. Therefore, we think that the laparoscopic method will be accepted by surgeons with sufficient experience as a standard method in cases requiring splenectomy.

## References

1. Fachin CG, Amado F, Romaniello G, Oliveira L, Oliveira I, Wolff L, et al. Open Versus Laparoscopic Splenectomies in Children: A Comparative Study Performed at a Public Hospital in Brazil. *J Laparoendosc Adv Surg Tech A*. 2019;29(10):1357-61.
2. Shamim AA, Zafar SN, Nizam W, Zeineddin A, Ortega G, Fullum TM, et al. Laparoscopic Splenectomy for Trauma. *JLS*. Oct-Dec 2018;22(4):e2018.00050. doi: 10.4293/JLS.2018.00050.
3. Ates U, Tastekin NY, Gollu G, Ergun E, Yagmurcu A. Laparoscopic splenectomy in pediatric age: long-term follow-up. *Arch Argent Pediatr*. 2017;115(6):e385-e90.
4. Huang GS, Chance EA, Hileman BM, Emerick ES, Gianetti EA. Laparoscopic Splenectomy in Hemodynamically Stable Blunt Trauma. *Jls*. 2017;21(2).
5. Moris D, Dimitriou N, Griniatsos J. Laparoscopic Splenectomy for Benign Hematological Disorders in Adults: A Systematic Review. *In Vivo*. 2017;31(3):291-302.
6. Duyuran Ö, Acipayam C, Akkeçeci NS, Sevcan İ, Duyuran R. Etiology of anemia in children aged between 6 months and 18 years. *Journal of Surgery and Medicine*. 2019;3(5):402-5.
7. Ammori BJ. Utilization of the Falciform Ligament to Buttress the Spleen Transection Staple Line During Laparoscopic Partial Splenectomy: A Novel Technique. *Surg Laparosc Endosc Percutan Tech*. 2020;30(1):e1-e3.
8. Ouyang G, Li Y, Cai Y, Wang X, Cai H, Peng B. Laparoscopic partial splenectomy with temporary occlusion of the trunk of the splenic artery in fifty-one cases: experience at a single center. *Surg Endosc*. 2020 Feb 12. doi: 10.1007/s00464-020-07410-0. Online ahead of print.
9. Schizas D, Katsaros I, Karatza E, Kykalos S, Spartalis E, Tsourouflis G, et al. Concomitant Laparoscopic Splenectomy and Cholecystectomy: A Systematic Review of the Literature. *J Laparoendosc Adv Surg Tech A*. 2020.
10. Utria AF, Goffredo P, Keck K, Shelton JS, Shilyansky J, Hassan I. Laparoscopic Splenectomy: Has It Become the Standard Surgical Approach in Pediatric Patients? *J Surg Res*. 2019;240:109-14.
11. Targarona EM, Lima MB, Balague C, Trias M. Single-port splenectomy: Current update and controversies. *J Minim Access Surg*. 2011;7(1):61-4.
12. Deng XG, Maharjan A, Tang J, Qiu RL, Wu YH, Zhang J, et al. A modified laparoscopic splenectomy for massive splenomegaly in children with hematological disorder: a single institute retrospective clinical research. *Pediatr Surg Int*. 2012;28(12):1201-9.
13. Stringer MD, Lucas N. Thrombocytosis and portal vein thrombosis after splenectomy for paediatric haemolytic disorders: How should they be managed? *J Paediatr Child Health*. 2018;54(11):1184-8.
14. Szasz P, Ardestani A, Shoji BT, Brooks DC, Tavakkoli A. Predicting venous thrombosis in patients undergoing elective splenectomy. *Surg Endosc*. 2020;34(5):2191-6.
15. Zaharie F, Muresan MS, Tomuleasa C, Popa G. Laparoscopic splenectomy for hereditary spherocytosis. A case series and review of the literature. *Ann Ital Chir*. 2018;89:569-71.

This paper has been checked for language accuracy by JOSAM editors.

The National Library of Medicine (NLM) citation style guide has been used in this paper.