

## Treatment of iatrogenic pseudo-aneurysms with ultrasonography-guided percutaneous thrombin injection and compression

Deniz Ozturk Kocakgol <sup>1</sup>, Sukru Oguz <sup>2</sup>, Suleyman Bekircavusoglu <sup>3</sup>, Hasan Dinc <sup>2</sup>

<sup>1</sup> Department of Radiology, Mareşal Çakmak State Hospital, Erzurum, Turkey

<sup>2</sup> Department of Radiology, School of Medicine, Karadeniz Technical University, Trabzon, Turkey

<sup>3</sup> Department of Radiology, Bursa City Hospital, Bursa, Turkey

### ORCID ID of the author(s)

DOK: 0000-0003-3780-2173  
SO: 0000-0002-1354-8898  
SB: 0000-0002-7831-3459  
HD: 0000-0002-0738-1809

### Corresponding Author

Deniz Ozturk Kocakgol  
Adnan Menderes Mahallesi Şehit Burak Karakuş Sokak Al-Furkan Sitesi A Blok Kat:1 No:8  
Palandöken, Erzurum, Turkey  
E-mail: dr.denizz@hotmail.com

### Ethics Committee Approval

This study was approved by the ethics committee of Karadeniz Technical University Medicine School (Approval number: 24237859-135). All procedures in this study involving human participants were performed in accordance with the 1964 Helsinki Declaration and its later amendments.

### Conflict of Interest

No conflict of interest was declared by the authors.

### Financial Disclosure

The authors declared that this study has received no financial support.

### Published

2023 March 6

### Copyright © 2023 The Author(s)

### Published by JOSAM

This is an open access article distributed under the terms of the Creative Commons Attribution-NonCommercial-NoDerivatives License 4.0 (CC BY-NC-ND 4.0) where it is permissible to download, share, remix, transform, and build upon the work provided it is properly cited. The work cannot be used commercially without permission from the journal.



### Abstract

**Background/Aim:** Recently, endovascular interventional procedures have become prevalent. Thus, complications due to arterial catheterization are frequent. The most common access site complications are pseudo-aneurysms (PSAs). The present study aimed to treat iatrogenic pseudo-aneurysm (PSA) with ultrasonography (US)-guided compression and percutaneous thrombin injection and to report these methods' effectiveness and short-term outcomes.

**Methods:** The study was designed as a retrospective cohort study. Two treatment techniques were performed. Forty-eight of 54 patients were included in the study. Forty patients were treated with US-guided percutaneous thrombin injection, and eight were treated with US-guided compression. Six of the 54 patients were excluded from the study. Two of these patients needed further surgical treatment. The other four patients needed no further intervention due to spontaneous thrombosis of PSA. The patient demographics, history of AC/AA drug use, indication for performing arterial catheterization, localization and size of PSAs, treatment method applied, the effectiveness of treatment, early outcomes, and the treatment complications were evaluated.

**Results:** In eight patients treated with US-guided compression, recurrent filling was not observed at the 24-h and first-month post-treatment follow-ups, and 100% success was achieved. Among the 40 patients treated with percutaneous thrombin injection for whom a second session was applied, recurrent filling was observed in six PSAs at the 24-h post-treatment follow-up. While the treatment success rate was 85% in the first session, it increased to 97.5% after the second session. A first-month follow-up could be made in 84.6% of the treated patients, and recurrence was observed in no patients.

**Conclusion:** US-guided thrombin injection for PSAs has a high success rate. It is practical, relatively rapid to perform, has low complication rates, and may be selected as the first treatment choice for PSA.

**Keywords:** iatrogenic pseudoaneurysms, US-guided compression, US-guided percutaneous thrombin injection

## Introduction

Pseudoaneurysms (PSAs) are hematomas developing from blood leakage from the vessel wall defect containing blood flow. The pseudo-lumen is associated with the injured artery through the neck. It is the most common complication developing after femoral artery catheterization and comprises 61% of all arterial access site complications. While the incidence of PSA is 0.1–1.1% in diagnostic procedures, it increases to 3.5–5.5% in therapeutic procedures [1-3].

While the primary treatment approach for PSA was surgical methods until the 1990s, minimally invasive methods have gained popularity in medical practices in recent years; compression, ultrasonography (US)-guided thrombin injection, endovascular modalities, and other methods have replaced surgery. These methods have grown in popularity because of their effectiveness and low morbidity and mortality rates [2,4,5].

The present study aimed to evaluate the effectiveness, short-term outcomes, and complication rates of iatrogenic PSAs treated with US-guided percutaneous thrombin injection and compression.

## Materials and methods

We retrospectively screened prospectively-collected data from 54 patients referred to the Karadeniz Technical University Medical Faculty Interventional Radiology Unit due to PSA developing after arterial catheterization between 2011 and 2018. The sample size could not be planned because iatrogenic PSA is an urgent condition that originates mostly from other clinics. Six of the 54 patients were excluded from the study. Two of these patients needed further surgical treatment, and the other four patients needed no further intervention due to spontaneous thrombosis of PSA. Therefore, 48 PSA patients treated with US-guided percutaneous thrombin injection and compression were included in the study. Features of PSAs (e.g., size, connecting artery) were evaluated with the grayscale and color Doppler US (CDUS) using a GE Voluson Expert US device (General Electric, Waukesha, Wisconsin) and 9-Mhz probe.

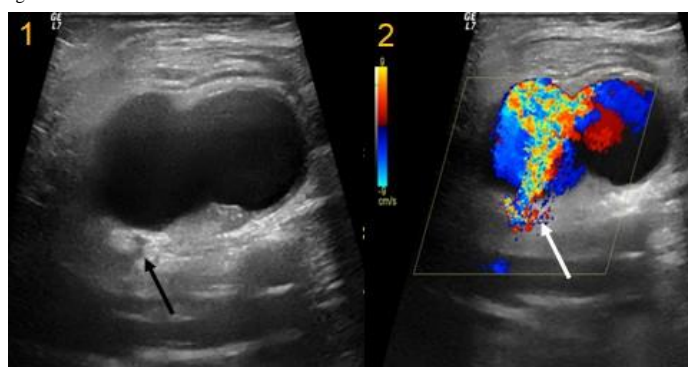
Patients with PSAs with the largest diameter of less than 20 mm and who were not using anticoagulant/antiaggregant (AC/AA) medications were treated with the compression method (Figure 1). Patients with PSAs larger than 20 mm were treated with US-guided percutaneous thrombin injections regardless of the history of AC/AA medication use. After treatment, all patients underwent compression dressing and inguinal compression with sandbag during the first 4 h and 24-h bed rest.

In US-guided compression treatment, the PSA neck was localized with the US, compression was applied to the PSA neck, and the blood flow in the neck region was completely interrupted. The flow was controlled every 15 min during compression. The procedure was terminated when thrombus formation was observed in the PSA sac, and flow was seen to be interrupted.

In patients treated with the US-guided thrombin injection method, surgical prophylaxis was provided by 1 g cephazolin given intravenously 30 min before the procedure, and anaphylaxis prophylaxis was provided by 40 mg methylprednisolone and 45.5 pheniramine maleate given by the

intravenous route 1 h before the procedure. For all patients, human thrombin as TISSEEL (Baxter, Gurgaon, India) KIT 2/4 ml vials was provided following cold chain principles. The skin was sterilized with betadine (povidone-iodine). The PSA sac was entered from the most distant part of the neck part with a 27 gauge (G) dental needle. Following the injection, which lasted for approximately 30–60 s, the procedure was terminated when the PSA lumen was seen to be thrombosed. The flow in the PSA and related arteries were evaluated with CDUS. The patients were followed up for Color Doppler US 24 h and 1 month after the procedure. At the 24-h follow-up, patients who did not have recurrent filling and complaints were discharged. Those who had recurrent filling were re-treated.

Figure 1: Features of PSAs (e.g., size, neck, connecting artery). Neck of PSA with the gray scale (black arrow) and color Doppler US Aliasing artifact (white arrow) and “Ying-Yang” sign.



## Statistical analysis

Data including patient demographics, the intervention that led to PSA, localization of PSA, treatment effectiveness, recurrence, and complications, were given as mean (standard deviation), frequency, and percentage values.

## Results

The mean age of the patients was 61.5 (16.2) years (10–86); 39.6% of the patients were female, 60.4% were male, and 72.9% were using AC/AA medications. PSAs mostly originate from the femoral artery (Table 1). Of 48 patients, 83.3% (40 patients) were treated with US-guided percutaneous thrombin injection, and 16.7% (8 patients) were treated with the US-guided compression method.

Table 1: Demographic and clinical characteristics of the patients.

Parameter	Value
Age, mean (SD)	61.58 (16)
Gender	% (n)
Female	39.6 (19)
Male	60.4 (29)
Procedure	% (n)
Diagnostic coronary angiography	52.1 (25)
Percutaneous coronary intervention	27.1 (13)
Cerebral digital angiography	4.2 (2)
Cerebral aneurysm coil and stent	4.2
Renal AVF embolization	2.1 (1)
Ischemic stroke	2.1
External iliac artery stenting	2.1
Renal artery stenting	2.1
Abdominal aorta stenting-grafting	2.1
Coronary artery by-pass surgery	2.1
Vascular access site	% (n)
Main femoral artery	50 (24)
Superficial femoral artery	41.7 (20)
Deep femoral artery	2.1 (1)
Brachial artery	4.2 (2)
External iliac artery	2.1
AKG/AG history use	72.9 (35)

SD: standard deviation

The mean size of eight PSAs treated with US-guided compression was 18.3 (2.3) mm. For all patients, the duration of treatment varied between 15 and 30 min. The recurrent filling was not observed in patients with the grayscale and color Doppler US at the 24-h and 1-month post-treatment follow-ups.

Of the patients who underwent US-guided percutaneous thrombin injection, 87.5% were taking AC/AA medications. The mean size of PSAs was 35 (9.5) mm (range: 60–20 mm). The mean thrombin dose was 4 (1.7) diziems. At the 24-h post-treatment follow-up, recurrent filling was observed in six PSAs. One patient was treated surgically. Four patients underwent a second thrombin injection, one patient underwent US-guided 25 min compression, and the recurrent filling was not observed on color Doppler US performed at 48 h. While the success rate was 85% in the first injection in the US-guided percutaneous thrombin injection group, the success rate increased to 97.5% with the second procedure. At the first-month follow-up, one patient had died due to cardio-vascular reasons, and the follow-up of five (12.5%) patients were lost. Recurrent filling was not observed in 84.6% of the patients at the first-month follow-up (Table 2). Minor complications related to the procedure developed in three patients. A thrombus developed in the main femoral vein in one patient who had undergone a US-guided percutaneous thrombin injection. In two patients, numbness, sensation loss, swelling, and pain developed following the thrombin injection. The symptoms regressed in 24–48 h with medical treatment.

Table 2: RDUS characteristics of pseudo-aneurysms, treatment method and outcomes.

Parameter	Value
<b>The largest diameter of the pseudo-aneurysm, mean (standard deviation)</b>	32.7 (10.2)
<b>PSA treatment method</b>	%
US-guided compression	16.7
US-guided percutaneous thrombin injection	83.3
<b>Treatment outcomes of all patients</b>	%
24 h	87.5
48 h	98
1 month	87.2
<b>Treatment outcomes of US-guided compression</b>	%
24 h	100
1 month	100
<b>Treatment outcomes of thrombin injection</b>	%
24 h	85
48 h	97.5
1 month	84.6

\* The values given are the rates of the patients whose 1-month control could be realized and in the controlled PSAs of whom no recurrence or residual filling was observed.

## Discussion

While small PSAs may become thrombosed spontaneously, many require treatment. These may lead to more severe complications like rupture, skin necrosis, compression-related deep vein thrombosis, and neuropathy [6,7].

Until the 1990s, surgery was the primary treatment approach for PSAs. In 1991, Fellmeth et al. [6] first treated PSAs with compression. In 1986, Cope et al. [9] applied fluoroscopy-guided percutaneous thrombin injection; in 1997, Liau et al. [10] applied US-guided percutaneous thrombin injection. Gradually, surgical treatment was replaced by non-invasive and percutaneous treatment methods. These approaches reduced mortality and morbidity [2,5,6,8-10].

US-guided compression treatment is more successful than blind compression as it is applied by seeing the PSA neck; the rate of complications such as deep vein thrombosis is lower, and it is more comfortable due to the short duration of the

procedure [11,12]. The success rate is affected by patient age, use of AC drugs, PSA size, being simple or complex, and the length and width of the PSA neck [8,13,14]. Time is the most important factor that restricts US-guided compression treatment. Longer duration induces thrombus. The patient may need analgesics and even narcotics for a prolonged time. It is also difficult for the practitioner to perform compression by keeping the position stable for a long time [11]. In our study, we performed compression treatment on patients whose PSA diameter was less than 2 cm and who were not using AC/AA medications. The duration of compression varied between 15 and 30 min. Hence, we did not encounter problems like pain intolerance and fatigue of the operator resulting from prolonged time. Thrombosis was provided in all patients, and no recurrence or complication was observed during the follow-ups. In the literature, we see a decrease in the success rates of US-guided compression treatment and an increase in the recurrence rates in patients who use AC drugs [13,15]. Studies also report that the PSA size and treatment success are inversely proportional [14,16]. As a result of these studies, we see that the small size of PSAs and the non-use of AC/AA by the patients increase the success rate of compression treatment. We see that US-guided compression treatment has some disadvantages, such as being uncomfortable for the patient and the operator, long duration of treatment, and a low success rate, particularly in patients who use AC/AA and have large PSAs. The history of AC/AA use and the PSA size (<2 cm) should be considered for achieving high success rates and eliminating technical disadvantages.

US-guided percutaneous thrombin injection is a preferred method due to its high success and low complication rates, not containing ionizing radiation, being easily applicable, having a short duration, and being well tolerated [17,18]. The results of our study indicate that US-guided thrombin injection is safe, practical, and successful. Recurrent filling was observed at the 24-h follow-up in 15% of the patients who had undergone US-guided percutaneous thrombin injection. However, the success rate increased to 97.5% with the second session of thrombin injection and US-guided compression method in one patient. Recurrent PSA was not observed at the follow-up 1 month later. In the literature, the success rate of US-guided percutaneous thrombin injection has been reported as 94–100% [5,10,17,19-21]. Previously, compression therapy was more frequently preferred in the treatment of iatrogenic PSAs. However, in the literature, when compared to thrombin injection therapy, success rates of 64–100% were reported, especially in PSA developing more than 2 weeks previously and in AC users. Complications are rare after US-guided percutaneous thrombin injection. According to the results of the studies, the incidence of complications has been reported to be 0–4% [1,8,20,22-25]. The most common complication is thrombin leakage into the arterial lumen associated with PSA and the development of distal embolism. Other complications are quite rare, including swine thrombin-related anaphylaxis-urticaria, infection-abscess, deep vein thrombosis, and coagulopathy due to the development of autoantibodies against factor V in recurrent swine thrombin injection [17,19,26,27]. We encountered two complications in our study: one patient developed a thrombus in the femoral vein; the other was the development of numbness and loss of sensation

in the leg, swelling and pain in the arm, which was thought to be due to the mass effect after thrombin injection in the superficial femoral and brachial artery, which regressed in the follow-up. In the literature, Weinman et al. [25] encountered sudden onset pain in two of 33 patients who underwent thrombin injection and skin infection in one patient. Pezzullo et al. [28] reported foot pain and temporary occlusion in the dorsalis pedis after paresthesia in 1 of 23 patients who underwent a thrombin injection.

### Limitations

The relatively small number of cases, the evaluation of only the size of PSAs, and the inability to evaluate the parameters (such as the number of lobulations and neck diameter) are limitations of our study.

### Conclusion

In our study, we observed that US-guided compression treatment was successful in selected patient groups. US-guided thrombin injection is a treatment method with a high success rate, and it is practical and relatively rapid to apply; it has low complication rates and may be selected as the first treatment choice for PSA.

### References

1. Mauro MA, Murphy KP, Thomson KR, Venbrux AC, Morgan RA. Image-guided interventions e-book: Expert radiology series (Expert Consult-Online and Print): Elsevier Health Sciences; 2013.
2. Saad NE, Saad WE, Davies MG, Waldman DL, Fultz PJ, Rubens DJ. Pseudoaneurysms and the role of minimally invasive techniques in their management. *Radiographics*. 2005;25(suppl\_1):S173-89. doi: 10.1148/rg.25si055503
3. Ahmad F, Turner S, Torrie P, Gibson M. Iatrogenic femoral artery pseudo-aneurysms—A review of current methods of diagnosis and treatment. *Clinical Radiology*. 2008;63(12):1310-6. doi: 10.1016/j.crad.2008.07.001
4. Hung B, Gallet B, Hodges TC. Ipsilateral femoral vein compression: A contraindication to thrombin injection of femoral pseudo-aneurysms. *Journal of Vascular Surgery*. 2002;35(6):1280-3. doi: 10.1067/mva.2002.121748
5. La Perna L, Olin JW, Goines D, Childs MB, Ouriel K. Ultrasound-guided thrombin injection for the treatment of postcatheterization pseudo-aneurysms. *Circulation*. 2000;102(19):2391-5. doi: 10.1161/01.CIR.102.19.2391
6. Fellmeth BD, Roberts AC, Bookstein JJ, Freischlag JA, Forsythe JR, Buckner NK, et al. Postangiographic femoral artery injuries: Nonsurgical repair with US-guided compression. *Radiology*. 1991;178:671-75. doi: 10.1148/radiology.178.3.1994400
7. Kang SS, Labropoulos N, Mansour MA, Baker WH. Percutaneous ultrasound guided thrombin injection: A new method for treating postcatheterization femoral pseudo-aneurysms. *J Vasc Surg*. 1998;27:1032-38. doi: 10.1016/S0741-5214(98)70006-0
8. Morgan R, Belli A-M. Current treatment methods for postcatheterization pseudo-aneurysms. *Journal of Vascular and Interventional Radiology*. 2003;14(6):697-710. doi: 10.1097/01.RVI.0000071089.76348.6A
9. Cope C, Zeit R. Coagulation of aneurysms by direct percutaneous thrombin injection. *American Journal of Roentgenology*. 1986;147(2):383-7. doi: 10.2214/ajr.147.2.383
10. Liao C-S, Ho F-M, Chen M-F, Lee Y-T. Treatment of iatrogenic femoral artery pseudo-aneurysm with percutaneous thrombin injection. *Journal of Vascular Surgery*. 1997;26(1):18-23. doi: 10.1016/S0741-5214(97)70141-1
11. Webber GW, Jang J, Gustavson S, Olin JW. Contemporary management of postcatheterization pseudo-aneurysms. *Circulation*. 2007;115(20):2666-74. doi: 10.1161/CIRCULATIONAHA.106.681973
12. Steinkamp HJ, Werk M, Felix R. Treatment of postinterventional pseudo-aneurysms by ultrasound-guided compression. *Investigative Radiology*. 2000;35(3):186-92.
13. Dean SM, Olin JW, Piedmonte M, Grubb M, Young JR. Ultrasound-guided compression closure of postcatheterization pseudo-aneurysms during concurrent anticoagulation: A review of seventy-seven patients. *Journal of Vascular Surgery*. 1996;23(1):28-35. doi: 10.1016/S0741-5214(05)80032-1
14. Eisenberg L, Paulson E, Kliewer M, Hudson M, DeLong D, Carroll B. Sonographically guided compression repair of pseudo-aneurysms: Further experience from a single institution. *AJR American Journal of Roentgenology*. 1999;173(6):1567-73. doi: 10.2214/ajr.173.6.10584803
15. Cox GS, Young JR, Gray BR, Grubb MW, Hertzner NR. Ultrasound-guided compression repair of postcatheterization pseudo-aneurysms: Results of treatment in one hundred cases. *Journal of Vascular Surgery*. 1994;19(4):683-6. doi: 10.1016/S0741-5214(94)70042-7
16. Coley BD, Roberts AC, Fellmeth BD, Valji K, Bookstein JJ, Hye RJ. Postangiographic femoral artery pseudo-aneurysms: Further experience with US-guided compression repair. *Radiology*. 1995;194(2):307-11. doi: 10.1148/radiology.194.2.7824703
17. Krueger K, Zaehring M, Strohe D, Stuetzer H, Boecker J, Lackner K. Postcatheterization pseudo-aneurysm: Results of US-guided percutaneous thrombin injection in 240 patients. *Radiology*. 2005;236(3):1104-10. doi: 10.1148/radiol.2363040736
18. Sheiman RG, Mastromatteo M. Iatrogenic femoral pseudo-aneurysms that are unresponsive to percutaneous thrombin injection: Potential causes. *American Journal of Roentgenology*. 2003;181(5):1301-4. doi: 10.2214/ajr.181.5.1811301
19. Paulson EK, Nelson RC, Mayes CE, Sheafor DH, Sketch Jr MH, Kliewer MA. Sonographically guided thrombin injection of iatrogenic femoral pseudo-aneurysms: Further experience of a single institution. *American Journal of Roentgenology*. 2001;177(2):309-16. doi: 10.2214/ajr.177.2.1770309
20. Mishra A, Rao A, Pimpalwar Y. Ultrasound Guided Percutaneous Injection of Thrombin: Effective Technique for Treatment of Iatrogenic Femoral Pseudoaneurysms. *J Clin Diagn Res*. 2017 Apr;11(4):TC04-TC06. doi: 10.7860/JCDR/2017/25582.9512. Epub 2017 Apr 1. PMID: 28571227; PMCID: PMC5449873.
21. Khoury M, Rebecca A, Greene K, Rama K, Colaiuta E, Flynn L, et al. Duplex scanning-guided thrombin injection for the treatment of iatrogenic pseudo-aneurysms. *Journal of Vascular Surgery*. 2002;35(3):517-21. doi: 10.1067/mva.2002.120029

22. Paulson EK, Kliewer MA, Hertzberg BS, Tchong JE, McCann RL, Bowie JD, et al. Ultrasonographically guided manual compression of femoral artery injuries. *Journal of Ultrasound in Medicine*. 1995;14(9):653-9. doi: 10.7863/jum.1995.14.9.653
23. Lennox A, Delis K, Szendro G, Griffin M, Nicolaides A, Cheshire N. Duplex-guided thrombin injection for iatrogenic femoral artery pseudo-aneurysm is effective even in anticoagulated patients. *British Journal of Surgery*. 2000;87(6):796-801. doi: 10.1046/j.1365-2168.2000.01436.x
24. Friedman SG, Pellerito JS, Scher L, Faust G, Burke B, Safa T. Ultrasound-guided thrombin injection is the treatment of choice for femoral pseudo-aneurysms. *Archives of Surgery*. 2002;137(4):462-4. doi: 10.1001/archsurg.137.4.462
25. Weinmann E, Chayen D, Kobzantzev Z, Zaretsky M, Bass A. Treatment of postcatheterisation false aneurysms: ultrasound-guided compression vs ultrasound-guided thrombin injection. *European journal of vascular and endovascular surgery*. 2002;23(1):68-72. doi: 10.1053/ejvs.2001.1530
26. Pope M, Johnston K. Anaphylaxis after thrombin injection of a femoral pseudo-aneurysm: recommendations for prevention. *Journal of Vascular Surgery*. 2000;32(1):190-1. doi: 10.1067/mva.2000.106498
27. Sheldon PJ, Oglevie SB, Kaplan LA. Prolonged generalized urticarial reaction after percutaneous thrombin injection for treatment of a femoral artery pseudo-aneurysm. *Journal of vascular and interventional radiology: JVIR*. 2000;11(6):759-61. doi: 10.1016/s1051-0443(07)61636-4
28. Pezzullo JA, Dupuy DE, Cronan JJ. Percutaneous injection of thrombin for the treatment of pseudo-aneurysms after catheterization: an alternative to sonographically guided compression. *American journal of Roentgenology*. 2000;175(4):1035-40. doi: 10.2214/ajr.175.4.1751035.