

Safety and accuracy of cannulated versus non-cannulated iliac screws: Cohort study

Kanüllü ile kanülsüz iliak vidaların güvenilirliği ve doğru yerleşimi: Kohort çalışması

Sinan Yılar¹, Serdar Toy², Kemal Zencirli¹

¹ Department of Orthopedics and Traumatology
Medical Faculty of Atatürk University, Erzurum,
Turkey
² Department of Orthopedics and Traumatology Ağrı
State Hospital, Ağrı, Turkey

ORCID ID of the author(s)

SY: 0000-0002-1268-170X
ST: 0000-0001-8074-4672
KZ: 0000-0003-2702-0266

Abstract

Aim: Fixation with iliac screw is often used in long-segment instrumentation with lumbosacral fusion. Polyaxial screws are sent with fluoroscopy, computerized tomography, and navigation, or by freehand. In our study, we compared the accuracy of the cannulated iliac screw (CAS) and classic iliac screw (CLS) sent under fluoroscopy.

Methods: This study was planned as a cohort study. Patients who underwent long segment fusion and sacroiliac fixation in our clinic between 2015 and 2018 were included in our study. The follow-up period of the patients was at least one year. All radiological and clinical data of patients were followed. Computerized tomographies obtained in the postoperative period were used to investigate the accuracy of the screws. Malposition of the screws was classified as medial, lateral and anterior perforation.

Results: Sixty-six iliac screws of 29 patients who met the study criteria were evaluated. There were 15 patients (34 screws) in the classical screw group and 14 patients (32 screws) in the cannulated screw group. The classic screw group had two screws (one medial, one lateral) malpositioned, while the cannulated screw group had no screw malpositions. There was no statistically significant difference between the two groups. No complications were encountered in both groups during the intraoperative and postoperative periods. While two screws loosening was observed in the CLS group, one screw loosening was observed in the CAS group. No statistically significant difference was found. There was no screw breakage in either group.

Conclusion: The use of cannulated iliac screws for sacroiliac fixation is an effective and reliable treatment option.

Keywords: Bone screw, Joint, Lumbosacral, Sacroiliac

Öz

Amaç: İliak vida ile fiksasyon lumbosakral füzyon yapılan uzun segment enstrümanlarda sıklıkla kullanılırlar. Bu işlem için çoğunlukla floroskopi, CT, Navigasyon eşliğinde veya serbest gönderilen poliaksiyel vidalar kullanılır. Biz çalışmamızda floroskopi kontrolü ile gönderilen kanüllü vida (CAV) ve klasik iliak vidanın (CLV) doğruluğunu karşılaştırdık.

Yöntemler: Çalışma, kohort çalışması olarak planlandı. Çalışmamızda 2015-2018 yılları arasında kliniğimizde uzun segment füzyon ve sakroiliak fiksasyon yapılan hastalar kullanıldı. Hastaların takip süresi en az bir yıl idi. Hastaları takiplerindeki tüm radyolojik ve klinik verileri toplandı. Vidaların doğruluğunu araştırmak için postoperatif dönemde çekilen CT'ler kullanıldı. Vidaların malpozisyonları medial, lateral ve anterior perforasyon olarak sınıflandırıldı.

Bulgular: Çalışma kriterlerine uyan 29 hastanın 66 iliak vidası değerlendirildi. Klasik vida grubunda 15 hasta (34 vida), kanüllü vida grubunda 14 hasta (32 vida) mevcuttu. Klasik vida grubunda iki vida malpozisyonu mevcuttan (bir medial, bir lateral), kanüllü vida grubunda hiç vida malpozisyonu yoktu. İki grup arasında istatistiksel olarak anlamlı fark yoktu. Her iki grupta da cerrahi esnasında ve sonrasında herhangi bir komplikasyonla karşılaşılmadı. CLV grubunda iki vida gevşemesi görülürken CAV grubunda bir vida gevşemesi görüldü. İstatistiksel olarak anlamlı fark bulunamadı. İki grupta da vida kırılması görülmeydi.

Sonuç: Sakroiliak fiksasyon için kanüllü iliak vida kullanımı etkili ve güvenilir bir tedavi seçeneğidir.

Anahtar kelimeler: Kemik vida, Eklem, Lumbosakral, Sakroiliak

Corresponding author/Sorumlu yazar:

Sinan Yılar

Address/Adres: Atatürk Üniversitesi Ortopedi ve
Travmatoloji Anabilim Dalı, Erzurum, Türkiye
e-Mail: sinan_yilar@hotmail.com

□

Ethics Committee Approval: Ethics committee approval was not received due to the retrospective design of the study. All procedures in this study involving human participants were performed in accordance with the 1964 Helsinki Declaration and its later amendments.

Etik Kurul Onayı: Etik kurul onayı çalışmanın retrospektif dizaynından dolayı alınmamıştır. İnsan katılımcıların katıldığı çalışmalarda tüm prosedürler, 1964 Helsinki Deklarasyonu ve daha sonra yapılan değişiklikler uyarınca gerçekleştirilmiştir.

□

Conflict of Interest: No conflict of interest was declared by the authors.

Çıkar Çatışması: Yazarlar çıkar çatışması bildirmemişlerdir.

□

Financial Disclosure: The authors declared that this study has received no financial support.

Finansal Destek: Yazarlar bu çalışma için finansal destek almadıklarını beyan etmişlerdir.

□

Published: 2/29/2020

Yayın Tarihi: 29.02.2020

Copyright © 2020 The Author(s)

Published by JOSAM

This is an open access article distributed under the terms of the Creative Commons Attribution-NonCommercial-NoDerivatives License 4.0 (CC BY-NC-ND 4.0) where it is permissible to download, share, remix, transform, and build upon the work provided it is properly cited. The work cannot be used commercially without permission from the journal.



Introduction

In spinal deformities, the fusion of the lumbosacral region is still very difficult, although the strength of the instruments is increased and the load on the instruments is reduced by osteotomy techniques. In long-segment fused spinal deformities, the bone quality of the sacrum is insufficient to maintain the global alignment of the spine [1-3]. For this reason, in long segment fusions, S2 pedicle screws, alar screws, S2 alar screws, Galveston rods, S2 alar iliac screws and iliac screws are frequently used to support this fusion [2,4,5].

Although it is a safe option, it is vital to place the iliac screws in the right place due to the close relationship of the iliac wings with the visceral organs and neurovascular structures. Several techniques have been developed to improve the accuracy of the screws. These include palpation of the sciatic notch with wide soft tissue dissection, placing screws with fluoroscopy [6,7], use of intraoperative computerized tomography (CT) or navigation [8-11] and lastly, inserting iliac screws through the cannula, as we do [10,12].

In different studies, the accuracy of iliac screws has been investigated and it has been reported that there are around 15% incorrectly sent screws. We hypothesized that when we insert cannulated screws into the iliac wings, the screws will move in a more accurate direction. For this reason, we used cannulated screws in patients who underwent long spinal fusion in our clinic and compared the accuracy of these screws with the classic iliac screws we used before. In different studies, the authors used the cannulated pedicle screws as S2 alar screws and mentioned good results [10,12]. However, we did not find any study showing that it was used and compared for the classic iliac screw. For this reason, to the best of our knowledge, our study is the first study comparing the classic iliac screw and cannulated iliac screw.

Materials and methods

This study was planned as a cohort study. Patients who underwent sacroiliac fixation due to spinal deformity, lumbosacral nonunion and long-segment fusion between 2015-2018 were included in the study. Those with less than one year-follow-up periods and those without postoperative computerized tomography (CT) were excluded from the study. The classic iliac screw (Group 1) was used in patients operated between 2015-2016, and the cannulated iliac screw was used in patients operated between 2017-2018 (Group 2) (Figure 1). The surgeries of all patients were performed by Y.S., an experienced surgeon in spinal surgery.

Surgical procedure

All patients were operated using a posterior midline incision at the radiolucent table. The incisions starting from the spinous processes were extended to the level of the sacroiliac joint. All tissues from spinous processes to transverse processes were dissected laterally. The posterior iliac crest was palpated and the erector spinae muscle was dissected laterally. Posterosuperior iliac spines (PSISs) were detected. The most protruding part of the PSIS was excised with an osteotomy. It was advanced by 30 mm by aiming the anteroinferior spinous process with Straight Path Opener, laterally by 20-30 degrees

and caudally by 30-40 degrees. Then the path opener was retracted and the path opened with the tip of the blunt probe was advanced until it touched the cortical bone. The probes placed in both iliac wings were checked with C-arm scope. During the control, care was taken to ensure that the probes and screws were inside the iliac teardrop (Figure 2A, 2B), because it is possible to control the medial and lateral walls of the iliac wing and the upper end of the sciatic notch (the zenith of the sciatic notch) with the iliac teardrop.

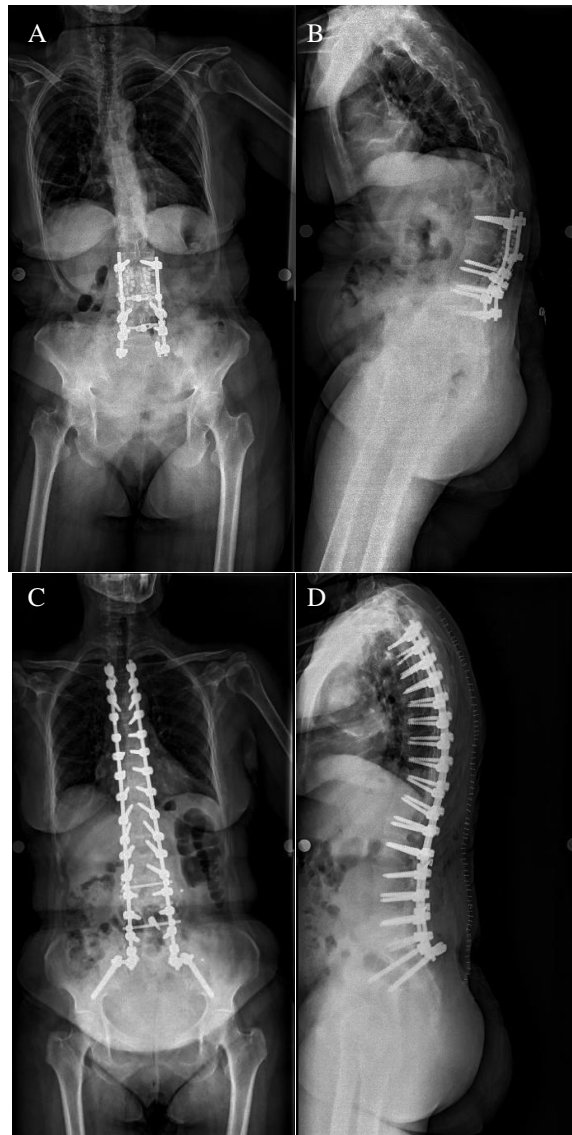


Figure 1: Anteroposterior and lateral X-ray view of kyphosis deformity developing after the operation due to spinal stenosis (A, B). To correct the deformity, the patient underwent instrumentation and 3 levels of Ponte osteotomy between the thoracic 3rd vertebra and the iliac wing. A cannulated iliac screw was used for the iliac wing detection (C, D).

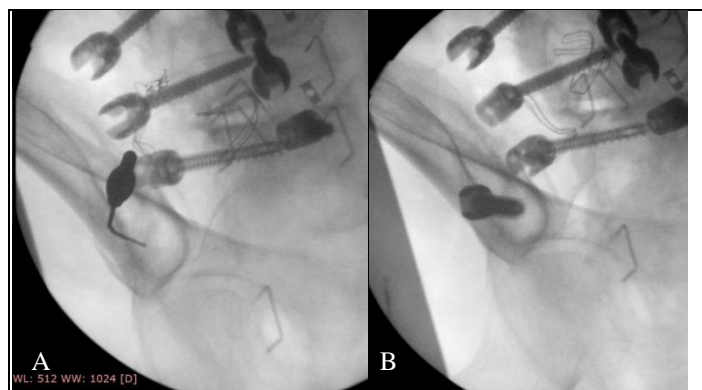


Figure 2: Care was taken to ensure that the blunt-tipped probe and screws were in the iliac tear drop during fluoroscopy control (A, B)

In the classic screw group, the path was widened with the classic tapper after the probe was removed, and then the screws sent following the cortices were checked by the probe. In the cannulated screw group, after removing the thick probe, a guidewire of the same thickness was placed. The guide was controlled with a C-arm scope. After the path was widened with a cannulated tapper, a screw was sent through the guide. While the screw was being sent, we checked the progress of the guidewire. If the guidewire was moving along with the screw, we pulled back the screw and opened another path. Also, after the screw was sent in the bone about 50 mm, the guidewire was withdrawn so that it did not cause a possible organ injury. After the screw placement process was completed, the accuracy of the screw was checked again with the guidewire. The width of the iliac screws was 7.5-9 mm and 70-95 mm long.

Evaluation of the screw malposition

CTs taken in the postoperative period or during follow-ups were used to evaluate screw malposition. The images in the axial, coronal and sagittal plan were examined by Toy S., and metallic densities extending beyond the cortical bone in any of these images were evaluated as screw malposition. Medial and lateral perforations of both groups were recorded. Superior and inferior perforations were evaluated as lateral perforations.

Also, X-rays taken in the last follow-up of patients were interpreted to evaluate the screws for breakage and loosening.

Statistical analysis

Data were analyzed using SPSS version 20.0 (IBM Corp; Armonk, NY, USA. Independent samples t-test and Mann-Whitney U tests were used for the comparisons of normally and non-normally distributed independent groups, respectively. Fisher’s exact test was used for categorical variables. A *P*-value <0.05 was accepted as statistically significant.

Results

After the operation, 66 iliac screws (34 classical screws, 32 cannulated screws) were evaluated in 29 patients (15 classical screws, 14 cannulated screws) with computed tomography. In the preoperative period, ten patients were diagnosed with degenerative scoliosis, nine patients with neuromuscular scoliosis, four patients with flat back, and six patients with iatrogenic kyphosis.

There was no significant difference between the ages (*P*=0.253) of the groups, or in terms of postoperative fusion levels (12.87-12.36) (*P*=0.413). The follow-up period of group 1 was longer than group 2 (30.87 months – 20.00 months) (*P*=0.009) (Table 1).

Table 1: Patient demographics

	Total	Classical screws	Cannulated screws	<i>P</i> -value
Number of patients	29	15	14	0.096
Mean of age	51.48 (18.96)	47.53 (18.98)	55.71 (18.67)	0.253
Level of fusion	12.62 (3.73)	12.87 (3.72)	12.36 (3.87)	0.413
Follow-up periods	25.62 (9.92)	30.87 (8.40)	20.00 (8.37)	0.009
Number of screws	66	34	32	0.942
Number of wrong screws	2	2	0	0.483
Loosening of screws	3	2	1	1.00

Group 1 had two screw malpositions (1 medial, 1 lateral) (Figure 3), while group 2 had none. There was no statistically significant difference between the two groups (*P*=0.483). No symptomatic visceral organ or vascular injuries were observed in either group.

In groups 1 and 2, two and one screw loosening were observed, respectively. No statistically significant difference was found (*P*=1.00). There was no screw breakage in either group.

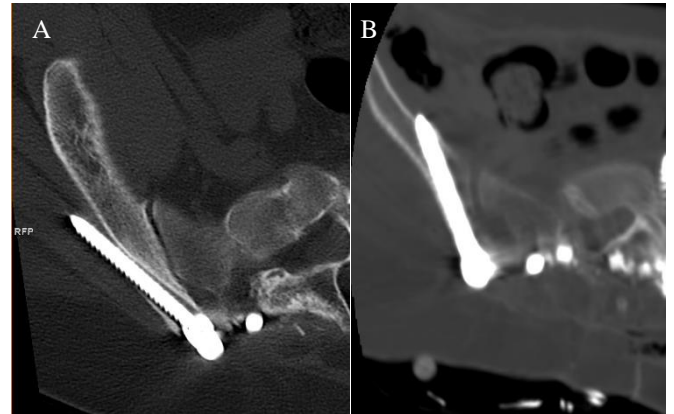

Figure 3: Iliac screw causing lateral wall injury (A), An iliac screw that was seen causing medial iliac wall injury (B)

Discussion

In spinal deformities with long-segment fusion reaching the sacrum, iliac fixation is mostly included in the fusion, since the bone density of the sacrum cannot withstand the force of stress. S2 alar screws, classic iliac screws, Galveston rods, and S2 alar iliac screws, which are iliac fixation techniques, have been shown to be effective for rigid lumbosacral fixation [1-3]. Although conventional iliac screws require additional connection and require wide tissue dissection and are obvious from the skin, these methods are still commonly used sacroiliac fixation methods [5,13,14].

Although the effectiveness and reliability of the iliac screws have been proven, the screws cannot always be sent as intended. Misplaced screws can also cause cortical injuries and neurovascular injuries [5,12]. The accuracy of iliac screws has been shown to vary between 80% and 100% in different studies [3,10,15-17]. In these studies, different methods are tried to decrease screw accuracy and complication rate. The most important of these methods are intraoperative tomography and navigation. Although some of the studies on these methods show that it increases screw accuracy [10], there are also studies showing that it does not affect it at all [16]. With these methods, there is less tissue dissection and less wound site problems and shorter operation times. It also causes less radiation exposure. However, they come with some disadvantages. The first one is the high cost, which makes them unavailable in most centers. They also increase the likelihood of infection, as different devices constantly enter the site of operation [18]. In addition, the use of intraoperative CT increases the radiation exposure of both the patient and the surgical team. In fact, almost all of the screws sent with navigation are sent with the guidewire after navigation, and screws are sent over the guidewire [13,19-21]. The guide prevents the screw from changing the direction of the wire. We were inspired by this, and sent the cannulated iliac screws through the guidewire.

Different studies have proven that the use of cannulated screws in spinal surgery is an effective and reliable method [10,12,22,23]. In our study, we tried to increase our screw accuracy using cannulated iliac screws and compared them with the group in which we used classic iliac screws. Although there was no significant difference between the two groups, we did not

observe screw malpositioning in any patient we used cannulated screws on. The most important reason for this is that the cannulated screw guide prevents the direction of the screw from changing and the accuracy of the screw can be controlled with the cannula.

Although almost all of the iliac screws sent by navigation are cannulated screws, there were only two studies in the literature using cannulated iliac screws without navigation. In a non-controlled study, Choi et al. [12] placed cannulated iliac screws in 16 patients using the S2 AI technique. In this study where 93.8% of the screws were placed in the right place, no complications were encountered. Also, since there was no patient follow-up in this study, no information was provided regarding screw strength. Hlubek et al. [10] examined 111 patients with iliac screws, after they sent cannulated iliac screws with the freehand technique from the traditional and anatomic entry points to a group and compared the accuracy of the screws in this group with the group to which they sent iliac screws with navigation from three different entry points (traditional, anatomic and S2AI). They did not find any significant differences between the two groups (89% - 96%).

One of the most important criticisms of the cannulated screws is the concerns about screw strength and its effect on relaxation. We have not found any biomechanical studies on the stability of the iliac screws. Although the cannulated screws have been shown to be more fragile than conventional screws in a biomechanical study with pedicle screws [24], no weakness has been found in clinical studies [22,23]. To avoid any breakage problem while inserting a cannulated iliac screw, we sent the cannulated taper to the end and tried to bury it in the bone tissue with only the polyaxial part of the screw outside. We did not find any screw breakage after an average of two years of follow-up. In terms of screw loosening, we did not find a significant difference between the two groups.

Limitations

Since the most important limitation of our study was its retrospective nature, we could not investigate the effect of using cannulated screws on radiation exposure, bleeding amount and operation time. Although we are the only study investigating cannulated iliac screw strength, we think that our follow-up time is short to evaluate screw breakage and screw loosening.

This case series that we have done is the first clinical study for cannulated and classical iliac screws using for iliac fixation. This manuscript will be to lead the prospective studies with more patients and longer follow-up in the future. We think that with these studies, concerns about the use of cannulated iliac screws will disappear.

Conclusions

In this case series, we discovered that the usage of classical iliac screws, which are mostly preferred for sacroiliac fixation, do not have a statistically significant difference when compared with cannulated iliac screws. We can easily say that using cannulated screws for sacroiliac fixation is an effective and reliable treatment option. Also, based on our results, we can emphasize that the strength of cannulated screws should not be a matter of concern.

References

- Emami A, Deviren V, Berven S, Smith JA, Hu SS, Bradford DS. Outcome and complications of long fusions to the sacrum in adult spine deformity: luque-galveston, combined iliac and sacral screws, and sacral fixation. *Spine*. 2002;27(7):776-86.
- Shen FH, Mason JR, Shimer AL, Arlet VM. Pelvic fixation for adult scoliosis. *European Spine Journal*. 2013;22(2):265-75.
- Banno T, Ohishi T, Hasegawa T, Yamato Y, Kobayashi S, Togawa D, et al. Accuracy of Iliac Screws Insertion in Adult Spinal Deformity Surgery. *Clinical spine surgery*. 2017;30(4):407-11.
- DeWald CJ, Stanley TJS. Instrumentation-related complications of multilevel fusions for adult spinal deformity patients over age 65: surgical considerations and treatment options in patients with poor bone quality. *Spine*. 2006;31(19S):144-51.
- Keibaish KMJS. Sacropelvic fixation: techniques and complications. *Spine*. 2010;35(25):2245-51.
- Gressot LV, Patel AJ, Hwang SW, Fulkerson DH, Jea A. Iliac screw placement in neuromuscular scoliosis using anatomical landmarks and uniplanar anteroposterior fluoroscopic imaging with postoperative CT confirmation. *Journal of Neurosurgery: Pediatrics*. 2014;13(1):54-61.
- Wang MY, Ludwig SC, Anderson DG, Mummaneni PV. Percutaneous iliac screw placement: description of a new minimally invasive technique. *Neurosurgical Focus*. 2008;25(2):17.
- Garrido BJ, Wood KEJTSJ. Navigated placement of iliac bolts: description of a new technique. *The Spine Journal*. 2011;11(4):331-5.
- Shin JH, DJ Hoh, and IHJON Kalfas. Iliac screw fixation using computer-assisted computer tomographic image guidance. *Operative Neurosurgery*. 2011;70(suppl_1):16-20.
- Hlubek RJ, Almeyty KK, Xu DS, Turner JD, Kakarla UK. Safety and Accuracy of Freehand Versus Navigated Iliac Screws. *Spine*. 2017;42(20):1190-6.
- Doğan Ö, Çalışkan E, Gencer B, Biçimoğlu A. Effect of loss of correction on functional outcomes in thoracolumbar burst fractures treated with short segment posterior instrumentation. *J Surg Med*. 2019;3(8):600-4.
- Choi HY, Hyun SJ, Kim KJ, Jahng TA, Kim HJ. Freehand S2 alar-iliac screw placement using k-wire and cannulated screw: technical case series. *Journal of Korean Neurosurgical Society*. 2018;61(1):75.
- Hu X, Lieberman IHJESJ. Robotic-guided sacro-pelvic fixation using S2 alar-iliac screws: feasibility and accuracy. *European Spine Journal*. 2017;26(3):720-5.
- Tsuchiya K, Bridwell KH, Kuklo TR, Lenke LG, Baldus C. Minimum 5-year analysis of L5-S1 fusion using sacropelvic fixation (bilateral S1 and iliac screws) for spinal deformity. *Spine*. 2006;31(3):303-8.
- Laratta JL, Shillingford JN, Lombardi JM, Alrabaa RG, Benkli B, Fischer C, et al. Accuracy of S2 alar-iliac screw placement under robotic guidance. *Spine Deformity*. 2018;6(2):130-6.
- Shillingford JN, Laratta JL, Park PJ, Lombardi JM, Tuchman A, Saifi C, et al. Human versus Robot: A Propensity-Matched Analysis of the Accuracy of Free Hand: versus: Robotic Guidance for Placement of S2 Alar-Iliac (S2AI) Screws. *Spine*. 2018;43(21):1297-304.
- Bederman SS, Hahn P, Colin V, Kiestner PD, Bhatia NN. Robotic guidance for S2-alar-iliac screws in spinal deformity correction. *Clinical spine surgery*. 2017;30(1):49-53.
- Kim BD, Hsu WK, De Oliveira Jr GS, Saha S, Kim JY. Operative duration as an independent risk factor for postoperative complications in single-level lumbar fusion: an analysis of 4588 surgical cases. *Spine*. 2014;39(6):510-20.
- Togawa D, Kayanja MM, Reinhardt MK, Shoham M, Balter A, Friedlander A, et al. Bone-mounted miniature robotic guidance for pedicle screw and translaminar facet screw placement: part 2—evaluation of system accuracy. *Operative Neurosurgery*. 2007;60(suppl_2):129-39.
- Ughwanogho E, Flynn JJUPOJ. Current navigation modalities in spine surgery. *University Pa Orthop J*. 2010;20:65-69.
- Putzler M, Strube P, Cecchinato R, Lamartina C, Hoff EK. A new navigational tool for pedicle screw placement in patients with severe scoliosis. *Clinical spine surgery*. 2017;30(4):430-9.
- Yilar S. Comparison of the accuracy of cannulated pedicle screw versus conventional pedicle screw in the treatment of adolescent idiopathic scoliosis: A randomized retrospective study. *Medicine (Baltimore)*. 2019;98(10):14811.
- Lee CK, Chan CYW, Gani SMA, Kwan MK. Accuracy of cannulated pedicle screw versus conventional pedicle screw for extra-pedicular screw placement in dysplastic pedicles without cancellous channel in adolescent idiopathic scoliosis: a computerized tomography (CT) analysis. *European Spine Journal*. 2017;26(11):2951-60.
- Shih KS, Hsu CC, Hou SM, Yu SC, Liaw CK. Comparison of the bending performance of solid and cannulated spinal pedicle screws using finite element analyses and biomechanical tests. *Medical engineering & physics*. 2015;37(9):879-84.

This paper has been checked for language accuracy by JOSAM editors.
The National Library of Medicine (NLM) citation style guide has been used in this paper.