

The effect of dexpanthenol on the formation of epidural fibrosis in an experimental laminectomy model in rats

Deneysel epidural fibrosis modelinde dextpanthenol'un epidural fibrosis oluşumu üzerine etkisi

Zahir Kızılay¹, Nesibe Kahraman Çetin², Soner Yayıoğlu¹, Murat Özcan Yay¹, Hakan Öztürk³, Çiğdem Yenisey⁴

¹ Department of Neurosurgery, Aydın Adnan Menderes University, Aydın, Turkey

² Department of Pathology, Aydın Adnan Menderes University, Aydın, Turkey

³ Department of Clinical Biostatistics, Aydın Adnan Menderes University, Aydın, Turkey

⁴ Department of Clinical Biochemistry, Aydın Adnan Menderes University, Aydın, Turkey

ORCID ID of the author(s)

ZK: 0000-0002-2021-0406

NKC: 0000-0002-4549-1670

SY: 0000-0001-9230-1107

MÖY: 0000-0001-8990-7642

HÖ: 0000-0001-8112-4934

ÇY: 0000-0001-7693-641X

Abstract

Aim: Epidural fibrosis, which develops after spinal surgery, is one of the factors which reduce the chances of successful surgery in the medium and long term by tightly surrounding the dura and spinal roots. In this experimental study, the aim was to compare the effects of local and systemic administration of dexpanthenol on epidural fibrosis formation in rats.

Methods: Twenty-eight rats were randomly divided into 4 equal groups (control, Spongostan, local dexpanthenol and systemic dexpanthenol) and laminectomy was performed at the T11 level. Local dexpanthenol (500mg/kg) was administered with Spongostan, and systemic dexpanthenol (500 mg/kg) was administered once a day for three weeks. Epidural fibrosis, arachnoidal involvement, fibroblast cell count, vascular endothelial growth factor, and hydroxyproline levels were evaluated.

Results: The grade of epidural fibrosis, fibroblast cell counts, and hydroxyproline levels were significantly lower in the systemic dexpanthenol groups ($P=0.025$).

Conclusion: Dexpanthenol may be used as potential agent for reducing epidural fibrosis. However, it should be administered more than once for it to take effect.

Keywords: Laminectomy, Epidural fibrosis, Fibroblast, Dexpanthenol, Rat

Öz

Amaç: Spinal cerrahi sonrası gelişen epidural fibrosis dura ve spinal köklerin çevresini sıkıca sarak orta ve uzun vadede cerrahinin başarısını azaltan nedenlerden biridir. Bu nedenle, bu deneysel çalışmada, ratlarda local ve sistemik dekspanthenol uygulamasının epidural fibrosis oluşumu üzerine etkisini karşılaştırmak amaç edinilmiştir.

Yöntemler: Yirmi sekiz adet sıçan rastlantısal olarak 4 eşit gruba ayrıldı (Kontrol, spongostan, local dekspanthenol ve sistemik dekspanthenol) ve bütün sıçanların torakal 11 düzeyine laminektomi yapıldı. Local olarak dexpanthenol 500 mg/kg dan spongostan ile uygulandı. Sistemik olarak dexpanthenol, 500 mg/kg dan günde bir defa olmak üzere 3 hafta boyunca uygulandı. Epidural fibrosis, araknoid tutulum, fibroblast hücre sayısı, vasküler endotelial büyüme faktörü ve hidroksiprolini içeriği değerlendirildi.

Bulgular: Epidural fibrosis derecesi, fibroblast hücre sayısı ve hidroksiprolin düzeyi istatistiksel olarak anlamlı düzeyde sistemik dekspanthenol grubunda düşüktü ($P=0,025$).

Sonuç: Dekspanthenol epidural fibrosis azaltmak için potansiyel bir ajan olabilir, fakat bu etkinin ortaya çıkması için birden fazla sayıda verilmesi gereklidir.

Anahtar kelimeler: Laminektomi, Epidural fibrosis, Fibroblast, Dekspanthenol, Sıçan

Corresponding author / Sorumlu yazar:

Zahir Kızılay

Address / Adres: Aydın Adnan Menderes Üniversitesi
Tıp Fakültesi, Beyin Cerrahisi Anabilim Dalı Aydın,
Türkiye

e-Mail: zahir.kizilay@adu.edu.tr

Ethics Committee Approval: Ethical approval was obtained from the Animal Ethics committee of Aydın Adnan Menderes University with the approval number of 64583101/2017/090.

Etik Kurul Onayı: Etik onay, 64583101/2017/090 onay numarası ile Aydın Adnan Menderes Üniversitesi Hayvan Etik Kurulu'ndan alınmıştır.

Conflict of Interest: No conflict of interest was declared by the authors.

Çıkar Çatışması: Yazarlar çıkar çatışması bildirmemişlerdir.

Financial Disclosure: The authors declared that this study has received no financial support.

Finansal Destek: Yazarlar bu çalışma için finansal destek almadıklarını beyan etmişlerdir.

Published: 1/15/2020

Yayın Tarihi: 15.01.2020

Copyright © 2020 The Author(s)

Published by JOSAM

This is an open access article distributed under the terms of the Creative Commons Attribution-NonCommercial-NoDerivatives License 4.0 (CC BY-NC-ND 4.0) where it is permissible to download, share, remix, transform, and build upon the work provided it is properly cited. The work cannot be used commercially without permission from the journal.



Introduction

Failed back surgery syndrome (FBSS) is described as chronic back pain which persists after spinal surgery, with or without radicular pain [1]. In the literature, the main reported factor in the development of FBSS is extensive fibrotic tissue formation in the epidural distance after surgery, causing widespread adhesions and retractions that involve the neuronal roots and dura [2-4]. It has been reported that epidural fibrosis (EF) occurs after lumbar disc surgery at rates varying between 5% and 33%, and that it can vary depending on the surgery type [5]. Although it is not currently an effective treatment method, the best protection against EF is decreasing its formation [2,6,7]. Many etiological factors which could influence the formation of EF include epidural hematoma, removal of the epidural fat tissue, and paraspinous muscular fiber invasion.

Although the mechanism of EF formation has not been understood, many authors have shown the effect of fibroblast cell proliferation on formation of EF, focusing to decrease fibroblast proliferation and its production. In these studies, free fat grafts, anti-neoplastic and anti-inflammatory agents, Adcol-L, and numerous chemical agents were investigated. However, no standard treatment protocol has been established for humans [2,8-11]. Studies on EF continue to be conducted.

Dexpanthenol, also known as provitamin B5, is an alcohol analogue of pantothenic acid. Following oral or parenteral administration, it is transformed into pantothenic acid in the tissues and has frequently been used to enhance the recovery of skin injuries. Studies on dexpanthenol have shown its anti-oxidative and anti-inflammatory activity [12-15]. There is no information related to effect of dexpanthenol on EF formation.

In this study, we investigated the effects of the local and systemic administration of dexpanthenol in an empirical EF model and discussed the results in the light of the available literature.

Materials and methods

Animals

After receiving the approval of the Animal Ethics Committee (Approval Number 64583101/2017/090), all experimental protocols were followed according to the National Institutes of Health (NIH) Guide for the Care and Use of Laboratory Animals. Twenty-eight adult female Wistar albino rats weighing 300 ± 50 g were used in this study, and they were housed under environmentally suitable conditions at 21–25°C with 50% humidity and a 12-hour light/dark cycles. The rats were provided with free access to food and water.

Groups

The rats were randomly divided into the following four groups (n=7 each) and were treated as indicated.

Group 1: Control (C). T11 total laminectomy was performed and the site was washed with saline.

Group 2: Spongostan (S). T11 total laminectomy was performed and saline was administered with spongostan on the laminectomy area.

Group 3: Local Dexpanthenol (D). T11 total laminectomy was performed and 500 mg/kg dexpanthenol

(Bepanthen injectable solution, Bayer Turk Chemical Co., Turkey) was applied with spongostan.

Group 4: Systemic Dexpanthenol (SD). T11 total laminectomy was performed, saline was applied with spongostan, and 500 mg/kg dexpanthenol was administered once a day for a total period of three weeks.

Surgical procedure and sample preparation

Intraperitoneal (IP) injection of a mixture of 10 mg/kg xylazine hydrochloride (BIOVETA plc, Czech Republic) and 50 mg/kg ketamine HCl (Ketasol, Richter Pharma, Austria) were administered for anesthesia five minutes before the surgery. The body temperatures of the rats were maintained at 37°C, and they were placed in the prone position. The laminectomy areas were shaved and disinfected with povidone-iodine. The same surgeon carried out all surgical procedures. An incision was performed through the skin along the T8–L3 levels. The thoracolumbar fascia and paravertebral muscles were dissected in a subperiosteal manner, reaching the T10–L2 laminae. Total laminectomy was performed at the T11 level. Cotton pads and water were applied to maintain hemostasis. The wounds were sutured in anatomical layers using a 5-0 polypropylene suture after administration of dexpanthenol. On postoperative day 21, the rats were euthanized by cervical dislocation under deep anesthesia. The vertebral columns of the rats were removed *en bloc* between T8 and L3.

Histopathological evaluation

The vertebral column from T9 to L1 including the paraspinous muscles and epidural scar tissue was removed *en bloc* and fixed in 10% neutral-buffered formalin solution. The samples were decalcified in 10% formic acid for approximately 10 days, after which tissue samples were collected from the laminectomy areas, washed with tap water, and routinely processed. Subsequently, the specimens were embedded in paraffin. The upright T11 vertebra was cut into 12 continuous transverse sections of 4 μ m, among which six sections were stained with hematoxylin and eosin (H&E), and the other six with Masson's trichrome stains. The H&E and Masson's trichrome-stained fibrous tissue sections were examined using an Olympus BX52 microscope, and images were captured with an Olympus DP 25 camera. The presence of arachnoid involvement was also identified, and the extent of the EF and the dura mater was graded according to the following scale described by He et al. [16]. Grade 0: the dura mater was free of scar tissue; Grade 1: only thin fibrous bands were observed between the scar tissue and dura mater; Grade 2: continuous adherence was observed in less than two-thirds of the laminectomy defect; Grade 3: scar tissue adherence was considerable, affecting more than two-thirds of the laminectomy defect or the adherence extended to the nerve roots. At 400x magnification, fibroblast density was calculated in three fields of the laminectomy sites from each section.

Immunohistochemistry

The immunostaining was conducted at room temperature using a DAKO autostainer universal staining system (Autostainer Link 48 DAKO, Glostrup, Denmark). The 4- μ m thick paraffin-embedded sections were mounted on positively charged slides, deparaffinized in xylene, and subsequently dehydrated using a graded series of ethanol solutions. Then,

antigen retrieval was performed at 96°C in a 10 mM/L citrate buffer (pH 6) for 40 min in a thermostatic water bath (PT Link). The sections were incubated with vascular endothelial growth factor (VEGF) (RB-9031, NeoMarkers, Fremont, CA, USA) for 60 minutes at room temperature. Positive and negative controls were included for each antibody and each batch of stained tissue. A streptavidin-biotin enhanced immunoperoxidase technique (K8000 Envision Flex, DAKO, Glostrup, Denmark) was used to detect the immunoreactions using an automated system. The sections were incubated with 3,3'-diaminobenzidine (DAB) and counterstained lightly with hematoxylin to demonstrate the binding. Finally, the sections were dehydrated and mounted onto the slides. The positively immunostained slides were used as positive controls. Normal rabbit serum IgG was used to replace primary antibody as a negative control.

Evaluation of immunostaining

The slides were examined at low magnification (100x), areas that exhibited the highest staining intensity were considered "hot spots" and were further evaluated at high magnification (200x). The stained cell ratio was determined by counting at least 200 cells. When $\geq 10\%$ of the cells were stained with the marker, the staining was considered positive. The staining intensity at different magnifications was evaluated using the following scale: "weak," "moderate," and "strong;" visible at 200x, 100x, and 40x magnifications, respectively.

Hydroxyproline content analysis

Total collagen was determined by measuring the concentration of hydroxyproline in each specimen as described by Reddy et al. [17]. The samples (40 mg) homogenized in 100 μ l 2N NaOH were hydrolyzed by autoclaving at 120°C for 20 min. Then, 450 μ l chloramine-T was added to the hydrolysate, mixed gently, and oxidation was allowed to proceed for 25 min at room temperature. 500 μ l of Ehrlich's aldehyde reagent was added to each sample, mixed gently, and the chromophore was developed by incubating the samples at 65°C for 20 minutes. Absorbance of each sample was read at 550 nm using a spectrophotometer. Unknown concentrations of hydroxyproline in each tissue specimen were deduced from a standard calibration curve using L-hydroxyproline. The content of total collagen was calculated assuming that 14 percent of the total amino acids of collagen were hydroxyproline.

Statistical analysis

Kolmogorov-Smirnov test was used to determine whether the variables were normally distributed among groups. One-way ANOVA test was used in the groups showing normal distribution. Kruskal-Wallis H test was used if the group was non-normally distributed. Bonferroni corrected post-hoc test and Tamhane's T2 test were used for pairwise comparisons. Descriptive statistics for the variables were presented as median (25.-75. percentile) and Mean (Standard Deviation). *P*-value of less than 0.05 was considered significant.

Results

Complications associated with wound recovery and medical practice

Dexpanthenol did not induce any adverse effects in the wound area or peripheral tissues. In addition, no infections,

cerebrospinal fluid collections or hematoma were seen in the wound area.

Histopathological results

Grade 3 EF (Figures 1A and 1B) was observed in groups C, S, D and SD in five rats, two rats, five rats and one rat, respectively. Grade 2 EF (Figure 2A and 2B) was observed in groups C, S, D and SD in two, five, two and six rats, respectively. These results were significantly different between the groups ($P=0.025$) (Table 1). In addition, there was a statistically significant difference between groups D and SD.

Arachnoidal involvements were observed in two, one, two and one rats in groups C, S, D and SD, respectively, the difference between which was not significantly different ($P=0.756$).

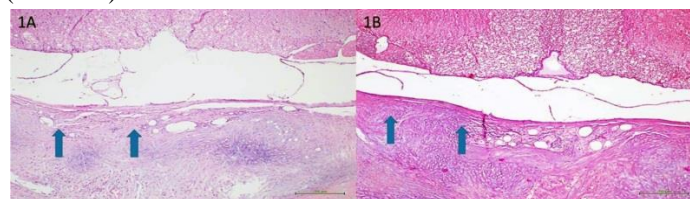


Figure 1: (A) Hematoxylin and eosin (H&E) and (B) Masson trichrome (both 100x magnification) staining of the epidural fibrosis in the laminectomy sites. Grade 3 fibrosis: scar tissue completely covered the laminectomy defects and adhered to the underlying dura mater (arrows)

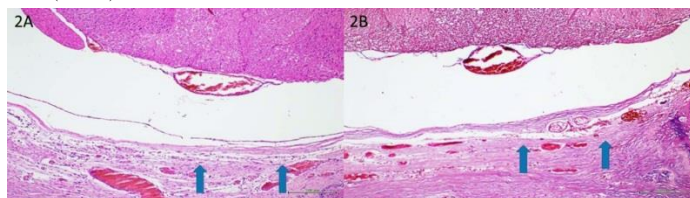


Figure 2: (A) Hematoxylin and eosin (H&E) and (B) Masson trichrome (both 100x magnification) staining of the epidural fibrosis in the laminectomy sites. Grade 2 fibrosis: scar tissue adhered to the underlying dura mater and covered less than two-thirds of the laminectomy sites (arrows)

Fibroblast count results

Fibroblast counts were 197.5 (190 - 200.5), 181 (173.5 - 188.5), 195.5 (193 - 196.5), and 171 (169.5 - 175.5), respectively, in groups C, S, D, and SD. These results were significantly different between the groups ($P<0.001$) (Figure 3A, 3B, 3C and 3D) (Table 2).

Immunohistochemistry results

The VEGF levels were evaluated in each group according to strong, moderate, and weak staining levels. Weak (Figure 4A) and moderate (Figure 4B) levels were observed in four and three rats in Groups C and S, respectively. Weak, moderate, and strong (Figure 4C) staining levels were observed in two, three, and two rats in Group D, respectively. Moderate and strong staining was observed in three and four rats in group SD, respectively. There was no statistically significant difference between the groups ($P=0.068$).

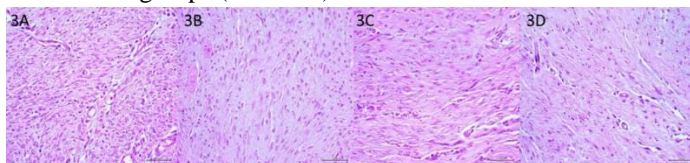


Figure 3: Fibroblast numbers of Control (3A), Spongostan (3B), local dexpanthenol (3C), and systemic dexpanthenol (3D) were expressed as number per counting area (400x).

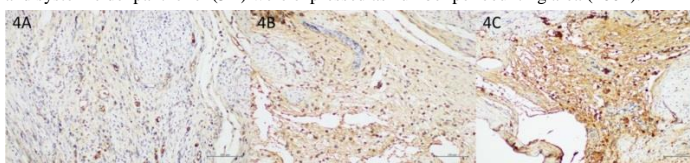


Figure 4: Vascular endothelial growth factor (VEGF) immunostaining of the epidural fibrosis in the laminectomy sites. (4A) Weak, (4B) moderate, and (4C) strong staining (200x magnification).

Hydroxyproline results

Hydroxyproline values were found as 1.556 (1.081) $\mu\text{gHyp/mg}$ wet weight, 0.701 (0.309) $\mu\text{gHyp/mg}$ wet weight, 1.520 (0.346) $\mu\text{gHyp/mg}$ wet weight, and 0.414 (0.104) $\mu\text{gHyp/mg}$ wet weight, respectively, in groups C, S, D, and SD, which significantly differed ($P=0.002$) (Table 3).

Table 1: The grades of epidural fibrosis (EF) according to the He et al. [16]

	C (n=7)	S (n=7)	D (n=7)	SD (n=7)	P-value
EF grade	3 (3-3) ^a	2 (2-3) ^{b,c}	3 (2-3) ^{a,b}	2 (2-2) ^{b,c}	0.025

Descriptive statistics for the variables were given as median (25.-75. percentile). Similar letters in the same line represent similarity, and different letters represent dissimilarity.

Table 2: Fibroblast counting in epidural fibrosis tissue

	C (n=7)	S (n=7)	D (n=7)	SD (n=7)	P-value
Fibroblast Counting	197.5 (190-200.5) ^a	181 (173.5-188.5) ^{b,c}	195.5 (193-196.5) ^{a,b}	171 (169.5-175.5) ^c	<0.001

Descriptive statistics for the variables were given as median (25.-75. percentile). Similar letters in the same line represent similarity, and different letters represent dissimilarity.

Table 3: Hydroxyproline content of the groups

	C (n=7)	S (n=7)	D (n=7)	SD (n=7)	P-value
Hydroxyproline Content	1.556 (1.081) ^{a,b,c,d}	0.701 (0.309) ^b	1.520 (0.346) ^f	0.414 (0.104) ^{b,d}	0.002

Descriptive statistics on variables were given as mean (standard deviation). Similar letters in the same line represent similarity, and different letters represent dissimilarity.

Discussion

The effects of local and systemic administration of dexpanthenol on EF grade were demonstrated in this study. According to our results, EF grades decreased after systemic administration of dexpanthenol compared with local administration and control group. The decrease in hydroxyproline levels in group SD was a factor which reduced EF grades. However, many factors may be responsible for these results.

In the literature, a study conducted by Ermis et al. [13] using a bleomycin-induced lung fibrosis model showed that leukocyte infiltration and lung fibrosis rates were decreased in the dexpanthenol and bleomycin-treated group compared with the group treated with bleomycin alone. They also reported that this effect could be attributed to the combined anti-inflammatory and antioxidant effects of dexpanthenol [13]. Previous studies supported the idea that dexpanthenol may have an effect in decreasing EF formation. In the literature, various studies have shown that decreases in the pro-inflammatory cytokines TNF- α , IL-6, and transforming growth factor β particularly, might decrease the proliferation and differentiation of fibroblasts and EF [1,18-20]. However, in our study, local dexpanthenol was shown to increase the formation of EF, whereas systemic administration decreased it. In fact, our study results are not contrary to those in the literature because there are numerous possible explanations for these results. One of the probable causes is the method of administration. In a study by Ulger et al. [21] which investigated the effects of the local application of nebigolol and dexpanthenol on wound healing, it was reported that although this administration significantly decreased inflammation compared with the control group, fibrosis in the dexpanthenol-treated group was higher. The same study also reported that granulation and angiogenesis rates did not differ significantly between the control and dexpanthenol groups [21]. The study emphasized that local administration of dexpanthenol might increase fibrosis by supporting tissue fibroblasts despite its anti-inflammatory effects. The results of our study support those of Ulger et al. [21], because we have shown that local administration of dexpanthenol increases the level of

hydroxyproline and fibroblast cell count in the laminectomy area. Moreover, in the previous study, authors reported that hydroxyproline levels indicate the amount of collagen and increased hydroxyproline levels are considered one of the most important signs in formation of EF. Therefore, our opinion is that increased level of hydroxyproline related to the local application of dexpanthenol might cause increased EF grade.

Another reason may be that the dose of dexpanthenol is responsible for the observed results. A previous study, conducted by Yardimci et al. [22], who showed that the administration of substantial amounts, even at the same dosage, might induce more obvious anti-fibrotic activity, supports this view. In our study, we also showed that the administration of substantial amounts of dexpanthenol caused a decrease in the level of hydroxyproline and fibroblast cell count in EF tissue. Our opinion is that when dexpanthenol is systemically administered more than once, it may be effective not only at a single stage of inflammation but at many stages at once. This is because a decrease in hydroxyproline levels suggests that inflammation and proliferation phases can be affected. The proliferation phase may be affected indirectly because fibroblasts, which are altered due to decreased pro-inflammatory cytokines, are more prominent in the proliferation phases of the inflammation. In the literature, previous studies have also reported that decreasing tumor necrosis alpha (TNF- α), interleukin (IL)-6, and transforming growth factor β particularly, might decrease the proliferation and differentiation of fibroblasts and EF [1,18-20]. In addition to this, authors have stated that the use of dexpanthenol decreased TNF- α and IL-1 β levels, neutrophil flow, and IL-6 synthesis [15,23].

Limitations

Although we showed for the first time that administration of systemic dexpanthenol had a negative effect of formation of epidural fibrosis, the study had some limitations. Firstly, different doses of dexpanthenol were not administered. Secondly, the molecular mechanisms were not investigated to reveal the action mechanism of dexpanthenol. Third, our sample size was small.

Conclusion

We demonstrated that dexpanthenol should be given more than once for its anti-inflammatory effect, for which the decrease of hydroxyproline and fibroblast cell count may be responsible. Also, dexpanthenol may be effective at various stages of inflammation and a potential agent for reducing EF.

References

1. Lv P, Zhao J, Su W, Liang X, Zhang K. An experimental novel study: hyperbaric oxygen treatment on reduction of epidural fibrosis via a down-regulation of collagen deposition, IL-6, and TGF- β 1. *Eur J Orthop Surg Traumatol.* 2015;25 Suppl 1:S53-8.
2. Sandoval MA, Hernandez-Vaquero D. Preventing epidural fibrosis with nonsteroidal anti-inflammatory drugs. *Eur Spine J.* 2008;17(3):451-5.
3. Mohi Eldin MM, Albed Razek NM. Epidural fibrosis after lumbar disc surgery: prevention and outcome evaluation. *Asian Spine J.* 2015;9(3):370-85.
4. Ozkan U, Osun A, Samancioglu A, Ercan S, Firat U, Kemaloglu S. The effect of bevacizumab and 5-fluorouracil combination on epidural fibrosis in a rat laminectomy model. *Eur Rev Med Pharmacol Sci.* 2014;18(1):95-100.
5. Masopust V, Hackel M, Netuka D, Bradac O, Rokyta R, Vrabec M. Postoperative epidural fibrosis. *Clin J Pain.* 2009; 25(7):600-06.
6. Golan A, Maymon R, Winograd I, Bukovsky I. Prevention of post-surgical adhesion formation using aspirin in a rodent model: a preliminary report. *Hum Reprod.* 1995;10(7):1797-800.
7. Henderson R, Weir B, Davis L, Mielke B, Grace M. Attempted experimental modification of the postlaminectomy membrane by local instillation of recombinant tissue-plasminogen activator gel. *Spine.* 1983;18(10):1268-72.
8. Gill GG, Scheck M, Kelley ET, Rodrigo JJ. Pedicle fat grafts for the prevention of scar in low-back surgery. A preliminary report on the first 92 cases. *Spine (Phila Pa 1976).* 1985;10(7):662-7.
9. Chen H, Yan L, Wang J, Sun Y, Li X, Zhao S, et al. Methotrexate prevents epidural fibrosis through endoplasmic reticulum stress signalling pathway. *Eur J Pharmacol.* 2017;796:131-8.
10. Kurt G, Aydar MH, Dogulu F, Cemil B, Erdem O, Baykaner MK, et al. A comparison of the local effectiveness of mitomycin C, aprotinin, and Adcon-L in an experimental peridural fibrosis. *Surg Neurol.* 2008;70(6):608-13.

11. Kasimcan MO, Bakar B, Aktaş S, Alhan A, Yılmaz A, Caydere M, et al. Effectiveness of the biophysical barriers on the peridural fibrosis of a postlaminectomy rat model: An experimental research. *Injury*. 2011;42(8):778-81.
12. Karadag A, Ozdemir R, Kurt A, Parlakpinar A, Polat A, Vardi N, et al. Protective effects of dexpanthenol in an experimental model of necrotizing enterocolitis. *J Pediatr Surg*. 2015;50(7):1119-24.
13. Ermis H, Parlakpinar A, Gulbas G, Vardi N, Polat A, Cetin A, et al. Protective effect of dexpanthenol on bleomycin-induced pulmonary fibrosis in rats. *Naunyn Schmiedebergs Arch Pharmacol*. 2013;386(12):1103-10.
14. Zakaria MM, Hajjipour B, Khodadadi A, Afshari F. Ameliorating effects of dexpanthenol in cerebral ischaemia reperfusion-induced injury in rat brain. *J Park Med Assoc*. 2011;61(9):889-92.
15. Li-Mei W, Jie T, Shan-He W, Dong-Mei M, Peng-Jiu Y. Anti-inflammatory and anti-oxidative effects of dexpanthenol on lipopolysaccharide-induced acute lung injury in mice. *Inflammation*. 2016;39(5):1757-63.
16. He Y, Revel M, Loty B. A quantitative model of postlaminectomy scar formation. Effects of a nonsteroidal anti-inflammatory drug. *Spine (Phila Pa 1976)*. 1995;20(5):557-63.
17. Reddy GK, Enwemeka CS. A simplified method for the analysis of hydroxyproline in biological tissues. *Clin Biochem*. 1996;29(3):225-9.
18. Mantawy EM, Tadros MG, Awad AS, Hassan DA, El-Demerdash E. Insights antifibrotic mechanism of methyl palmitate: impact on nuclear factor kappa B and proinflammatory cytokines. *Toxicol Appl Pharmacol*. 2012;258:134-44.
19. Battagay EJ, Raines EW, Colbert T, Ross R. TNF-alpha stimulation of fibroblast proliferation. Dependence on platelet-derived growth factor (PDGF) secretion and alteration of PDGF receptor expression. *J Immunol*. 1995; 154(11):6040-7.
20. Pierce GF, Mustoe TA, Lingelbach J, Masakowski VR, Griffin GL, Senior RM, et al. Platelet-derived growth factor and transforming growth factor-beta enhance tissue repair activities by unique mechanisms. *J Cell Biol*. 1989;109(1):429-40.
21. Ulger BV, Kapan M, Uslukaya O, Bozdag Z, Turkoglu A, Alabalik U, et al. A. Comparing the effects of neбиволol and dexpanthenol on wound healing: an experimental study. *Int Wound J*. 2016;13(3):367-71.
22. Yardimci I, Karakan T, Resorlu B, Doluoglu OG, Ozcan S, Aydin A, et al. The effect of intraurethral dexpanthenol on healing and fibrosis in rats with experimentally induced urethral trauma. *Urology*. 2015;85(1):274.e9-13.
23. Ozdemir R, Demirtas G, Parlakpinar H, Polat A, Tanbag K, Taslidere E, et al. Dexpanthenol therapy reduces lung damage in a hyperoxic lung injury in neonatal rats. *J Matern Fetal Neonatal Med*. 2016;29(11):1801-7.

This paper has been checked for language accuracy by JOSAM editors.

The National Library of Medicine (NLM) citation style guide has been used in this paper.

Suggested citation: Patrias K. Citing medicine: the NLM style guide for authors, editors, and publishers [Internet]. 2nd ed. Wendling DL, technical editor. Bethesda (MD): National Library of Medicine (US); 2007-[updated 2015 Oct 2; cited Year Month Day]. Available from: <http://www.nlm.nih.gov/citingmedicine>