

## Results of surgical treatment of ulnar nerve schwannomas arising from upper extremity: Presentation of 15 cases with review of literature

### Üst ekstremitede ulnar sinir schwanomlarının cerrahi tedavi sonuçları: 15 olgu sunumu ile literatür taraması

Alper Aksoy<sup>1</sup>, Emin Sır<sup>2</sup>

<sup>1</sup> Konur Hospital Department of Plastic Aesthetic and Reconstructive Surgery, Bursa Turkey

<sup>2</sup> Private Practice Plastic Aesthetic and Reconstructive Surgery, Izmir, Turkey

ORCID ID of the author(s)

AA: 0000-0002-8993-4103

ES: 0000-0001-7462-1721

Corresponding author / Sorumlu yazar:  
Alper Aksoy

Address / Adres: Konur Hastanesi Zübeyde Hanım Caddesi, Çekirge, Osmangazi, Bursa, Türkiye

E-mail: aksoya@gmail.com

Ethics Committee Approval: Ethical approval was obtained from institutional Ethical committee. Etik Kurul Onayı: Etik kurul onayı, kurumsal Etik kuruldan alındı.

Informed Consent: The authors stated that the written consent was obtained from the patients presented with images in the study.

Hasta Onamı: Yazar çalışmada görüntüleri sunulan hastalardan yazılı onam alındığını ifade etmiştir.

Conflict of Interest: No conflict of interest was declared by the authors.

Çıkar Çatışması: Yazarlar çıkar çatışması bildirmemişlerdir.

Financial Disclosure: The authors declared that this study has received no financial support. Finansal Destek: Yazarlar bu çalışma için finansal destek almadıklarını beyan etmişlerdir.

Received / Geliş Tarihi: 30.01.2019

Accepted / Kabul Tarihi: 04.02.2019

Published / Yayın Tarihi: 05.02.2019

Copyright © 2019 The Author(s)

Published by JOSAM

This is an open access article distributed under the terms of the Creative Commons Attribution-NonCommercial-NoDerivatives License 4.0 (CC BY-NC-ND 4.0) where it is permissible to download, share, remix, transform, and buildup the work provided it is properly cited. The work cannot be used commercially without permission from the journal.



#### Abstract

**Aim:** Schwannomas are the most common benign tumors of upper extremities. The diagnosis of peripheral nerve lesions on clinical history, physical examination, and radiologic tests. Magnetic resonance imaging (MRI) is one of the best to use on schwannomas radiologic test. The aim of this study is to evaluate patients who are diagnosed with schwannomas on the ulnar nerve by mutual agreement between pathology and MRI.

**Methods:** Retrospective cohort study was designed. From January 2011 – December 2016, 15 patients who had surgery ulnar nerve mass and had been diagnosed schwannomas were included in the study. The anatomical classification was at 6 arms, 4 elbows and 5 forearms. Before surgery, all patients were diagnosed with nerve mass through by MRI. Patients were operated under regional anesthesia and microscope.

**Results:** All patients have diagnosed with histopathological schwannomas. All tumors were observed iso-intense in T1-weighted images and hyperintense in T2-weighted ones. Nerve injuries and motor deficit were not observed after surgery. All tumors were enucleated without harming any nerve fibers. The postoperative mean follow-up period was 12.4 months (9 – 29). In the early postoperative period, paresthesia, pain, and hypoesthesia were noted in 10 patients. Neurological symptoms were recovered in postoperative 5 months.

**Conclusions:** Schwannomas are solitary and benign tumors that are shown on the median and ulnar nerve. MRI and high-resolution ultrasonography are the big help to plan the treatment before the surgery. They are removed as intracapsular with acceptable complication ratio. Removing schwannomas can cause some sensation deficit such as pain and paresthesia but these complications are spontaneously decreased.

**Keywords:** Ulnar nerve, Schwannoma, Magnetic resonance imaging

#### Öz

**Amaç:** Schwannomlar üst ekstremitede en sık görülen iyi huylu tümörlerdendir. Periferik sinir kitlelerinde tanıda klinik öykü, fizik muayene ve radyolojik testler önemlidir. Schwannoma tanısında en iyi görüntüleme yöntemi manyetik rezonans görüntülemidir (MRG). Bu çalışmanın amacı ulnar sinirde schwannom tanısı konan hastaların MRG bulguları ile cerrahi eksizyon patoloji sonuçlarının karşılaştırılmasıdır.

**Yöntemler:** Retrospektif kohort çalışma tasarlandı. Ocak 2011 - Aralık 2016 tarihleri arasında, ulnar sinir kitlesi cerrahisi yapılan ve schwannoma tanısı alan 15 hasta çalışmaya dahil edildi. Anatomi sınıflandırma 6 kolda, 4 dirsekte ve 5 ön kolda idi. Ameliyattan önce tüm hastalara MRG ile tanı kondu. Hastalar bölgesel anestezi ve mikroskop altında ameliyat edildi.

**Bulgular:** Bütün hastalardan çıkarılan kitlelere histopatolojik schwannom teşhisi kondu. Tüm tümörler, T1 ağırlıklı görüntülerde izointens ve T2 ağırlıklı görüntülerde hiperintens olarak gözlemlendi. Ameliyat sonrası sinir yaralanmaları ve motor kayıp gözlemlenmedi. Tüm kitleler, herhangi bir sinir lifi zarar görmeden çıkarıldı. Postoperatif ortalama takip süresi 12,4 aydı (9 - 29). Postoperatif erken dönemde 10 hastada paraestezi, ağrı ve hipoestezi gözlemlendi. Tüm vakalarda postoperatif 5. ayda nörolojik semptomlarda iyileşme saptandı.

**Sonuçlar:** Schwannomlar median ve ulnar sinirde görülen soliter ve iyi huylu tümörlerdir. MRG ve yüksek çözünürlüklü ultrasonografi ameliyattan önce tedaviyi planlamak için büyük önem arz etmektedir. İntrakapsüler eksizyonlarda komplikasyon oranı daha düşüktür. Schwannom eksizyonu sonrası, ağrı ve parestezi gibi bazı komplikasyonlar görülsede zaman ile bu komplikasyonlar düzelmektedir.

**Anahtar kelimeler:** Ulnar sinir, Schwannoma, Manyetik rezonans görüntüleme

### Introduction

Schwannomas are the most common benign tumors of upper extremities and originated from Schwann cells of the myelin sheath. The symptoms are solitary, painless swelling as encapsulated mass [1]. They are located on the flexor surface of the upper limbs because upper extremities have more nerve fiber than other extremities parts. They are immobile in a longitudinal plane [2]. Schwannomas cause paresthesia or hypoesthesia and Tinnel’s sign is positive [3]. They usually arise from single nerve fiber and grow circumferentially [4].

Magnetic resonance imaging (MRI) is one of the best to use on schwannomas radiological test. They are observed isointense of T1- weighted and hyperintense of T2-weighted [5]. Diagnosis is identified as microscopic for the lesions that diagnosed schwannomas on MRI [6]. Schwannomas contain histopathologically two various areas, Antoni A and Antoni B. Antoni A is an area that is formed by fusiform cell fascicule. Nucleus of cells is the shape of the elongated, and cytoplasm range is unclear. Antoni B area is the area that shows loose, edema, microcystic and hypocellular areas. Also, Antoni A area includes Verocay bodies which bizonal and bipolar array of the nucleus and homogenous pink area between them [7].

The aim of this study is to evaluate, pre and postoperative pain, paresthesia, hypoesthesia in patients who are diagnosed with schwannomas on the ulnar nerve by mutual agreement between pathology and MRI.

### Materials and methods

Retrospective cohort study was designed from January 2011 – December 2016, 15 patients who had surgery ulnar nerve mass and had been diagnosed schwannomas were included in the study. Ethical approval was obtained from institutional research committee and with the 1964 Helsinki declaration and comparable ethical standards. All patients were informed about the study in detail and a signed consent form was obtained from each patient.

The average age of patients was 36.4 (19 – 61) and gender classification 6 male, 9 women. The anatomical classification was at 6 arms, 4 elbows and 5 forearms. All patients were detected an immobile mass in longitudinal line preoperatively. Tinel’s signs were positive at five patients. Seven patients had paresthesia and pain, five patients had only pain and three patients had only paresthesia. Before surgery, all patients were diagnosed with nerve mass through by MRI. Patients were operated under regional anesthesia and microscope. The nerve was explored and the epineural incision was made longitudinally. The capsule was cut and reached to the tumor. Uninvolved nerve fibers were protected. The tumor was excised without harming nerve fibers (Figure 1). All skin layers were repaired after hemostasis.

### Results

All patients have diagnosed with histopathological schwannomas (Figure 2). All tumors were observed isointense in T1-weighted images and hyperintense in T2-weighted ones (Figure 3). Nerve injuries and motor deficit were not observed after surgery. All tumors were enucleated without harming any

nerve fibers. The postoperative mean follow-up period was 12.4 months (9 – 29).

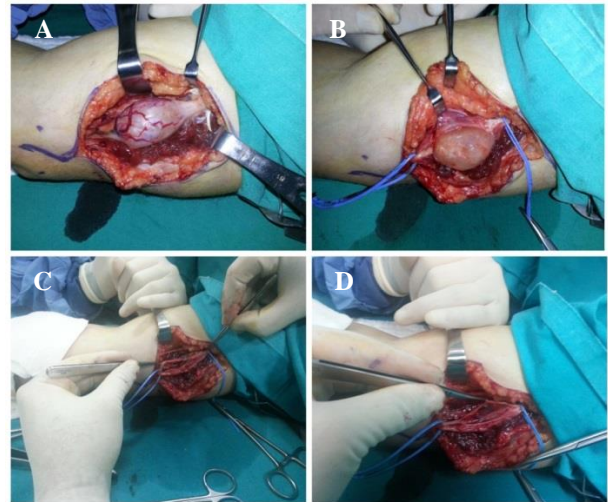


Figure 1: A: Intraoperative view of schwannoma, B: Capsule was incised, C: Schwannoma was enucleated, D: Unharmed ulnar nerve fibers

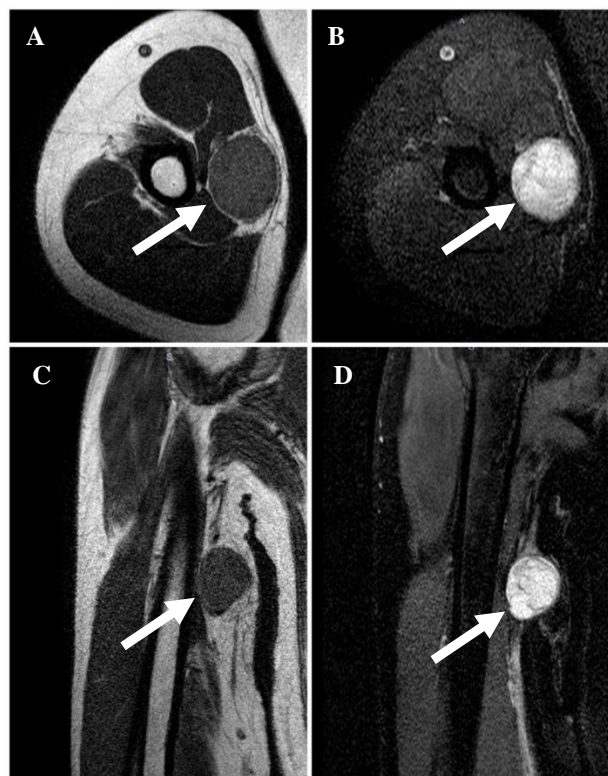


Figure 2: Magnetic resonance view of schwannoma, A,B: Axial plane, C,D: Sagittal plane, Arrow: Mass

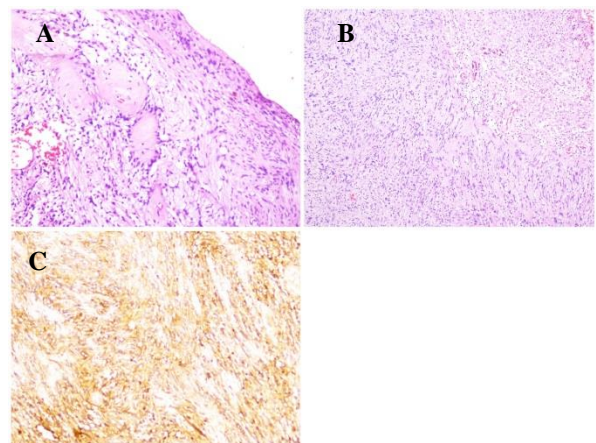


Figure 3: A: Spindle-shaped cells in a fasciculated architecture. There were also hypercellular Antoni A areas and hypocellular Antoni B areas. (H&E x100), B: Nuclear palisading around fibrillary process (Verocay bodies) were seen in cellular areas (H&E x200), C: Immunohistochemical studies revealed S100 protein positivity (x200)

In the early postoperative period, paresthesia, pain, and hypoesthesia were noted in 10 patients. Neurological symptoms were recovered in postoperative 5 months. There were only 2 patients who complained about the pain. Patients are summarized in Table 1.

Table 1: Demographic characteristics of the patients and evaluation parameters

	Age / Gender	Localization	Symptoms	Tinel's Sign	Size	Early Postoperative
1	21/M	Right Elbow	Pain and paresthesia	-	57x27x36 mm	Pain and paresthesia
2	32/F	Left Elbow	Pain	-	55 x 30x 46 mm	Hypoesthesia
3	44/M	Right arm	Pain and paresthesia	-	33.8x21.4x15.4 mm	-
4	39/F	Left Arm	Pain	+	42x31x38 mm	Pain
5	61/ M	Left forearm	Paresthesia	+	21x12x18 mm	Hypoesthesia
6	37/F	Left Elbow	Pain and paresthesia	-	58x32x41 mm	Pain and paresthesia
7	55/F	Right Arm	Pain and paresthesia	+	44x38x40 mm	-
8	28/M	Right Forearm	Pain	-	29x24x26 mm	Pain
9	33/F	Left Elbow	Pain and paresthesia	-	37x26x32 mm	Hypoesthesia
10	26/M	Left Forearm	Pain	+	41x31x34 mm	Pain
11	41/F	Right arm	Paresthesia	-	23x18x22 mm	-
12	19/F	Right arm	Pain and paresthesia	+	36x28x31 mm	Hypoesthesia
13	29/F	Left Forearm	Pain	-	45x37x39 mm	-
14	31/M	Left arm	Pain and paresthesia	-	52x36x44 mm	Pain and paresthesia
15	51/F	Right forearm	Paresthesia	-	43x35x38 mm	-

## Discussion

Primary peripheral nerve tumors are rare and about 5% of them are upper extremities soft tissue tumors. Schwannomas are the most common tumors [8]. The first step of treatment is to proper diagnosis and when you face various symptoms such as slowly growing mass, pain, paresthesia and mass on the flexor surface of upper extremities, schwannomas should be kept in mind to be in charge of [9].

Open and fine needle aspiration biopsy can harm nerve even though the actual diagnosis is schwannoma in a histopathological manner. For that reason, radiologic screening needs to be evaluated and it must be applied to all patients before the surgery. It can be observed the location of tumor on nerve and relationship with surrounding tissues [10].

Treatment of schwannomas is to remove the tumor as intracapsular under the microscopically [11]. There are some studies that show minimum nerve harm [1,9]. But it has said that this surgery is difficult at a digital level and tumor should be removed completely [1]. In our study, all tumors nerve were removed intracapsular enucleation and observed paresthesia and pain were continued in a short-term but their symptoms were ended in the long term. Pulling traction of the nerve during the surgery is the reason of pain and paresthesia in a short term. We did not observe any motor nerve deficit in our patients.

Schwannomas are categorized as involved and not involved nerve fibers. Enucleation is enough on the patients not involved nerve fibers. If nerve fibers got involved, this nerve is included excision and immediately nerve should be repaired with nerve graft in order not to observe motor nerve deficit after surgery [3]. Involved nerve fibers were separated from tumor under microscopically and there was no need the use of nerve graft in our all patients.

After surgery relapse is a very rare condition of solitary and benign schwannomas. Relapse develops with the wrong diagnosis and not enough excision. This leads to secondary operation for patients [1]. Radiological images of patients should be examined well before the operation to prevent secondary surgery. Also, it must be kept in mind that some nerve can be involved in different tumors. In our study, the radiological screening of patients before the surgery ulnar nerve schwannomas has been found solitary and encapsulated mass.

Schwannomas are can be despited with some radiological tests such as ultrasonography, computerized tomography (CT) and MRI [13]. USG is a fast and easy method to access. Nerve pathology is certain diagnosed with high-resolution ultrasonography, even though MRI is the best for certain diagnosis method. Because MRI provides high resolution and three-dimensional screening but this advantages of MRI is high financial cost and not easy to reach [14]. All patients included in our study were diagnosed with histopathological schwannomas. Those patients were diagnosed the same as before surgery on MRI. Some studies show the sensitivity of MRI 91% and 51% for ultrasonography [2,9].

Possible neurological problems after schwannomas excision are between 1.5-80% [15]. Complications of high rate usually are the evaluation of postoperatively early stage [16]. 95% of problems are usually down between the first few months and a year [9]. The complications of our patients who are included in our study were gone completely in 5 months and the motor deficit was not observed. Malign transformation should be taken into consideration if the motor deficit is observed after surgery in a period of time [17].

### Limitations

Main limitation of the study is the number of cases but the number was actually not less because the incidence of peripheral nerves schwannomas in adults is only 5% and upper limb schwannomas contribute 19% of them [18].

### Conclusions

Schwannomas are solitary and benign tumors that are shown on the median and ulnar nerve. MRI and high-resolution ultrasonography are the help to plan the treatment before the surgery. They are removed as intracapsular with acceptable complication ratio. Removing schwannomas can cause some sensational deficit such as pain and paresthesia but these complications are spontaneously decreased.

## References

- Komurcu E, Kaymaz B, Adam G, Gokmen F, Murath A. A hybrid schwannoma of median nerve. *J Coll Physicians Surg Pak*. 2014 Mar;24 Suppl 1:S32-3.
- Ozdemir O, Ozsoy MH, Kurt C, Coskunol E, Calli I. Schwannomas of the hand and wrist: long-term results and review of the literature. *J Orthop Surg (Hong Kong)*. 2005 Dec;13(3):267-72. Review. Erratum in: *J Orthop Surg (Hong Kong)*. 2006 Aug;14(2):following 229.
- Tang CY, Fung B, Fok M, Zhu J. Schwannoma in the Upper Limbs. *Biomed Res Int*. 2013;2013:167196.
- Pant A, Julfiqar, Huda N, Aslam M. Benign solitary schwannoma of right ulnar nerve – A case report. *Acta Medica International* 2015; 2(1):164-7.
- Thawait SK, Chaudhry V, Thawait GK, et al. Highresolution MR neurography of diffuse peripheral nerve lesions. *The American Journal of Neuroradiology*, vol. 32, no. 8, pp. 1365–1372, 2011.
- Trăistaru R, Enăchescu V, Manuc D, Gruia C, Ghiluşi M. Multiple right schwannoma. *Rom J Morphol Embryol*. 2008;49(2):235-9.
- Adani R, Baccarani A, Guidi E, Tarallo L. Schwannomas of the upper extremity: diagnosis and treatment. *Chir Organi Mov*. 2008 Sep;92(2):85-8.
- Rockwell GM, Thoma A, Salama S. Schwannoma of the hand and wrist. *Plast Reconstr Surg*. 2003 Mar;111(3):1227-3.
- Adani R, Tarallo L, Mugnai R, Colopi S. Schwannomas of the upper extremity: analysis of 34 cases. *Acta Neurochir (Wien)*. 2014 Dec;156(12):2325-30.

10. Bhatti AM, Alo GO, Power DM, Masood A, Thuse HG. Lobulated schwannoma of the median nerve: pitfalls in diagnostic imaging. *J Comput Assist Tomogr.* 2005;29:330-2.
11. Nishio J, Mori S, Nabeshima K, Naito M. Successful enucleation of large multinodular/plexiform schwannoma of the foot and ankle. *Springerplus.* 2015 Jun 17;4:260.
12. Senol N, Yilmaz O. A rare type of peripheral nerve sheath tumor: radial nerve schwannoma. *Turk Neurosurg.* 2015;25(1):137-40.
13. Di Lorenzo S, Corradino B, Cordova A, Moschella F. Unexpected Ulnar nerve schwannoma. The reasonable risk of misdiagnosis. *Acta Chir Plast.* 2007;49(3):77-9.
14. Lee FC, Singh H, Nazarian LN, Ratliff JK. High-resolution ultrasonography in the diagnosis and intraoperative management of peripheral nerve lesions. *J Neurosurg.* 2011 Jan;114(1):206-11.
15. Gosk J, Gutkowska O, Urban M, Wnukiewicz W, Reichert P, Ziółkowski P. Results of surgical treatment of schwannomas arising from extremities. *Biomed Res Int.* 2015;2015:547926.
16. D. M. Knight, R. Birch, and J. Pringl. Benign solitary schwannomas: a review of 234 cases. *J Bone Joint Surg Br.* 2007 Mar;89(3):382-7.
17. Ogose A, Hotta T, Morita T, Yamamura S, Hosaka N, Kobayashi H, Hirata Y. Tumors of peripheral nerves: correlation of symptoms, clinical signs, imaging features, and histologic diagnosis. *Skeletal Radiol.* 1999 Apr;28(4):183-8.
18. Forthman CL, Blazar PE. Nerve tumors of the hand and upper extremity. *Hand Clinics.* 2004;20(3):233-42.