

Liver alveolar hydatid cyst diagnosed patient with right intrahepatic biliary tract obstruction: A case report with special emphasis on radiological features

Alveolar kist hidatik tanılı hastada gelişen sağ intrahepatik safra yollarında obstrüksiyon: Radyolojik özelliklerinin vurgulandığı olgu sunumu

Fatih Ateş¹, Turgay Kara¹, Halil İbrahim Şara¹, Muhammed Sami Çoban¹, Mehmet Sedat Durmaz², Funda Gökğöz Durmaz³

¹ Department of Radiology, Education and Research Hospital, Health Sciences University, Konya, Turkey

² Department of Radiology, Selcuk University Medical Faculty, Konya, Turkey

³ Karatay Community Health Center Department of Family Medicine, Konya, Turkey

ORCID ID of the authors

FA: 0000-0002-2693-4616
TK: 0000-0001-8448-9066
HİŞ: 0000-0001-9075-9237
MSÇ: 0000-0003-3078-0231
MSD: 0000-0002-1340-2477
FGD: 0000-0003-3043-5809

Corresponding author / Sorumlu yazar:
Fatih Ateş

Address / Adres: Sağlık Bilimleri Üniversitesi,
Radyoloji, Eğitim ve Araştırma Hastanesi,
Bölgeler, Konya, Türkiye
e-Mail: fatih_ates81@hotmail.com

Informed Consent: The author stated that the written consent was obtained from the patient presented in the study.

Hasta Onamı: Yazar çalışmada sunulan hastadan yazılı onam alındığını ifade etmiştir.

Conflict of Interest: No conflict of interest was declared by the authors.

Çıkar Çatışması: Yazarlar çıkar çatışması bildirmemişlerdir.

Financial Disclosure: The authors declared that this study has received no financial support.
Finansal Destek: Yazarlar bu çalışma için finansal destek almadıklarını beyan etmişlerdir.

Received / Geliş tarihi: 03.11.2018
Accepted / Kabul tarihi: 08.01.2019
Published / Yayın tarihi: 09.01.2019

Copyright © 2019 The Author(s)
Published by JOSAM

This is an open access article distributed under the terms of the Creative Commons Attribution-Non Commercial-NoDerivatives License 4.0 (CC BY-NC-ND 4.0) where it is permissible to download, share, remix, transform, and build upon the work provided it is properly cited. The work cannot be used commercially without permission from the journal.



Abstract

Hepatic alveolar echinococcosis is a rare parasitic disease caused by Echinococcus multilocularis. The disease is diagnosed by a combination of serological tests, radiological modalities and histology of needle biopsy specimens. In this case, we present magnetic resonance imaging (MRI) and magnetic resonance cholangiopancreatography (MRCP) findings in a patient with right intrahepatic biliary tract obstruction due hepatic alveolar echinococcosis. A 66-year-old female patient who was diagnosed as liver alveolar hydatid cyst at the external university hospital in her anamnesis presented for evaluation of right upper-quadrant abdominal pain. MRI and MRCP were taken to patient. Lesion with hyper-intense and iso-intense components were observed in T2A images with a diameter of approximately 70x65 mm, length of 76 mm, heterogeneous intensities, no definite boundaries in liver segment 6-7 on MRI and MRCP. Continuation of right intrahepatic bile ducts was not observed due secondary to pressure of lesion. The lumen was slightly prominent in the traceable segment of approximately 7 mm. In lesion's peripheral segments, intrahepatic bile ducts were dilated in segment 6-7 due secondary pressure of lesion. The intrahepatic main bile ducts were normally wide on the left. The diameter of the choledochus was measured approximately 9 mm at its most prominent location and is normally expanded. The gallbladder was hydropic and had a transverse diameter of approximately 48 mm. There was no calculi or matter occupying the lumen. Alveolar echinococcosis lesions mimic slow-growing tumors of the liver parenchyma that tend to infiltrate adjacent structures, especially the portal hilum, hepatic veins, inferior vena cava, and biliary system, and spread to other organs by means of hematogenous dissemination. These lesions may be misdiagnosed as malignant neoplasms if the diagnosis is based on clinical features and imaging findings of local invasion and regional or distant metastases, without serologic testing. If left untreated, alveolar echinococcosis is eventually fatal. Effective treatment options include benzimidazole therapy and surgical resection or liver transplantation.

Keywords: Echinococcosis, Magnetic Resonance cholangiopancreatography, Liver, Biliary tract obstruction

Öz

Hepatik elveolar ekinokokkozis Echinococcus multilocularis'e bağlı gelişen nadir bir parazitik hastalık olup tanı serolojik, radyolojik ve histopatolojik değerlendirme ile konur. Bu vakada alveolar ekinokokkozis tanılı hastada gelişen sağ intrehepatik safra yollarında obstrüksiyonun manyetik rezonans görüntüleme (MRG) ve manyetik rezonans kolanjiopankreatografi (MRKP) bulgularını sunduk. Hikayesinde üniversite hastanesinde karaciğer alveolar hidatik kist tanısı olduğunu öğrendiğimiz 66 yaşında kadın hasta sağ üst kadran ağrısı ile kliniğe başvurdu. Hastaya MRG ve MRKP tetkikleri çekildi. Karaciğer segment 6-7 de yaklaşık 70x65 mm çaplarında, 76 mm uzunluğunda, heterojen intensitede, sınırları net seçilemeyen, T2A görüntülerde hiperintens ve izointens komponentleri bulunan alan izlendi. Sağda intrahepatik safra yolları devamlılığı lezyon basısına sekonder izlenmedi. İzlenebilen distal yaklaşık 7 mm'lik segmentte lümeni hafif belirgindi. Lezyon periferik kesimlerinde segment 6-7'de intrahepatik safra yolları dilate görünümde olup intrahepatik ana safra kanalları solda normal genişlikte saptandı. Koledok çapı en belirgin yerinde yaklaşık 9 mm ölçülmüş olup normalden genişti. Safra kesesi hidropik görünümde olup transvers çapı yaklaşık 48 mm ölçülmüştür, lümeninde yer kaplayan lezyon yoktu. Alveoler ekinokokkoz lezyonları, komşu yapılara, özellikle portal hiluma, hepatic venlere, inferior vena kava ve safra sistemine infiltre olan ve hematojen yayılım yoluyla diğer organlara yayılan, karaciğer parankiminin yavaş büyüyen tümörlerini taklit eder. Bu lezyonlar, serolojik testler olmaksızın, lokal invazyon ve bölgesel veya uzak metastazların klinik özelliklerine ve görüntüleme bulgularına dayanarak, malign neoplazmalar olarak yanlış teşhis edilebilir. Tedavi edilmezse, alveoler ekinokokkozun sonunda ölümcül olur. Etkin tedavi seçenekleri arasında benzimidazol tedavisi ve cerrahi rezeksiyon veya karaciğer transplantasyonu yer alır.

Anahtar kelimeler: Kistik ekinokokkozis, Manyetik rezonans kolanjiopankreatografi, Karaciğer, Safra yolu obstrüksiyonu

Introduction

The liver with portal system and hepatic arterial blood flow is one of the solid organs in which hematogenous pathologies are the most common. Parasitic liver cysts occur due to *Echinococcus granulosus* and *Echinococcus alveolaris*. Alveolar echinococcosis is a parasitic cyst form with as malignant and local invasion and distant organ metastases. Lesions cause destructive and infiltrative effects on the liver with biliary tracts or vascular invasions, causing liver dysfunction, biliary obstruction or abscess formation. These patients require mass resection or liver transplantation [1].

In practice, ultrasonography (US) is the most commonly used method in the evaluation and typing of liver hydatid cysts. Although computed tomography (CT) is more effective in demonstrating other organ cysts such as peritoneum and lung with cyst calcification and infection, CT can be inadequate in showing and typing the cyst content. Cyst content can be better shown by magnetic resonance imaging (MRI) in compatible patients and it is more suitable for follow-up after percutaneous treatment especially because it does not contain radiation. In addition, cystobiliary fistulas in special shots with magnetic resonance cholangiopancreatography (MRCP) or liver specific agents can be evaluated non-invasively [2].

In this case, we present MRI and MRCP findings in a patient with right intrahepatic biliary tract obstruction due hepatic alveolar echinococcosis.

Case presentation

A 66 year old female patient with diagnosed liver alveolar hydatid cyst in external university hospital in her anamnesis presented for evaluation of right upper-quadrant abdominal pain.

Lesion with a diameter of approximately 70x65x76 mm, with hyper-intense and isointense components, no definite boundaries were observed in T2A weighted images, in liver segment 6-7 on MRI and MRCP (Figure 1). Continuation of right intrahepatic bile ducts was not observed due to the pressure of lesion. The lumen was slightly prominent in the traceable segment of approximately 7 mm. Intrahepatic bile ducts were dilated in segment 6-7 due secondary pressure of lesion. The intrahepatic main bile ducts were normally wide on the left. The diameter of the choledochus was measured approximately 9 mm at its most prominent location and was dilatated. The gallbladder was hydroptic in appearance and had a transverse diameter of approximately 48 mm, with no mass occupying the lumen. The pancreatic duct was normally wide (Figure 2). In laboratory, total bilirubin was 0.7 mg/dL and alkaline phosphatase was 113 IU/L. Gamma glutamyl transferase was 41.9. There was no abnormality in the hemogram examination. The case that we presented continued the follow-up and treatment in the university hospital. While preparing the case report, we informed the patient and obtained the consent.

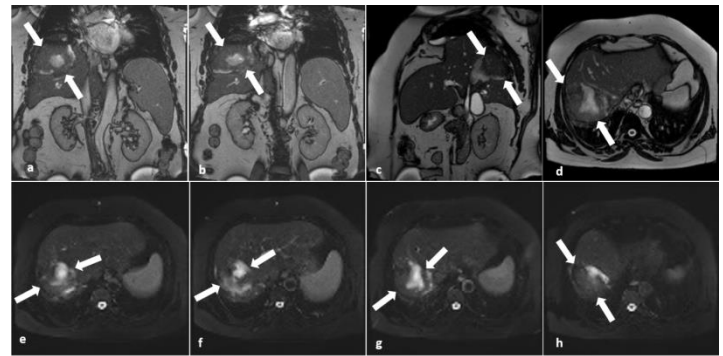

Figure 1: In the magnetic resonance cholangiopancreatography images; the coronal T2 (a, b), sagittal T2 (c), axial T2 (d) and fat-suppressed axial T2 (e-h) sections for liver; in the right lobe posterior superior segment; a mass lesion with solid components (arrow) of 76x70x65 mm diameter, heterogeneous intensity, with no borderline clearance, hyper-intense cystic T2A images, isointense with liver parenchyma was observed.

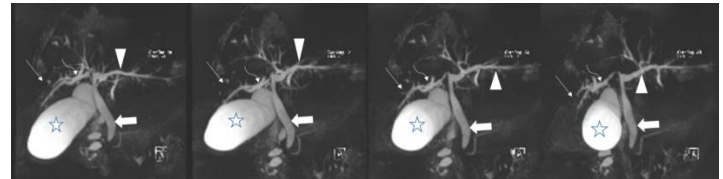


Figure 2: In the magnetic resonance cholangiopancreatography images obtained using the T2-weighted sequence; the gallbladder was observed in hydroptic appearance (star). The choledochus was dilated and the blunt end was distal (arrow). Distal segment of right intrahepatic biliary tract was seemed occluded due to mass compression (thin arrow) and was dilated in the proximal part (curved arrow).

Discussion

Hydatid cyst disease is a widespread human infection caused by the larval stage of the tapeworms of *Echinococcus* [3,4]. The clinical presentation of the disease varies with regard to the involvement of the held organ, the size of the cyst, the enlarged cyst and the adjacent organs. Liver hydatid cysts may cause a feeling of fullness in the abdomen, abdominal pain, vomiting and jaundice [5,6]. USG measurements have shown that cysts can grow 1-50 mm per year or remain unchanged for many years. They can also spontaneously rupture, collapse or disappear. They usually have no symptoms until they reach a diameter of 5 cm. Liver hydatid cysts show slower growth than in lungs [7]. As the size grows, it shows clinical signs due to pressure and occlusive effects.

The diagnosis of hydatid cyst is made by demonstration of cysts by various imaging methods. The diagnosis can be confirmed by serological tests [8]. Hydatid cysts can present with various clinical manifestations due to both the ability to perform various organ involvement and complications.

The liver is the most frequently affected organ, with a rate of 60-75%. Especially the right hepatic lobe is affected by the left lobe with a rate of 80%. Less common sites are the lungs, spleen, peritoneum, kidneys, brain, etc. [9]. Hydatid cysts are mostly asymptomatic and many hydatid cysts represent incidental clinical or radiological findings. Most symptomatic cysts are either complicated by rupture or secondary bacterial infection, or have symptoms of large size causes such as upper abdominal pain, swelling and discomfort [10]. Untreated Echinococcal cysts expose mass effect on the surrounding liver tissue. If not intervened, cystic pressure can exceed the pressure in the bile ducts by 5-30% of patients, resulting in cysts ruptured or fistulized into the bile ducts, spontaneous decompression of the cyst and cholangitis [11]. Imaging findings in biliary echinococcosis can be seen as filling defects due to biliary duct

dilatation which may extend to the peripheral channels, cystobiliary fistulas and biliary cysts or leaf-like membranes in the bile duct. In addition, irregularity / absence of the cyst wall, direct contact with the biliary tract, fluid-liquid levels in the cyst, or cystobiliary fistulae of fat particles should be considered [11,12].

In *Echinococcus multilocularis* infection, multiloculated alveolar cysts are observed and unlike *E. granulosus*, pericyst does not occur in the host and invasion to the surrounding tissue. The inflammatory process directly affects the biliary tract and portal vein branches, causing dilatation of the channels and parenchymal atrophy. In the imaging, *E. multilocularis* is an unclear infiltration that does not show contrast enhancement and contains solid and cystic areas. Biliary dilatation or direct parasitic biliary invasion due to hilar infiltration can be detected on MRI [11,12].

Visualization of biliary tracts often requires various imaging methods and is accepted as a US starting method. While the use of MRCP is increasing, ERCP is preferred for treatment purposes. It is clear that imaging methods have different contributions to each other, their weaknesses, and hence, to diagnosis. In order to avoid unnecessary examinations, the most appropriate methods should be determined and radiological findings should be evaluated as a whole. Interpretation of imaging findings together with clinical and laboratory findings is also very important for accurate diagnosis.

Alveolar echinococcosis mimics malignancy, also is frequently confused with other malignant liver lesions and has an infiltrative pattern [13]. Early diagnosis of the disease is very important in terms of treatment. Radiological findings have an important role and contribution in the diagnosis of the disease.

References

- Haider HH, Nishida S, Selvaggi G, Levi D, Tekin A, Moon JI, Tzakis AG. Alveolar Echinococcosis induced liver failure: salvage by liver transplantation in an otherwise uniformly fatal disease. *Clin Transplant*. 2008;22:664-7.
- Koc M. The investigation of clinical and radiological findings of hepatic alveolar cyst hydatid disease. *Annals of Medical Research*. 2018;25(4):768-71.
- Biava FM, Dao A, Fortier B. Laboratory diagnosis of cystic hydatid disease. *World J Surg*. 2001;25:10-14.
- Chautems R, Bubler L, Gold B, Chilcott M, Morel P, Mentha G. Long term results after complete or incomplete surgical resection of liver hydatid disease. *Swiss Med Wkly*. 2003;133:258-62.
- Turkylmaz Z, Sonmez K, Karabulut R, Demirogullari B, Gol H, Basaklar AC, et al. Conservative surgery for treatment of hydatidcysts in children. *World J Surg*. 2004;28:597-601.
- Kurul IC, Topcu S, Altinok T, Yazici U, Tastepi I, Kaya S, et al. Onestage operation for hydatid disease of lung and liver: principles of treatment. *J Thorac Cardiovasc Surg*. 2002;124:1212-5.
- Altıntaş N. Past to present: echinococcosis in Turkey. *Acta Tropica*. 2003;85:105-12.
- Ciftci N, Ates F, Turkdagi H, Findik D. Evaluation of seropositivity of patients with cystic echinococcosis. *Genel Tip Derg*. 2017;27(3):91-4.
- Beggs I. The radiology of hydatid disease. *AJR Am J Roentgenol*. 1985;145(3):639-48.
- Radford AJ. Hydatid Disease. In: Weatherall DJ, Ledingham JGG, Warrell DA, eds. *Oxford textbook of medicine*. Oxford: Oxford University Press. 1982;5:442-4.
- Catalano OA, Sahani DV, Forcione DG, et al. Biliary Infections: Spectrum of Imaging Findings and Management. *Radiographics*. 2009;29:2059-80.
- Czermak BV, Akhan O, Hiemetzberger R, et al. Echinococcosis of the liver. *Abdom Imaging*. 2008;33:133-43.

- Yanık F, Karamustafaoglu YK, Yoruk Y. Diagnostic dilemma in discrimination between hydatid cyst and Tumor, for two cases. *Namik Kemal Medical Journal*. 2017;5(1):44-9.