

A rare cause of acute abdominal pain in a child: Giant sigmoid volvulus

Çocukta akut abdominal ağrının nadir bir nedeni: Dev sigmoid volvulus

Ayşe Selcan Koç¹, Zerrin Özçelik²

¹ Department of Radiology, University of Health Sciences - Adana Health Practices and Research Center, Adana, Turkey
² Specialist of Pediatric Surgery, Department of Pediatric Surgery, University of Health Sciences - Adana Health Practices and Research Center, Adana, Turkey

ORCID ID of the authors
ASK: 0000-0003-1973-0719
ZÖ: 0000-0003-3728-0846

Abstract

Sigmoid volvulus (SV) is a rare, but also life-threatening disease if not diagnosed earlier. SV appears as torsion of the sigmoid colon around its mesentery and causes necrosis, perforation, peritonitis and sepsis when obstruction and ischemia progresses in the colon segment. The important issue in SV to keep in mind is consideration of this rare condition during detailed examination of the history, physical examination and laboratory findings in the patient who refers because of some complaints such as abdominal pain, constipation and distention. This would allow planning the advanced radiological examinations and adequate treatment protocols to confirm the diagnosis.

Keywords: Sigmoid volvulus, Child, Abdominal pain

Öz

Sigmoid volvulus (SV) çocukluk çağında nadir görülen erken tanı konulmazsa hayatı tehdit edici bir hastalıktır. SV sigmoid kolonun kendi mezenter kökü etrafında dönmesi ile oluşup kolonik segmentteki obstrüksiyon ve iskemi ilerleyince nekroz, perforasyon, peritonit, sepsis gelişmesine neden olmaktadır. SV'de önemli olan karın ağrısı, konstipasyon, distansiyon gibi şikâyetlerle başvuran hastalarda ayrıntılı hikaye, fizik muayene ve laboratuvar bulgularının incelenmesinde hekimin bu tanıyı da akılda tutmasıdır. Böylece tanıyı doğrulayacak ileri radyolojik incelemelerin zaman kaybedilmeden planlanması ve uygun tedavi protokolü mümkün olacaktır.

Anahtar kelimeler: Sigmoid volvulus, Çocuk, Karın ağrısı

Introduction

Sigmoid volvulus (SV) is mechanical obstruction of the colon and very rare during childhood [1]. The most common cause is torsion of a long and mobile sigmoid colon around a narrow mesenteric root [1]. The most significant causes include cramp-like or blunt abdominal pain, distention as well as interruption of gas-stool passage [1]. However, clinical findings are not specific in every case and clinical suspicion is very important for the diagnosis. Abdominal X-ray graph and computed tomography are common imaging methods used for SV. Perforation and necrosis-induced morbidity as well as mortality decreases by early diagnosis.

Case presentation

A 10-year old boy who do not have any previous disease referred to our emergency service because of abdominal pain and exhaustion intermittently for 2 days. The patient had no fever, nausea and vomiting. In the physical examination, an epigastric distention was detected; however, no rebound and defense was present. The patient had not any gas-stool passage for 24 hours. The rectal examinations revealed that the rectum was completely empty and clean without any palpable mass or fullness. The laboratory findings were as follows; white blood cell count: $10.3 \times 10^3/\text{mL}$, C-reactive protein: 0.5 mg/dL and other biochemical parameters and urine analysis were normal.

Corresponding author / Sorumlu yazar:
Ayşe Selcan Koç
Address / Adres: Sağlık Bilimleri Üniversitesi,
Radyoloji Anabilim Dalı - Adana Sağlık
Uygulama ve Araştırma Merkezi, Adana, Türkiye
e-Mail: drayseselcankoc@gmail.com

Informed Consent: The author stated that the written consent was obtained from the parents of the patient presented in the study.

Hasta Onamı: Yazar çalışmada sunulan hastanın velisinden yazılı onam alındığını ifade etmiştir.

Conflict of Interest: No conflict of interest was declared by the authors.

Çıkar Çatışması: Yazarlar çıkar çatışması bildirmemişlerdir.

Financial Disclosure: The authors declared that this study has received no financial support.
Finansal Destek: Yazarlar bu çalışma için finansal destek almadıklarını beyan etmişlerdir.

Received / Geliş tarihi: 26.09.2018
Accepted / Kabul tarihi: 10.10.2018
Published / Yayın tarihi: 10.10.2018

Copyright © 2018 The Author(s)

Published by JOSAM

This is an open access article distributed under the terms of the Creative Commons Attribution-Non Commercial-NoDerivatives License 4.0 (CC BY-NC-ND 4.0) where it is permissible to download, share, remix, transform, and buildup the work provided it is properly cited. The work cannot be used commercially without permission from the journal.



In the Abdominal X-ray graph sharp air-fluid levels as well as dilatation and reverse U finding were detected in intestinal segments (Figure 1a). The identified findings were evaluated in favor of intestinal obstruction however patient relatives did not accept the treatment. After 6 hours from leaving the hospital, the patient was taken to our hospital again due to increased abdominal pain. Noticeable rebound and defense were detected in the abdomen; air-fluid leveling were more significant in the abdominal X-ray graph (Figure 1b); abdominal computed tomography was showed a significant dilatation at intestinal segments and torsion were detected (Figure 2 and 3).

The patient was taken laparotomy it was seen that sigmoid colon rotated 540 degrees around its mesentery and the effected segment showed dilatation and edema (Figure 4). The twisted part of the sigmoid colon appeared as longer and the cause of volvulus was considered as longer sigmoid colon and we performed sigmoid colon resection with primer anastomosis. There was not any ischemia and necrosis in the intestine segment. The patient was fed after 48 hours from the surgery. The patient was discharged at postoperative day 5 by suggesting a polyclinic control. There was not any significant finding during control visit. Written informed consent was obtained from the parents of the patients who participated in this study.

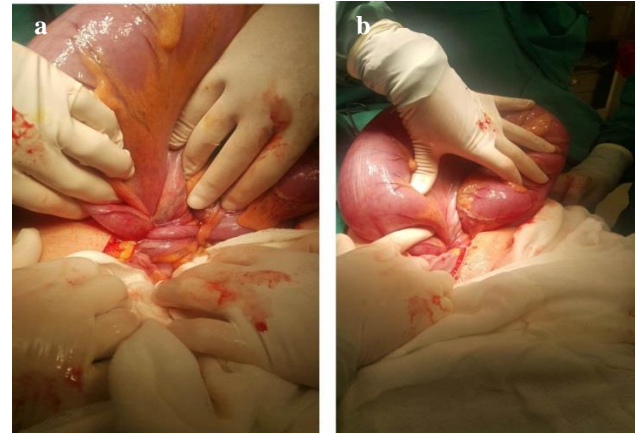


Figure 4: Intraoperative two different views (a and b) of sigmoid volvulus.

Discussion

SV is very rare in the children and may cause life threatening clinical manifestations. In the literature, Salas et al. [2] detected that the patients were usually between 7 and 12 years of age; the rate of male/female was 3.5/1. Volvulus is a pathological condition that appears as a result of anatomic torsion of the intestine around its narrow mesentery root [1]. Torsion may affect the intestinal supply; strangulation and gangrene may develop as a result. Development of volvulus requires a mobile colon which means a sufficient length of the colon mesentery for volvulus; mesenteries of the caecum and sigmoid colons were feasible for volvulus whereas other colon segments have low tendency [1].

Hirschsprung's disease, chronic constipation often play a predisposing role in development of SV, but other conditions like intestinal malrotation, anal stenosis, surgical adherence, prune belly syndrome, and mental retardation may also cause [1]. Our patient was a 10-year old boy and did not present any underlying significant pathology.

The important issue for diagnosis of SV is a detailed history, physical examination, laboratory tests as well as imaging methods. Severity of the symptoms is associated with degree of the torsion, strangulation and closed loop obstruction; the findings may vary between acute, subacute, chronic and persisting attacks. Major symptoms include cramp-like abdominal pain with sudden onset, increasing abdominal distention and loss of gas-stool discharge. Pain is usually diffuse; however, rarely blunt and localized [3]. Although nausea-vomiting also appears at the beginning, these usually develop following other symptoms. Such symptoms progresses rapidly in younger patients. Rectal examination may be completely normal or appear as red blood or in form of melena [4]. Dehydration, hematochezia, abdominal mass and fecaloid breath odor are other findings [4]. Unless gangrene develops in the colon, peritoneal irritation findings are not detected. Since non-perforated ischemic state does not deepen the clinical manifestation, it is difficult to differentiate simple volvulus from strangulated volvulus. However, irritation findings, fever and leukocytosis indicate gangrene. Defense appeared is a diagnostic finding when perforation and peritonitis occur. The present our case referred because of intermittent abdominal pain for 2 days. Abdominal pain gradually increased and defense was detected in the examination performed 6 hours after although no defense was detected in the initial physical examination.

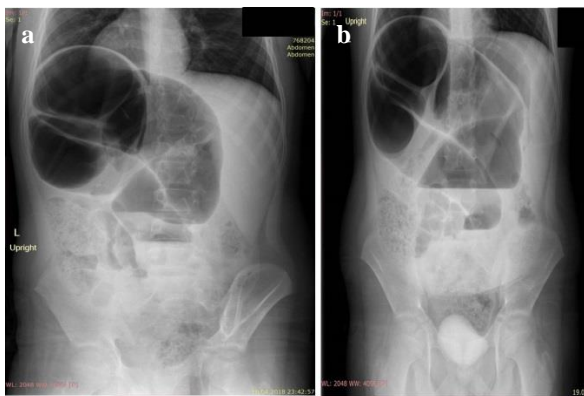


Figure 1: Abdominal X-ray demonstrating dilated colon segments, air fluid level, inverted "U" sign (a) First day of admission (b) Second day of admission.

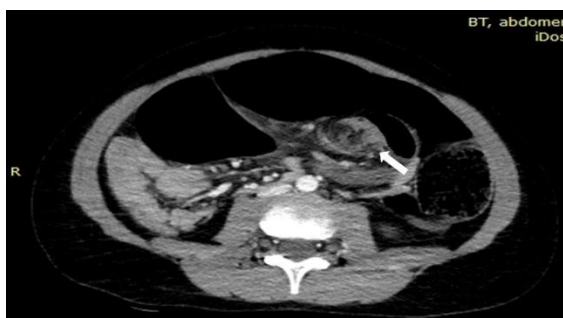

Figure 2: Axial abdominal CT image showing a distended gas-filled colonic loop and the whirlpool sign (twisting of the mesentery and vessels: arrow) suggestive of sigmoid volvulus.

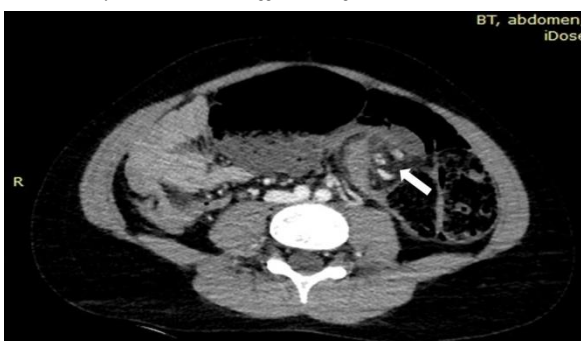

Figure 3: Axial abdominal CT image showing a distended gas-filled colonic loop and the whirlpool sign (twisting of the mesentery and vessels: arrow) suggestive of sigmoid volvulus.

Abdominal X-ray usually reveals dilated intestinal loops, air-fluid leveling which are nonspecific findings; diagnostic direct X-ray findings for volvulus include bill sign, reverse U shape (omega loop), large horseshoe [1,2]. Empty left iliac fossa in direct abdominal X-ray at standing position is accepted as a diagnostic finding [5]. An accurate diagnosis was established in 60 to 80% of the cases through direct abdominal X-ray; however diagnostic value of the X-rays is between 30% and 40% [5]. Whirlpool sign in CT provides accurate and reliable diagnosis of SV and this imaging method provides an accuracy of 100% in early stages of the disease [6]. The X-ray of our case revealed dilatation in intestinal loops, air-fluid leveling and reverse U finding were present. At that stage, intestinal obstruction was considered with findings of direct X-ray and abdominal CT evaluation was performed due to preliminary diagnosis of volvulus; evaluation results confirmed our diagnosis. Torsion of the sigmoid colon was clearly shown by dilated colon segments in CT.

Treatment of sigmoid volvulus is controversial for children. If clinical symptoms are stable and no sign for necrosis or intestinal perforation, non-operative induction, namely, barium enema or sigmoidoscopy should be performed [6,7]. However, performance of this maneuver was reported as difficult in the children [8]. Furthermore, recurrence was reported after endoscopic decompression in almost half of the cases [8]. Since the sigmoid volvulus is not distorted endoscopically or findings of ischemic intestine or peritonitis are indications for surgical operation; resection of the twisted segment and primary anastomosis or colostomy are performed surgically. Volvulus segment was detorsioned and dilate sigmoid segment resected through surgical procedure in our patient. Since there was not any finding for ischemia, prognosis of final treatment of sigmoid volvulus is promising on the condition of early diagnosis and immediate treatment [9].

In conclusion, SV is rarely caused of intestinal obstruction in children and adolescents. For this reason, pediatric surgeons should have a high degree of suspicion not to miss this diagnosis; any delay in treatment has a destructive effect on morbidity as well as mortality. Early diagnosis and prompt treatment confer an excellent prognosis.

References

- Oren D, Atamanalp SS, Aydinli B, Yildirgan MI, Başoğlu M, Polat KY, et al. An algorithm for the management of sigmoid colon volvulus and the safety of primary resection: experience with 827 cases. *Dis Colon Rectum*. 2007;50(4):489-97. DOI: 10.1007/s10350-006-0821-x
- Salas S, Angel CA, Salas N, Murillo C, Swischuk L. Sigmoid volvulus in children and adolescents. *J Am Coll Surg*. 2000;190(6):717-23.
- Weingrow D, McCague A, Shah R, Lalezarzadeh F. Delayed presentation of sigmoid volvulus in a young woman. *West J Emerg Med*. 2012;13(1):100-2. doi: 10.5811/westjem.2011.4.6720.
- Chang CJ, Hsieh TH, Tsai KC, Fan CM. Sigmoid Volvulus in a Young Woman Nearly Misdiagnosed as Fecal Impaction. *J Emerg Med*. 2013;44(3):611-3. doi: 10.1016/j.jemermed.2012.02.084.
- Raveenthiran V. Emptiness of the left iliac fossa: a new clinical sign of sigmoid volvulus. *Postgrad Med J*. 2000;76(900):638-4.
- Chiang LL, Lai HS, Ni YH, Hsu WM. Management of sigmoid volvulus based on Ladd's procedure: a case report. *Pediatr Neonatol*. 2009;50(3):129-31. doi: 10.1016/S1875-9572(09)60049-8.
- Parolini F, Orizio P, Bulotta AL, Garcia Magne M, Boroni G, Cengia G, et al. Endoscopic management of sigmoid volvulus in children. *Gastrointest Endosc*. 2016;8(12):439-43. doi: 10.4253/wjge.v8.i12.439.
- Colinet S, Rebeuh J, Gottrand F, Kalach N, Paquot I, Djeddi D, et al. Presentation and endoscopic management of sigmoid volvulus in children. *European Journal of Pediatrics*. 2015;174(7):965-9. doi: 10.1007/s00431-015-2489-5.
- Weeratunga ND, Samarakoon LB, Lamahewage AK. Sigmoid Volvulus Causing Intestinal Obstruction in a Child – A Case Report and Review of Literature. *J Pediatr Neonatal Care*. 2015;2:67. doi: 10.15406/jpnc.2015.02.00067