

Journal of Surgery and Medicine

e-ISSN: 2602-2079

Incidental findings at abdominal ultrasonography in health personnel working with radiation sources

Radyasyon kaynakları ile çalışan sağlık personelinde abdominal ultrasonografideki insidental bulgular

Elif Gündoğdu¹, Mahmut Kebapçı¹

¹ Department of Radiology, Eskişehir
Osmangazi University Faculty of
Medicine, Eskişehir, Turkey

ORCID ID of the authors
EG: 0000-0002-1729-6958
MK: 0000-0002-2856-9923

Abstract

Aim: In this study; we aimed to evaluate the incidental lesions detected by ultrasonography in the abdomen and their clinical trials at health personnel working in departments using radiation sources.

Methods: Ultrasonography reports on 52 health personnel working in departments using radiation sources were evaluated retrospectively, from the hospital report registry system. The findings were classified as anatomical variant, benign lesions and situations requiring further investigation.

Results: In 19 (36.53%) of the workers, the ultrasonography was completely normal. In 33 (63.46%) of the workers, lesions or sonopathological conditions were detected. There were incidental findings in 13 (25%) patients in hepatobiliar system, 8 (15.38%) patients in genitourinary system and 12 (23.07%) patients in both of them. 6 (11.53%) workers had a anatomic variant, 24 (46.15%) workers had a benign lesion or condition, and 26 (50%) workers required further examination.

Conclusion: Incidental findings are widespread at health personnel working in departments using radiation sources. Some of the findings were benign, while a significant number of cases required further investigation. Knowing commonly detected lesions prevents unnecessary anxiety, while it can ensure that cases requiring further investigation are considered sufficiently.

Keywords: Incidental findings, Ultrasonography, Health personnel

Öz

Amaç: Bu çalışmada radyasyon kaynakları ile çalışılan departmanlarda görevli sağlık personelinde ultrasonografi ile abdomen bölgesinde saptanan insidental lezyonların ve bu lezyonların klinik öneminin değerlendirilmesi amaçlanmıştır.

Yöntemler: Radyasyon kaynakları ile çalışılan departmanlarda görevli 52 sağlık çalışanının ultrasonografi raporları hastane rapor kayıt sistemi üzerinden retrospektif olarak değerlendirildi. Elde edilen bulgular anatomik varyant, benign lezyon ve ileri araştırma gerektiren durumlar olarak sınıflandırıldı.

Bulgular: 19 (%36,53) sağlık çalışanında ultrasonografi incelemeleri tamamen normaldi. 33 (%63,46) personelde lezyon ya da sonopatolojik durum tespit edildi. 13 (%25) çalışmada hepatobiliar sistemde, 8 (%15,38) çalışmada genitouriner sistemde ve 12 (%23,07) çalışmada ise hem genitouriner hem hepatobiliar sistemde bulgu saptandı. 6 (%11,53) çalışmada anatomik varyant, 24 (%46,15) çalışmada benign lezyon veya durum, 26 (%50) çalışmada ise ileri araştırma gerektiren durum tespit edildi.

Sonuç: Radyasyon kaynakları ile çalışılan departmanlarda görevli sağlık personelinde insidental bulgular yaygın olarak gözlenir. Bu bulguların bir kısmı benign iken önemli bir kısmı araştırılması gereken durumları içerir. Yaygın saptanan insidental bulguların bilinmesi gereksiz endişeyi önlerken, ileri araştırma gerektiren durumlara gerekli önemin verilmesini de sağlar.

Anahtar kelimeler: İnsidental bulgular, Ultrasonografi, Sağlık personeli

Corresponding author / Sorumlu yazar:
Elif Gündoğdu

Address / Adres: Eskişehir Osmangazi University,
Faculty of Medicine, Department of Radiology,
Meşelik Yerleşkesi, 26480, Eskişehir, Türkiye
E-mail: elif_basbay@hotmail.com

Ethics Committee Approval: The Medical Faculty
of Eskişehir Osmangazi University ethics
committee approved the study (no: 14, date:
15.05.2018).

Etik Kurul Onayı: Eskişehir Osmangazi
Üniversitesi Tıp Fakültesi etik kurulu çalışmayı
onayladı (no: 14, tarih: 15.05.2018).

Conflict of Interest: No conflict of interest was
declared by the authors.

Çıkar Çatışması: Yazarlar çıkar çatışması
bildirmemişlerdir.

Financial Disclosure: The authors declared that
this study has received no financial support.
Finansal Destek: Yazarlar bu çalışma için finansal
destek almadıklarını beyan etmişlerdir.

Received / Geliş Tarihi: 03.06.2018
Accepted / Kabul Tarihi: 11.07.2018
Published / Yayın Tarihi: 13.07.2018

Copyright © 2018 The Author(s)
Published by JOSAM

This is an open access article distributed under the terms of the Creative
Commons Attribution-NonCommercial-NoDerivatives License 4.0 (CC
BY-NC-ND 4.0) where it is permissible to download, share, remix,
transform, and buildup the work provided it is properly cited. The work
cannot be used commercially without permission from the journal.



How to cite / Atf için: Gündoğdu E, Kebapçı M. Incidental findings at abdominal ultrasonography in health personnel working with radiation sources. J Surg Med. 2018;2(3):288-292.

Introduction

Incidental radiological findings; are lesions or conditions that are diagnosed during examinations performed for other purposes and do not produce symptoms in the patient [1,2]. Increasing frequency of using imaging techniques has also increased the detection rate of these lesions [1-3]. Detected lesions are usually small-sized and benign, but also detection of cases requiring detailed evaluation is not so less [4]. The lesions and their ratios determined according to the examined body region vary. Abdomen is one of the most common anatomical localizations of incidental lesions [4].

Health personnel working with radiation sources are at a higher risk for precancerous lesions and various malignancies such as thyroid and hematopoietic system than other parts of the society. For this reason, some radiological examinations are carried out at certain periods for screening purposes. Incidental lesions can be detected during these examinations and how the management in this group can be confusing from time to time.

In this study; it was aimed to evaluate the incidental lesions and conditions detected by ultrasonography (USG) in the abdominal region and their clinical trials in health personnel working in departments using radiation sources who is fully asymptomatic and no history of known disease.

Materials and methods

Between October 2017 and January 2018, abdominal ultrasound reports of 52 health personnel (35 female, 17 male) aged 23-54 years working in departments with radiation sources were evaluated retrospectively. While, the mean age of females 36.68 ± 6.56 , the mean age of males 40.29 ± 9.62 . In the group included in the study, the health workers were completely asymptomatic and none had previously known illness. Sonographic examination was performed by a single radiologist-10 years of experience- with 12 hours of fasting and full filled bladder with USG. All examinations were made the same USG device (Toshiba Aplio 500) and 3-6 MHz convex probe. All examinations were performed by transabdominal approach. Detected lesions or conditions were reported in detail for each organ. All patients' records were accessed via the hospital report registry system. In retrospectively examined reports, lesions and findings were determined for each organ. The findings were classified as anatomic variant, benign lesions and cases requiring further examination. For anatomical variants, no follow-up examination was required. Benign lesions had typical ultrasonographic features and were not needed further examination. In some of them, follow-up was unnecessary (e.g. simple renal cyst) and in some of them (e.g. hemangiomas) ultrasonographic follow-up was sufficient. For some of the lesions or conditions requiring further investigation (e.g. splenomegaly), laboratory findings and etiological research were required, while in some (e.g. hydronephrosis) advanced radiological evaluation was required.

Statistical analysis was performed using SPSS 20.0 (Chicago, IL) software.

Ethical committee approval from Eskişehir Osmangazi University Faculty of Medicine was taken for the study.

Results

While the examination was satisfactory at 48 (92.30%) of the study group; examination was suboptimal at 4 (7.70%) of the study group, because of intensive gas distension, obesity or no breathing cooperation. The pancreas could not be assessed for these reasons in the group where the examination was insufficient. In 19 (36.53%) of the study group, abdominal USG examination was completely normal and no sonopathologic condition was detected. In 33 (63.46%) of the study group had lesions or sonopathological conditions in the intraabdominal organs. There were incidental findings in the hepatobiliary system in 13 (25%), genitourinary system in 8 (15.38%), and both genitourinary and hepatobiliary systems in 12 (23.07%).

Twenty-five (48.07%) of the study group had incidental findings in the hepatobiliary system. The detected findings are shown in Table 1. The most frequent incidental finding was hepatosteatosis. Grade 1 steatosis in 14 health personnel and grade 2 steatosis in 7 health personnel were detected. None of health personnel had Grade 3 steatosis. In a case in whom a simple hepatic cyst was detected, the number of cysts was more than 10, the largest cyst was 14 mm in diameter, and all cysts showed anechoic simple cyst characteristics. 3 health personnel had hemangiomas with typical ultrasonographic features (Figure 1). There were a total of 4 gallbladder polyp (2 in 1 patient) in 3 personnel. All of the polyps were smaller than 5 mm and did not carry any suspicious findings in terms of malignancy. One personnel had a single gallstone with a diameter of 13 mm, and the other patient had multiple stone which were smaller than 1 cm. Four of the personnel had one accessory spleen; all of the accessory spleens were localized in splenic hilum. No incidental findings were found in the pancreas in any of the personnel.

Twenty (38.46%) of the study group had incidental findings in the genitourinary system. The detected findings are shown in Table 2. A total of 8 renal cysts (2 in 1 patient, 3 in 1 patient, and 1 in 3 patients) were observed in 5 personnel (Figure 2). Seven of these cysts were simple cysts, while 1 had fine septations. A total of 6 kidney stones were observed in 3 patients (3 in 1 patient, 2 in 1 patient, 1 in 1 patient) (Figure 3). All stones were smaller than 1 cm in size, and concomitant calyceal ectasia was not present. Hydronephrosis was detected in 1 personnel and it was grade 1. There were 7 myoma (2 subserous in 1 patient, 2 intramural in 1 patient, 1 in 3 patients) in 5 personnel. None of the male patients had any pathology in the seminal vesicles and also in adrenal gland and bladder in both genders.

Patients were categorized to anatomic variation (accessory spleen, hypoplastic kidney, septate uterus), benign incidental findings (hepatic cyst, hemangiomas, bile stones, polyps, sludge, medullary nephrocalcinosis, renal cysts, stones, hemorrhagic / simple ovary cysts, paraovarian cysts, endometrioma, PCOS, myoma, prostate hyperplasia) and the findings to be investigated (hepatosteatosis, hepatomegaly, splenomegaly, hydronephrosis, focal calyceal ectasia, medullary nephrocalcinosis). Categories are shown in Table 3. The patient with hydronephrosis was suggested to evaluate with other radiological imaging modalities (computed tomography (CT)); and for other patients were suggested to evaluate with clinical and laboratory findings.

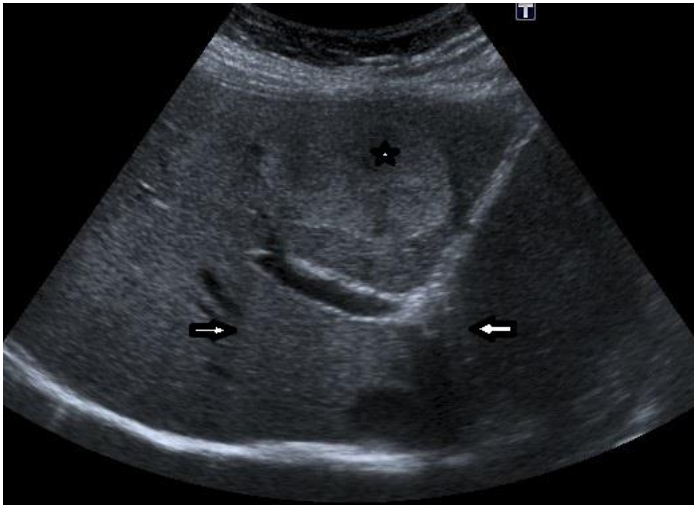


Figure 1: Ultrasonography image shows well-defined hyperechoic solid mass (asterisk) in liver parenchyma. Posterior acoustic enhancement (arrows) is typical for hepatic hemangiomas.

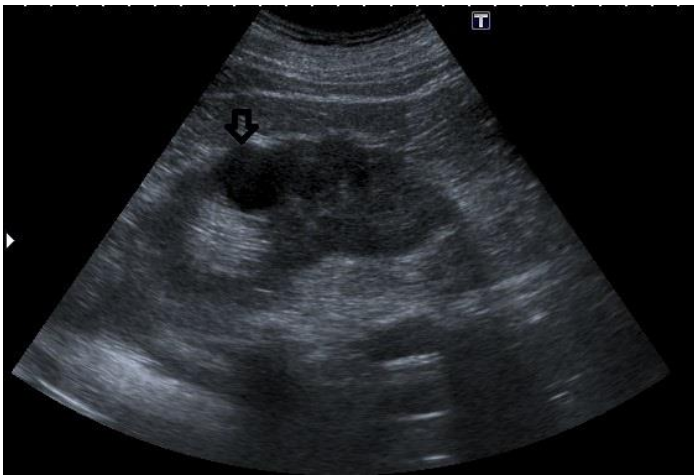


Figure 2: A hypoechoic cystic lesion (arrow) is seen upper pole of left kidney without any solid component or septa (simple cortical cyst).

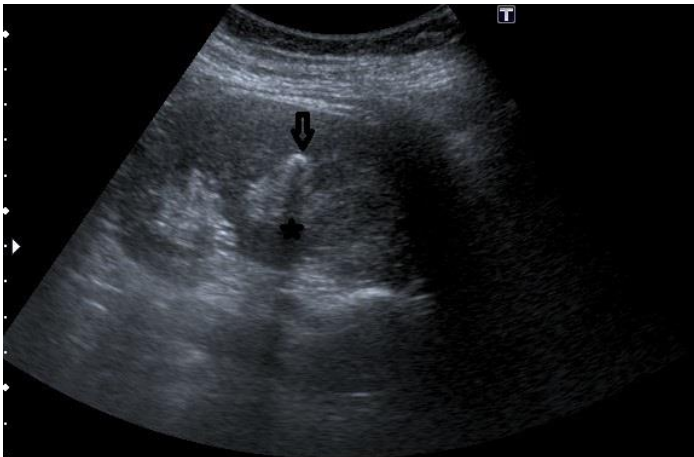


Figure 3: Ultrasonography image shows an echogenic foci (arrow) in calyceal system with posterior acoustic shadowing (asterisk) without any findings of obstruction.

Table 1: Incidental findings detected in hepatobiliar system

Incidental Findings	Organ	Number (n)	Ratio (%)
Hepatobiliar System			
Liver			
Grade 1 / Grade 2 Hepatosteatois		14/7	40.38
Hepatomegaly		5	9.61
Simple hepatic cyst		1	1.92
Hemangioma		3	5.76
Focal fatty- protection area		3	5.76
Gall Bladder			
Stone		2	3.84
Sludge		1	1.92
Polyp		3	5.76
Spleen			
Splenomegaly		2	3.84
Accessory Spleen		4	7.69

Table 2: Incidental findings in the genitourinary system

Incidental Findings	Organ	Number (n)	Ratio (%)
Genitouriner System			
Kidney			
Renal cyst		5	9.61
Renal stone		3	5.76
Focal caliectasy		2	3.84
Hydronephrosis		1	1.92
Medullary nephrocalcinosis		1	1.92
Hypoplastic kidney		1	1.92
Female Genital System			
Subserous / Intramural Myom		2/3	14.28
Septate uterus		1	2.85
Nabothian cyst		1	2.85
Simple ovarian cyst		5	14.28
Hemorrhagic ovarian cyst		1	2.85
Endometrioma		2	5.71
Paraovarian cyst		1	2.85
Polycystic ovary syndrome (PCOS)		2	5.71
Male Genital System			
Prostate Hypertrophy		2	11.76

Table 3: Categories according to findings

Categories	Number (n)	Ratio (%)
Category 1 (Anatomical Variants)	6	11.53
Accessory spleen		
Septate uterus		
Hypoplastic kidney		
Category 2 (Benign lesions or conditions)	24	46.15
Hepatic cyst, Hemangioma, Focal fatty- protection area		
Gall bladder stone/sludge/polyp		
Kidney cyst/stone		
Uterine myoma, nabothian cyst		
Simple/hemorrhagic ovarian cyst, paraovarian cyst, endometrioma, PCOS		
Prostate Hypertrophy		
Category 3 (situations need to be investigated)	26	50.00
Hepatosteatois, Hepatomegaly		
Splenomegaly		
Hydronephrosis, Focal caliectasy, Medullary Nephrocalcinosis		

Discussion

Along with the increasing use of imaging techniques, there is also an increase in incidental findings [1-5]. There are many studies on this topic, especially in trauma patients, with incidental findings in CT [1,4,6]. Incidental findings were determined at varying rates in these studies. One of the most frequently detected anatomic localizations of incidental lesions is abdomen [4]. Since there is no literature study on incidental lesions detected by abdominal USG, was compare and evaluate the our study group with those performed with CT in the general population.

The most common organ which detected incidental finding in our study is the liver. Hepatosteatois is the most common (40.68%) incidental finding. It has been reported that between %27 and 38 of general population in Western countries [7]. In autopsy series these rates were around 20% [8]. The incidence in our study group was found to be higher than the normal population and autopsy findings. There are many factors affecting hepatosteatois such as sedentary lifestyle, obesity, metabolic syndrome, ethnicity and gender. This result which we have obtained to determine whether the increased rate of steatois in health personnel working with radiation sources is due to radiation exposure alone needs to be compared to the normal population with similar risk factors (diabetes, family history, hyperlipidemia etc.) and characteristics (body mass index, sex, ethnicity etc.).

The hepatosplenomegaly has been detected at similar incidental rates both in health personnel working with radiation sources and in the normal population. This condition was in the

categories that need to be investigated in both groups. This issue is even more important because of the increased risk of hematopoietic malignancies in health personnel working with radiation sources, and further imaging may be needed with more detailed examination. Hydronephrosis is also a condition in the category that needs to be investigated. Hydronephrosis has been reported to be detected incidentally in the normal population in many studies [4,5]. Detection rates in our study group are not different from the normal population.

Hemangiomas are the most common benign lesions of the liver and are usually incidentally detected. It was reported in 0.4% to 7.3% of cases and in autopsy series these rates were between 3% and 20% [9]. In our study, the rate was 5.76%. The incidence of hemangiomas in our study group is similar to that of the normal population.

In the liver parenchyma, simple cysts are observed in 2.5 to 18% [10]. Incidence with age increases [10]. The rate of hepatic cyst in our study was found to be 1.92% and similar to the literature. The average age of our study was low and the incidence was likely to increase in older patient groups. There was no significant difference in the incidence of hepatic cysts between our study population and other parts of the community. Quattrocchi and friends found that the ratio incidentally detected of hepatic cyst was 0.3% with spinal magnetic resonance imaging (MRI) [5]. The modality difference and the fact that the liver is not fully involved in the study area may explain the lesser incidence compared to our study.

Bile stones incidence were found to be 3.84% in our study. It was seen in approximately 10% of the population and the incidence increases with age. The average age of our study group was the young adult age group and this may be the reason for the low incidence. The similar situation applies in the case of bile sludges. Gallbladder polyps were seen in 5-7% of the society and 90% were benign [11]. The rate of polyp detection in our study was 5.76%, similar to the general population. Accessory spleen were reported 6.7% in autopsy series [12]. In our study group, the ratio was 7.69 and similar. According to the study we think that working with radiation sources does not pose an increased risk for gallbladder stones, sludges, polyps and accessory spleen.

It is known that the incidence of renal cysts together with age increases and the rate of detection in CT examinations reaches 40% and incidental detection rate in pediatric age group reaches 0.2%. In our study group, the ratio was 9.6%, which was expected for the young population. It does not differ from the normal population.

Incidental kidney stones were detected in 5.76% of our study. This rate was found 13.9% in studies performed with CT colonoscopy and 0.1% in MR studies [5]. It is known that CT is more sensitive than USG in detection of stone less than 5 mm and MRI is less sensitive in stone detection. Because our study was performed with USG, the incidence is expected to be lower than CT.

Uterine myomas were seen in approximately 20-50% of the female in the reproductive age group. In our study, the rate was 15% and the incidence could be lower because some of the patients were in the postmenopausal period. Similarly, the

incidence of endometrioma was less than that of the reproductive age group, and the same reason is valid for this situation.

There is no study of incidental findings in health personnel working with radiation sources, all of the studies we compared in the literature were conducted in the general population. When considered as a whole, there were not different for anatomical variants and benign incidental findings between the general population and our study group. Some benign incidental findings due to the limitations of age and imaging modality were detected less common than in the general population. No increase in the incidence of benign incidental findings in health personnel working with radiation sources was detected.

In studies involving incidental lesions; it was found that the presence and malignancy rates of incidental findings increases with age [1-5]. In our study, was also found that the incidence of incidental lesions increased with age. No malignant incidental findings were observed in our study. This may be because the average age of our patient population was low. There is no significant relationship between the detected anatomical variations and age, and for most of these congenital variations this is an expected outcome.

The most important limitation of our study was the small number of patient populations. The fact that the working group was made up of a relatively young adult population was another limitation. It was known that the incidence of incidental lesions increases with age. Studies involving a wider series of cases and diversification of age groups will yield more accurate results and thus more generalized results can be obtained.

Another potential limitation of our study was that the study were made with USG and because of the known limitations and technical factors of USG, it is difficult to evaluate the adrenal gland and pancreas. Adrenal lesions are one of the most common incidental lesions in the abdominal region. However, most of these studies were done with CT. In our study, we think that the reason for the absence of incidental lesion in the adrenal gland is due to the modality difference. This discrepancy may have occurred because the retroperitoneal area is difficult to assess by ultrasound and most incidental lesions are small in size.

Conclusion

Incidental findings are widespread in health personnel working with radiation sources. Some of the incidental findings are benign or anatomic variants and do not differ from the normal population. Knowing commonly observed benign incidental lesions allows us to avoid unnecessary anxiety and further examinations. On the other hand, situation are detected that need to be investigated at a considerably high rate. The detection of these conditions can ensure that they are taken seriously.

References

1. Lantinga MA, Gevers TJJ, Drenth JPH. Evaluation of hepatic cystic lesions. *World Journal of Gastroenterology*. 2013;19(23):3543-54. <https://doi.org/10.3748/wjg.v19.i23.3543>
2. Patel S, Rajalakshmi BR, Manjunath GV. Histopathologic findings in autopsies with emphasis on interesting and incidental findings-A pathologist's perspective. *Journal of Clinical and Diagnostic*

- Research. 2016;10(11);EC08-EC12.
<https://doi.org/10.7860/JCDR/2016/21106.8850>
3. Wilkins T, Tadkod A, Hepburn I, Schade RR. Nonalcoholic fatty liver disease: diagnosis and management. *Am Fam Physician*. 2013;88(1);35-42.
 4. Yao J, Burns JE. Extracolonic Findings on CT Colonography. Does the Benefit Outweigh the Cost? *Academic Radiology*. 2013;20(6);665-6. <https://doi.org/10.1016/j.acra.2013.03.005>
 5. Quattrocchi CC, Giona A, Di Martino AC, Errante Y, Scarciolla L, Mallio CA, Zobel BB. Extra-spinal incidental findings at lumbar spine MRI in the general population: a large cohort study. *Insights into Imagin*. 2013;4(3);301-8. <https://doi.org/10.1007/s13244-013-0234-z>
 6. Paluska TR, Sise MJ, Sack DI, Sise CB, Egan MC, Biondi M. Incidental CT findings in trauma patients: Incidence and implications for care of the injured. *Journal of Trauma - Injury, Infection and Critical Care*. 2007;62(1);157-61. <https://doi.org/10.1097/01.ta.0000249129.63550.cc>
 7. Hitzeman N, Cotton E. Incidentalomas: Initial management. *American Family Physician*. 2014;90(11);784-89.
 8. Berland LL, Silverman SG, Gore RM, Mayo-Smith WW, Megibow AJ, Yee J, Taylor AJ. Managing incidental findings on abdominal CT: White paper of the ACR incidental findings committee. *Journal of the American College of Radiology*. 2010;7(10);754-73. <https://doi.org/10.1016/j.jacr.2010.06.013>
 9. Taşeva A, Taşev V, Bulanov D, Dimitrov K, Popov V, Zivkov E, Dimitrova V. Diagnosis of liver hemangioma. *Khirurgiia (Sofia)*. 2013;(3);8-13.
 10. Sperry JL, Massaro MS, Collage RD, Nicholas DH, Forsythe RM, Watson GA, Peitzman AB. Incidental radiographic findings after injury: Dedicated attention results in improved capture, documentation, and management. *Surgery*. 2010;148(4);618-24. <https://doi.org/10.1016/j.surg.2010.07.017>
 11. Sarici IS, Duzgun O. Gallbladder polypoid lesions > 15 mm as indicators of T1b gallbladder cancer risk. *Arab Journal of Gastroenterology*. 2017;18(3);156-58. <https://doi.org/10.1016/j.ajg.2017.09.003>
 12. Unver DN, Uysal L, Demirci S, Dogan KH, Kolcu G. Accessory spleens at autopsy. *Clinical Anatomy*. 2011;24(6);757-62. <https://doi.org/10.1002/ca.2011.04.006>